

COMPOUND HETEROZYGOSITY FOR A VARIABLY PENETRANT VARIANT AND A VARIANT OF UNKNOWN SIGNIFICANCE IN *FLT4* CAUSES FULLY PENETRANT MILROY'S LYMPHEDEMA

J. Kim, S.Y. Lim

Department of Plastic Surgery, Samsung Medical Center, Sungkyunkwan University School of Medicine, South Korea

ABSTRACT

*Milroy disease, known as primary congenital lymphedema, is characterized by chronic tissue swelling due to impaired lymphatic drainage and is inherited in an autosomal dominant manner. This study reports a rare case of Milroy disease affecting siblings from unaffected parents. A one-month-old female infant presented with swelling of the bilateral calf and the dorsum of the feet which had been present since birth. Her 14-month-old brother had a similar presentation since birth with swelling of the bilateral calf and the dorsum of the feet. Milroy disease was diagnosed based on the clinical findings of bilateral lower limb swelling and confirmed by molecular genetic testing. The patient and her family, including her brother, parents, and maternal grandfather, were genetically tested, and two novel missense mutations (NM_182925.4: c.2534T>C; p.Leu845Pro, c.4006G>A; p.Glu1336Lys) were found in the Fms-related tyrosine kinase (*FLT4*) gene. Mutations segregated by the parents who carried each mutation in the heterozygous state were identified in the patient and her brother. The present case report in which Milroy disease developed in all offspring of parents with a normal phenotype suggests the possibility of a compound heterozygous mutation or non-penetrance during the process of inheritance of Milroy disease.*

Keywords: lymphedema, Milroy disease, missense mutation, compound heterozygous mutation, non-penetrance

Milroy disease refers to familial primary lymphedema. The gene encoding Fms-related tyrosine kinase (*FLT4*) is the only known causative gene (1-3). Mutations in *FLT4* are responsible for lymphatic hypoplasia, which leads to a dysfunctional valve system and failure of initial lymphatic fluid absorption (1,2,4). The onset of edema due to lymphatic dysfunction may occur pre- or postnatally usually affecting both lower limbs (1,4,5). Milroy disease is diagnosed based on these clinical findings, and additional molecular genetic testing can confirm the diagnosis (6). There is currently no cure for Milroy disease except for spontaneous resolution. Therefore, the ultimate goal of therapy is to prevent disease progression by maintaining or mechanically reducing limb size to relieve the symptoms resulting from lymphedema while preventing skin infection (5).

Milroy disease is inherited in an autosomal dominant manner as in most familial cases of primary lymphedema (4,6). Indeed, most published case reports of Milroy disease suggest this manner of inheritance (7,8). Exceptionally, two cases of autosomal recessive inheritance of Milroy disease have been reported (9,10). In addition, there have

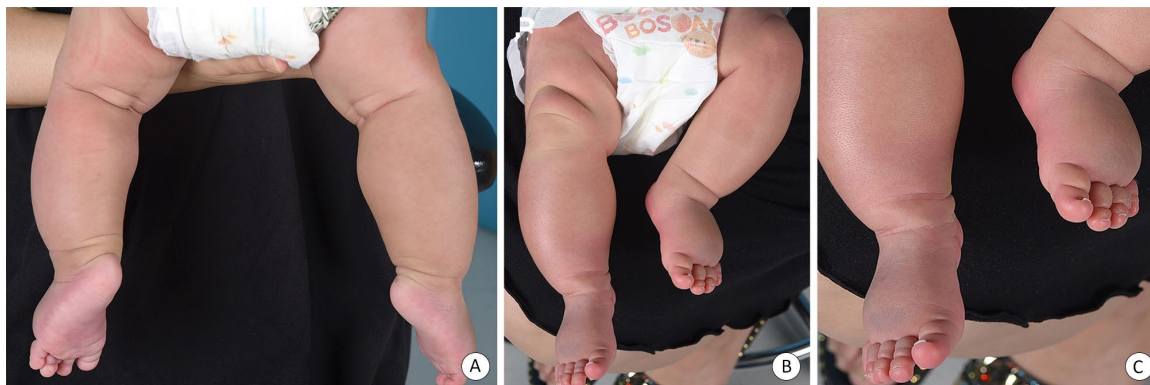

Fig. 1. (A) Bilateral swelling of the calves of the female infant one month after birth, swelling of the right (Rt) calf is more prominent than that of the left (Lt) calf. (B) Bilateral swelling of the dorsum of the feet one month after birth, Lt. dorsum of the foot swelling is more prominent than that of the Rt. dorsum of the foot. (C) Upslanting toenails observed in both big toes.

been several case reports in which individuals presenting with no symptoms were parents to some of offspring diagnosed with Milroy disease (7,11). With no evidence of autosomal recessive inheritance or spontaneous mutation, these reports suggest incomplete penetrance of Milroy disease inheritance, indicating that approximately 10-15% of individuals with an *FLT4* pathogenic variant could be clinically asymptomatic (6). However, to our knowledge, no previous studies have reported a case where all offspring from phenotypically normal parents were affected by Milroy disease.

Herein, we report a case of a brother and sister with clinical manifestations of Milroy disease, despite the parents having no history of lymphedema. In addition, this study presents novel *FLT4* mutation findings from the exome sequencing analysis of five family members, including siblings with Milroy disease.

CASE

A one-month-old female infant presented with bilateral swelling in the lower limbs and dorsum of the feet, with no associated inflammatory signs and no pain on palpation. The swelling was bilateral but was more remarkable on the right calf than on the left calf and the left dorsum of the foot than on the right dorsum of the foot. Upslanting toenails were also observed, most notably in both big

toes. No other abnormal clinical features were present (*Fig. 1*). The infant was born at full-term gestation, with a bodyweight of 3.38 kg. Swelling of both lower limbs was observed by ultrasonography during pregnancy, and the child was noted to have swelling of the calves and feet after birth. The circumference of the calves and feet was as follows: right calf, 15 cm; left calf, 13 cm; right foot dorsum, 10 cm; and left foot dorsum, 10.5 cm. Congenital secundum atrial septal defects were detected and examined. Although several differential diagnoses can be considered for primary lymphedema, the chromosomal analysis revealed no abnormalities. Additional detailed investigations were not requested because the clinical manifestations and age of onset matched those of Milroy disease.

Currently, the child is using a compression bandage to prevent progression and requires follow-up to monitor disease progression. Her family history was unremarkable, except for that of her older brother, a 14-month-old male infant born at full-term gestation weighing 3.75 kg. He had symmetrical bilateral swelling of the lower limbs and dorsum of the feet and a hydrocele at birth. The hydrocele improved spontaneously; however, swelling of the lower limbs persisted and upslanting of toenails was observed (*Fig. 2*). He experienced difficulty initiating walking due to swelling of dorsum of

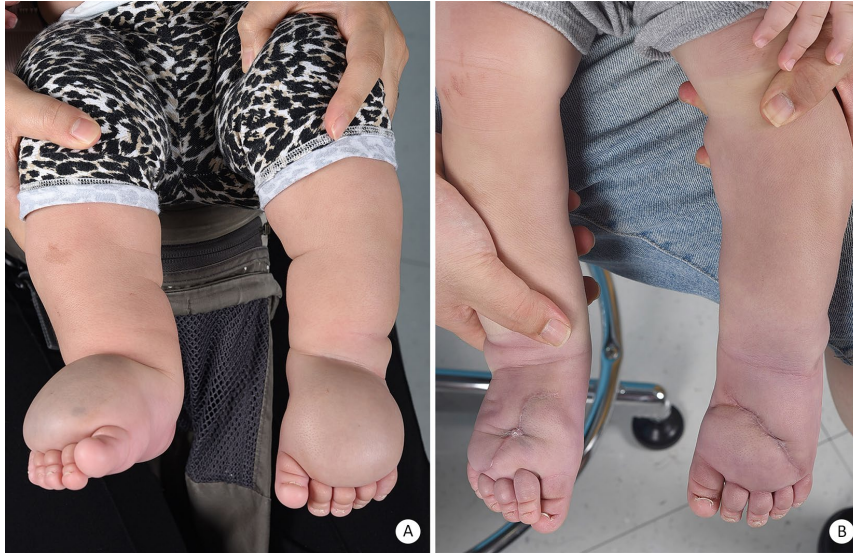

Fig. 2. (A) Bilateral swelling of the calves and dorsum of the feet seven months after birth of the male infant, before debulking surgery. (B) Bilateral calf and dorsum of the feet after debulking surgery at 11 months of age.

his feet; therefore, he required surgery. Magnetic resonance imaging of the lower extremities was performed in preparation of the surgery. Consequently, congenital lymphedema was suggested based on the probable bilateral diffuse soft tissue edema and predominant vascular structure with mild enhancement involving the subcutaneous fat layer of the dorsum of the feet and lower legs (right > left). Debulking of bilateral dorsum of the feet was performed when he was 11 months-old, and after surgery, conservative treatment with a compression bandage was maintained (*Fig. 2*).

The patient and four additional family members, including her brother, parents, and maternal grandfather, were genetically tested, and sequencing was performed on exons of *FLT4* to identify the pathogenic variant related to Milroy disease. Two novel missense variants (NM_182925.4: c.2534T>C; p.Leu845Pro, c.4006G>A; p.Glu1336Lys) that have not been previously recorded in common databases were identified (9,12,13). These two mutations were found in both affected siblings. The patient's mother was positive only for the p.Leu845Pro variant and the patient's father was positive only for the p.Glu1336Lys variant. When the maternal grandfather with no

signs of Milroy disease was screened, only the p.Leu845Pro variant was found, similar to that in the patient's mother (*Fig. 3*).

The patient's parents recently reported a new family history; the patient's maternal great aunt and another great aunt's daughter also had been diagnosed with lymphedema (*Fig. 3*).

DISCUSSION

Primary lymphedema results from a dysfunction of the lymphatic system, and Milroy disease was the first hereditary form of primary lymphedema to be described (4). Milroy disease is caused by mutations in *FLT4*, which plays a vital role in regulating the development and maintenance of the lymphatic system (4). However, *FLT4* mutations do not account for all cases of Milroy disease, and some reports have suggested genetic heterogeneity (12,14). Notably, the location of swelling is limited to below the knee and usually presents at birth (4). In addition to a swelling of the lower limb, there are several other clinical manifestations associated with Milroy disease, such as hydro-cele (37% of males), prominent veins (23%), upslanting toenails (14%),

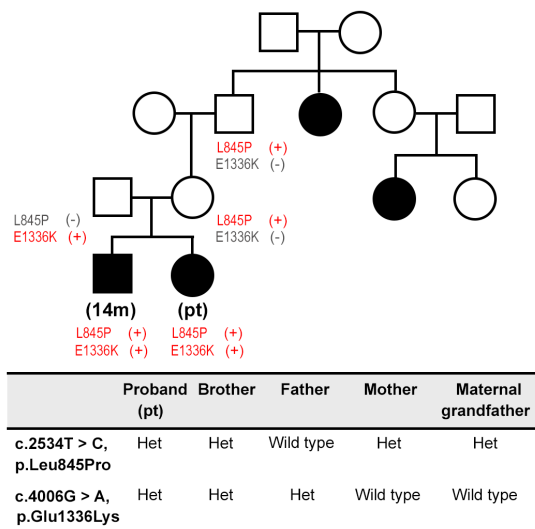


Fig. 3. Family pedigree showing affected individuals and pathogenic mutations.

papillomatosis (10%), and urethral abnormalities in males (4%). Cellulitis is known to occur in approximately 20% of individuals with Milroy disease and can further damage lymphatic vessels (4,15).

Although two cases of Milroy disease have been reported to be inherited in an autosomal recessive manner, most cases of Milroy disease are inherited in an autosomal dominant manner, meaning that each child of a parent with Milroy disease has a 50% chance of inheritance (9,10). If the parents are clinically unaffected, the risk to siblings after an affected child is born is slightly higher than that of the general population because of the possibility of non-penetrance and germline mosaicism (15-17). Approximately 85-90% of individuals with a mutant form of *FLT4* develop lower limb lymphedema by the age of three years, indicating that 10-15% of individuals with a mutant form of *FLT4* are clinically unaffected (12). In addition, *de novo* mutations have been reported; however, the proportion of cases remains unknown (7,12).

Here, we describe two novel missense mutations in *FLT4*: p.Leu845Pro and p.Glu1336Lys. To date, more than 70 mutations in *FLT4* have been reported, most of

which are missense mutations, although insertions and deletions have occasionally been reported (2,9). The two different heterozygous mutants, each from the parents with a normal phenotype, could be expressed together as compound heterozygotes in the patient and her brother, both of which developed Milroy disease. There has been a study that pathogenic variants of *FOXC2* which is already known for developing lymphedema with distichiasis and *PIEZO1* which causes autosomal recessive congenital lymphatic dysplasia were found in different combinations including compound heterozygosity in clinically affected individuals with familial lymphedemas (18-20). To the best of our knowledge, however, there have been no reports of compound heterozygosity in *FLT4* variants in patients with Milroy disease.

Considering indices of pathogenicity of the two mutations we found in the present case, both mutations are unlikely to be pathogenic. First, the leucine to proline mutation which was found in the siblings' mother and maternal grandfather could be damaging. Since proline has very rigid structure, known as breaker of secondary structures of protein, it causes a bend though it depends on where the protein it is located (21). Secondly, the glutamine to lysine mutation from the siblings' father may be less likely to be pathogenic as lysine has roughly the same side-chain entropy as glutamine (22). Therefore, having two mild mutations, each might be very variably penetrant, or not at all on its own. However, in compound heterozygous condition they could be fully penetrant. It's not surprising that, in this autosomal recessive like case, two siblings could be affected since the odds are 1:16.

Even if it's a small possibility, we could not exclude that p.Leu845Pro mutation alone might lead to the development of Milroy disease with the possibility of non-penetrance of the patient's mother and maternal grandfather. In non-penetrance cases, one can be found to be clinically unaffected while carrying disease-causing mutations (15). Additional genetic testing of other clinically affected family members, including the patient's maternal great aunt and another great aunt's

daughter, could help to determine the mechanism of inheritance.

The siblings had similar clinical findings and onset, matching Milroy disease, whereas the parents were clinically unaffected. The presence of two mutations in *FLT4*, inherited from each parent, is indirect evidence of compound heterozygosity or non-penetrance of inheritance in Milroy disease.

CONCLUSION

The present case showed the occurrence of Milroy disease in all offspring from normal-phenotype parents. Two novel causative mutations were detected in *FLT4*, p.Leu845Pro, and p.Glu1336Lys. We suggest that the cause of the two mutants being expressed together only in siblings with manifestations of Milroy disease, might be compound heterozygosity or non-penetrance in the inheritance of Milroy disease.

CONFLICT OF INTEREST AND DISCLOSURE

The authors declare no competing financial interests exist.

REFERENCES

1. Grada, AA, TJ Phillips: Lymphedema: Pathophysiology and clinical manifestations. *J. Am. Acad. Dermatol.* 77 (2017), 1009-1020. doi:10.1016/j.jaad.2017.03.022
2. Liu, N, M Gao: *FLT4* mutations are associated with segmental lymphatic dysfunction and initial lymphatic aplasia in patients with Milroy disease. *Genes (Basel)* 12 (2021). doi:10.3390/genes12101611
3. Ferrell, RE, KL Levinson, JH Esman, et al: Hereditary lymphedema: Evidence for linkage and genetic heterogeneity. *Hum. Mol. Genet.* 7 (1998), 2073-2078. doi:10.1093/hmg/7.13.2073
4. Mellor, RH, CE Hubert, AW Stanton, et al: Lymphatic dysfunction, not aplasia, underlies Milroy disease. *Microcirculation* 17 (2010), 281-296. doi:10.1111/j.1549-8719.2010.00030.x
5. Tiwari, A, KS Cheng, M Button, et al: Differential diagnosis, investigation, and current treatment of lower limb lymphedema. *Arch. Surg.* 138 (2003), 152-161. doi:10.1001/archsurg.138.2.152
6. Connell, FC, K Gordon, G Brice, et al: The classification and diagnostic algorithm for primary lymphatic dysplasia: an update from 2010 to include molecular findings. *Clin. Genet.* 84 (2013), 303-314. doi:10.1111/cge.12173
7. Evans, AL, R Bell, G Brice, et al: Identification of eight novel VEGFR-3 mutations in families with primary congenital lymphoedema. *J. Med. Genet.* 40 (2003), 697-703. doi:10.1136/jmg.40.9.697
8. Evans, AL, G Brice, V Sotirova, et al: Mapping of primary congenital lymphedema to the 5q35.3 region. *Am. J. Hum. Genet.* 64 (1999), 547-555. doi:10.1086/302248
9. Melikhan-Revzin, S, A Kurolap, E Dagan, et al: A novel missense mutation in *FLT4* causes autosomal recessive hereditary lymphedema. *Lymphat. Res. Biol.* 13 (2015), 107-111. doi:10.1089/lrb.2014.0044
10. Ghalamkarpour, A, W Holthoner, P Saharinen, et al: Recessive primary congenital lymphoedema caused by a *VEGFR3* mutation. *J. Med. Genet.* 46 (2009), 399-404. doi:10.1136/jmg.2008.064469
11. Gokhale, S, S Gokhale: Four generations of rare familial lymphedema (Milroy disease). *Med. Princ. Pract.* 22 (2013), 593-596. doi:10.1159/000351571
12. Gordon, K, SL Spiden, FC Connell, et al: *FLT4/VEGFR3* and Milroy disease: novel mutations, a review of published variants and database update. *Hum. Mutat.* 34 (2013), 23-31. doi:10.1002/humu.22223
13. Mendola, A, MJ Schlögel, A Ghalamkarpour, et al: Mutations in the VEGFR3 signaling pathway explain 36% of familial lymphedema. *Mol. Syndromol.* 4 (2013), 257-266. doi:10.1159/000354097
14. Holberg, CJ, RP Erickson, MJ Bernas, et al: Segregation analyses and a genome-wide linkage search confirm genetic heterogeneity and suggest oligogenic inheritance in some Milroy congenital primary lymphedema families. *Am. J. Med. Genet.* 98 (2001), 303-312. doi:10.1002/1096-8628(20010201)98:4<303::aid-ajmg1113>3.0.co;2-9
15. Brice, G, AH Child, A Evans, et al: Milroy disease and the VEGFR-3 mutation phenotype. *J. Med. Genet.* 42 (2005), 98-102. doi:10.1136/jmg.2004.024802

16. Brouillard, P, L Boon, M Vikkula: Genetics of lymphatic anomalies. *J. Clin. Invest.* 124 (2014), 898-904. doi:10.1172/JCI71614
17. Sakumi, K: Germline mutation: De novo mutation in reproductive lineage cells. *Genes Genet. Syst.* 94 (2019), 3-12. doi:10.1266/ggs.18-00055
18. Mustacich, DJ, Lai LW, Bernas MJ, et al: Digenic inheritance of a *FOXC2* mutation and two *PIEZO1* mutations underlies congenital lymphedema in a multigeneration family. *Am. J. Med.* 135 (2022), e31-e41. doi:10.1016/j.amjmed.2021.09.007
19. Tavian, D, Missaglia S, Michelini S, et al: *FOXC2* disease mutations identified in lymphedema distichiasis patients impair transcriptional activity and cell proliferation. *Int. J. Mol. Sci.* 21 (2020), 5112. doi:10.3390/ijms21145112
20. Alper, SL: Genetic diseases of *PIEZO1* and *PIEZO2* dysfunction. *Curr. Top .Membr.* 79 (2017), 97-134. doi: 10.1016/bs.ctm.2017.01.001
21. Khan, S, M Vihinen: Spectrum of disease-causing mutations in protein secondary structures. *BMC Struct. Biol.* 56 (2007). doi:10.1186/1472-6807-7-56
22. Anstrom, DM, L Colip, B Moshofsky, et al: Systematic replacement of lysine with glutamine and alanine in Escherichia coli malte synthase G: Effect on crystallization. *Acta Crystallogr. Sect. F Struct. Biol. Cryst. Commun.* 61 (2005), 1069-74. doi:10.1107/S1744309105036559

So Young Lim, MD, PhD
Department of Plastic Surgery
Samsung Medical Center
Sungkyunkwan University School of Medicine
81 Irwon-ro, Gangnam-gu
Seoul, Republic of Korea 06351
Tel: 82-2-3410-2239
Fax: 82-2-34100-036
E-mail: pslisy@naver.com