

## MODIFIED LYMPHOSCINTIGRAPHY IN PRIMARY LYMPHATIC INSUFFICIENCY OF THE LOWER LIMB

M. Wald, J. Svobodova, H. Krizova

Department of Surgery, Unit of Lymphatic Surgery (MW), Department of Surgery, Department of Nuclear Medicine and Endocrinology (JS,HK), 2<sup>nd</sup> Medical Faculty of Charles University and University Hospital Motol, Prague, Czech Republic

### ABSTRACT

*Primary lymphedema of the foot and toes could be sometimes misdiagnosed by lymphoscintigraphy as a whole lower limb lymphatic insufficiency (LLLI). This is caused by using standard lymphoscintigraphic protocol based on one interstitial injection of radiotracer applied into the first interdigital space followed by image analysis of lower limb lymphatic vessels and lymph nodes. Here, we show that a modification of the lymphoscintigraphic protocol and introduction of a second dose of radiotracer right above the inner ankle to the clinically healthy tissue can more accurately describe morphological abnormalities of the superficial lymphatic system at the lower limb and thereby refine the diagnosis of the LLLI.*

*Fourteen patients with swelling of the foot and toes (16 lower limbs) were examined using standard lymphoscintigraphic protocol. Subsequently, modified lymphoscintigraphy was performed. While standard lymphoscintigraphy showed severe lymphatic insufficiency of the superficial lymphatic system in all 14 patients (in 16 lower limbs), including significantly reduced number of inguinal nodes, modified lymphoscintigraphy revealed almost normal morphology of superficial lymphatic vessels in 11 patients (in 13 lower limbs) throughout the entire lower limb proximal to the application site.*

*In conclusion, using the modified*

*lymphoscintigraphy protocol in patients with foot and toes primary lymphedema can refine diagnosis and follow-up medical management.*

**Keywords:** lymphatic insufficiency, lymphedema, standard lymphoscintigraphy, modified lymphoscintigraphy, therapy

The lymphatic system, which drains the interstitial space of virtually all tissues, has an irreplaceable function in terms of homeostasis of the body. The transport of the lymph containing cellular and acellular components through the lymphatic vessels into the lymph nodes has key immune and metabolic roles (1).

Lymphatic insufficiency, or impairment of the drainage function of the lymphatic system, results in a variety of subsequent pathological processes clinically evident especially in the subcutaneous tissue and in the skin. The most important clinical manifestations include lymphedema and recurrent soft tissue infections (2). If the appropriate therapy is not initiated in time, both of these pathologies cause remodeling of the extracellular space mainly in terms of fibrosis and/or lipohypertrophy (3).

Nowadays, the most common causes of secondary (acquired) lymphatic insufficiency include lymphadenectomy, radiotherapy, trauma, complicated tissue healing with subsequent development of extensive scarring, recurrent inflammatory diseases of the subcutaneous tissue and, in tropical regions, also

parasitic diseases (filariasis). Less common primary (congenital) lymphatic insufficiency is caused by aplasia or hypoplasia of the lymphatic vessels and/or lymph nodes (4,5).

While the secondary lymphatic insufficiency of lower limb (including thigh, lower leg, foot, and toes regions) can be predicted with a high probability due to known medical history, the primary lymphatic insufficiency may manifest itself only by subjective health problems for many years or decades without any clinically evident signs. This can lead to significant underdiagnosis of the early stage of the primary lymphatic insufficiency (latent stage of lymphedema). Based on the severity of the congenital disorder, primary lymphatic insufficiency may manifest clinically at any time during life either by swelling in the foot and toes area (distal type) or in the thigh area (proximal type) (6).

Although the protocol for lymphoscintigraphy (radionuclide lymphography) can differ among diagnostic centers (choice of radiotracer, subcutaneous/intradermal application, dose of radiopharmaceutical), lymphoscintigraphy remains the gold standard in imaging the lymphatic system and in the diagnosis of its morphological and functional disorders. Standard lymphoscintigraphy of the superficial lymphatic system of lower limbs is performed by applying radiotracer intradermally or subcutaneously in the first web space of both feet. Standard lymphoscintigraphy of the deep lymphatic systems of the lower limbs is performed by applying radiotracer intramuscularly, for example, into the sole of both feet. Lymphoscintigraphy visualizes both the morphology of the lymphatic system (lymphatic vessels and nodes) and, to some extent, lymphatic drainage effectiveness (transport capacity) (7-10).

In some cases of the lower limb lymphedema (including thigh, lower leg, foot, and toes regions) the standard lymphoscintigraphy of superficial lymphatics does not show any lymphatic nodes in the groin area. However, Bourgeois and Leduc reported that in such cases one additional injection of the radiotracer at the root of the edematous limb (above thigh region) allows detection and visualiza-

tion of collateral lymphatic pathways and lymph nodes (11).

In contrast, when lymphedema is limited only to the foot and toes without clinical signs of lymphatic insufficiency in the lower leg and thigh, standard lymphoscintigraphy usually describes not only absence of inguinal and pelvic lymph nodes but also a severe morphological disorder (hypoplasia/aplasia) of the lymphatic vessels of the entire lower limb.

Importantly, the findings of the lymphoscintigraphy, regardless of the absence of edema in the lower leg and thigh regions, often result in initiation of complex decongestive therapy (CDT) with emphasis on daily wearing of compression stockings from the toes to the groin. In some cases, surgery may be considered (e.g., microsurgical procedures). The discrepancy between pathological findings in the standard lymphoscintigraphy of the lower limb on one hand but normal clinical findings in the lower leg and thigh on the other one is usually not taken into account at all.

Given this discrepancy between the results of standard lymphoscintigraphy and clinical findings, we asked ourselves the following three questions: 1) Do results of the standard lymphoscintigraphy correlate with the clinical findings in patients who are affected by the distal type of the lower limb primary lymphedema? 2) What will be the result of lymphoscintigraphy if the radiotracer is injected into the clinically healthy tissue right above inner ankle? We have called this procedure as Modified lymphoscintigraphy. 3) Can we learn more about the morphology and function of the lymphatic system of the lower limb by using the Modified lymphoscintigraphy?

The presented protocol of Modified lymphoscintigraphy is based on additional subcutaneous application of radiotracer into the clinically healthy tissue above the inner ankle in cases of distal type of lymphedema which is limited only to the foot and toes. In contrast to standard lymphoscintigraphy, we show that in cases of distal type of lymphedema (limited to toes and foot region) the Modified lymphoscintigraphy provides more accurate information about lymphatic vessels morphology of the lower leg and thigh and detects the pres-

ence of inguinal nodes. These more detailed information can have influence on decision about the follow-up treatment.

## MATERIALS AND METHODS

### Patients

The clinical and lymphoscintigraphic examination of patients was performed in accordance with the ethical standards approved by the ethics committee of the University Hospital Motol, Prague. All patients signed informed consent providing them with all information related to the lymphoscintigraphic method used prior to lymphoscintigraphic examination. In case of children examination, the informed consent was signed by a legal representative.

Fourteen patients (M/F: 10/4, mean age 30.6 years, range 3-60 years of age) were referred to the Unit of Lymphatic Surgery, Department of Surgery, 2nd Medical Faculty of Charles University and University Hospital Motol, Prague between January 2013 and December 2019 for performance of edema differential diagnosis of the foot and toes.

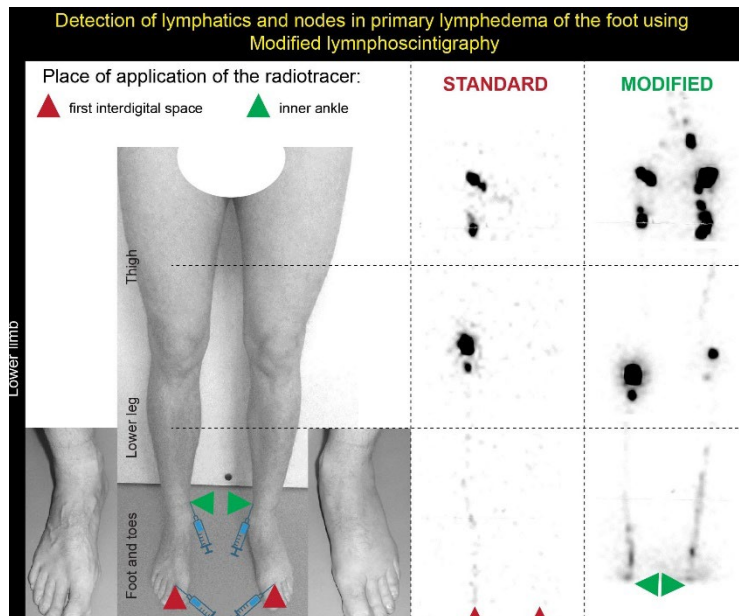
Twelve patients had unilateral and two

(siblings) had bilateral edema. Importantly, in all patients, only edema of the foot and toes was present. There was no clinical evidence of swelling or other signs of lymphatic insufficiency between groin and ankle. None of the patients had any clinical symptoms that would indicate any other type of primary lymphatic anomalies (12,13). None of the patients underwent genetic testing. The mean duration of clinical follow-up was 6 years (range 3-9 years).

### Protocol of Modified Lymphoscintigraphy

All patients underwent standard lymphoscintigraphy of the superficial lymphatic system of both lower limbs according to previously published protocols (7,9). The Technetium-99m-labeled nano-colloid radiotracer was injected subdermally in the first web space of both feet.

In some patients, standard lymphoscintigraphy of the deep lymphatic system of both lower limbs was performed by application of the radiotracer intramuscularly into the sole of both feet with a time gap. In children, the applied radiotracer dose was calculated according to the recommendations of the European Association of Nuclear Medicine.



**Fig. 1. The schematics showing the difference in application of radiotracer between standard and Modified lymphoscintigraphy.**

When the discrepancy between standard lymphoscintigraphy (severe lymphatic insufficiency) and clinical picture (no swelling of lower leg and thigh present) was found a second (Modified) lymphoscintigraphy with application of radiotracer right above the inner ankle into the clinically healthy tissue (*Fig. 1*) was performed after a time interval at least 48 hours. In all cases, whole lower limbs and pelvis were imaged after 30 minutes of rest, after 30 minutes of walking and in some cases after 180 minutes.

## RESULTS

Fourteen patients (16 lower limbs) were examined for suspected primary lymphatic insufficiency of the lower limbs with clinically evident edema only in the foot and toes. Twelve patients had clinical evidence of edema in only one lower limb and 2 patients (siblings) in both limbs. Standard lymphoscintigraphy of the superficial lymphatic system (and in some cases of the deep lymphatic system) showed severe lymphatic insufficiency in all 14 patients (16 lower limbs), respectively (*Figs. 2A,2B,3A,4A,4B,5A,5B*). The radiotracer became stagnant at the site of the application. The superficial lymphatic vessels were either not visualized at all, or only very poorly, and only after exercise by walking (right panels in *Figs. 2A,3A,4A,5A*). The inguinal lymph nodes were not visualized at all or in very small amounts only after exercise by walking and with minimal radiotracer accumulation. In some cases, lymphoscintigram of the superficial lymphatic system showed drainage by the deep lymphatic system (*Fig. 4A*). Dermal backflow was present in two patients. In one patient in the lower leg, in the other patient in both the lower legs and thighs (*Fig. 6*).

In contrast to standard lymphoscintigraphy, Modified lymphoscintigraphy with radiotracer applied into the clinically healthy tissue right above the inner ankle showed almost normal morphology of superficial lymphatic vessels throughout the lower leg and thigh in 11 patients (13 lower limbs), respectively (*Figs. 2C,3B,4C,5C*). The inguinal lymph nodes were imaged and, especially after exercise, showed

normal or near-normal radiotracer accumulation (right panels in *Figs 2C,3B,4C,5C*). No dermal backflow was present in the lower limb in any of these patients (*Figs. 2A,2B,3A,4A,4B,5A,5B*).

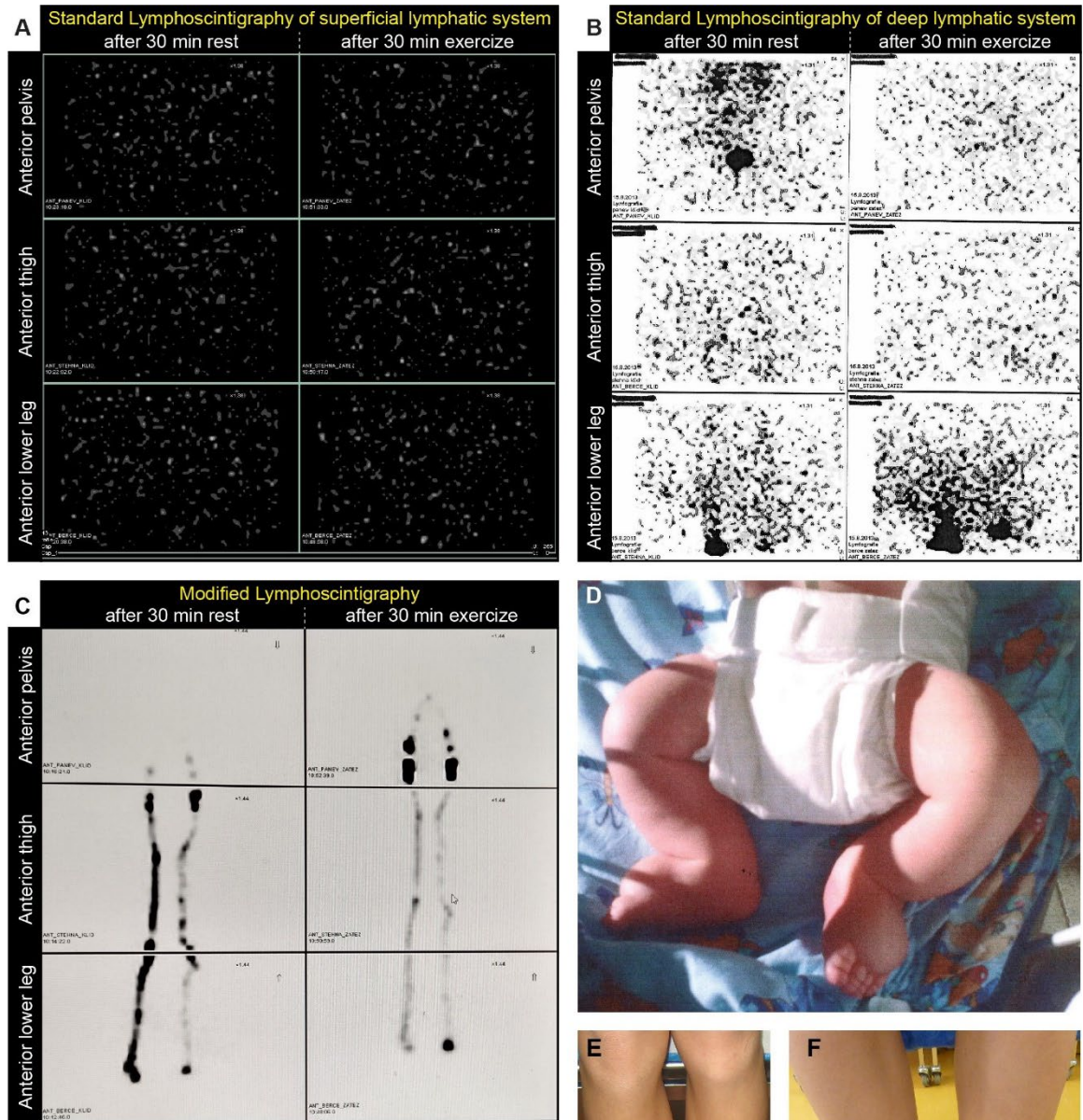
In 3 patients, the result of modified lymphoscintigraphy was identical to standard lymphoscintigraphy – severe lymphatic insufficiency (data not shown).

## DISCUSSION

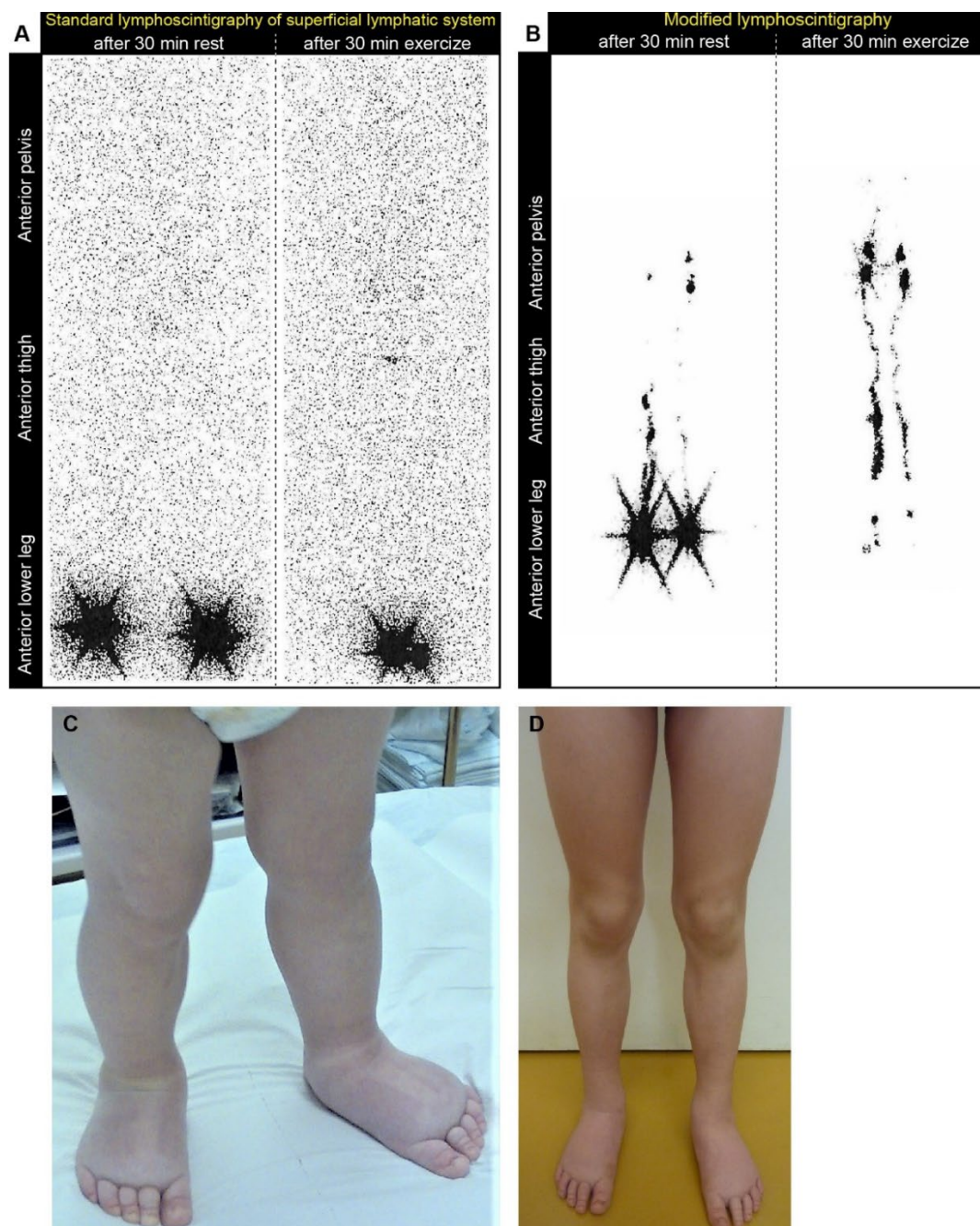
Despite more than a century of research focused on the embryonic development of the lymphatic system, the debate is far from over. Moreover, anatomical description of the lymphatic system of the foot remains imprecise (14). The first description of embryonic development of the lymphatic system was described by Sabin in 1909 (15) who suggested three different origins of lymphatics. Centrifugal (venous origin), in which lymphatic vessels are formed by budding of the endothelium of preexisting veins. Centripetal (non-venous origin), where lymphatic vessels arise by differentiation from mesenchyme in situ. Dual, according to which both previous theories are applied simultaneously depending on the localization. Deep lymphatic vessels are formed by budding and superficial lymphatic vessels by differentiation from mesenchyme.

Sabin's theory was later modified by other authors (16,17). Although the scientific knowledge of developmental anomalies of lymphatic vessels and nodes as a result of genetic mutations have advanced significantly (12,18), we did not find any explanation for the above-mentioned discrepancy between results of standard and Modified lymphoscintigraphies.

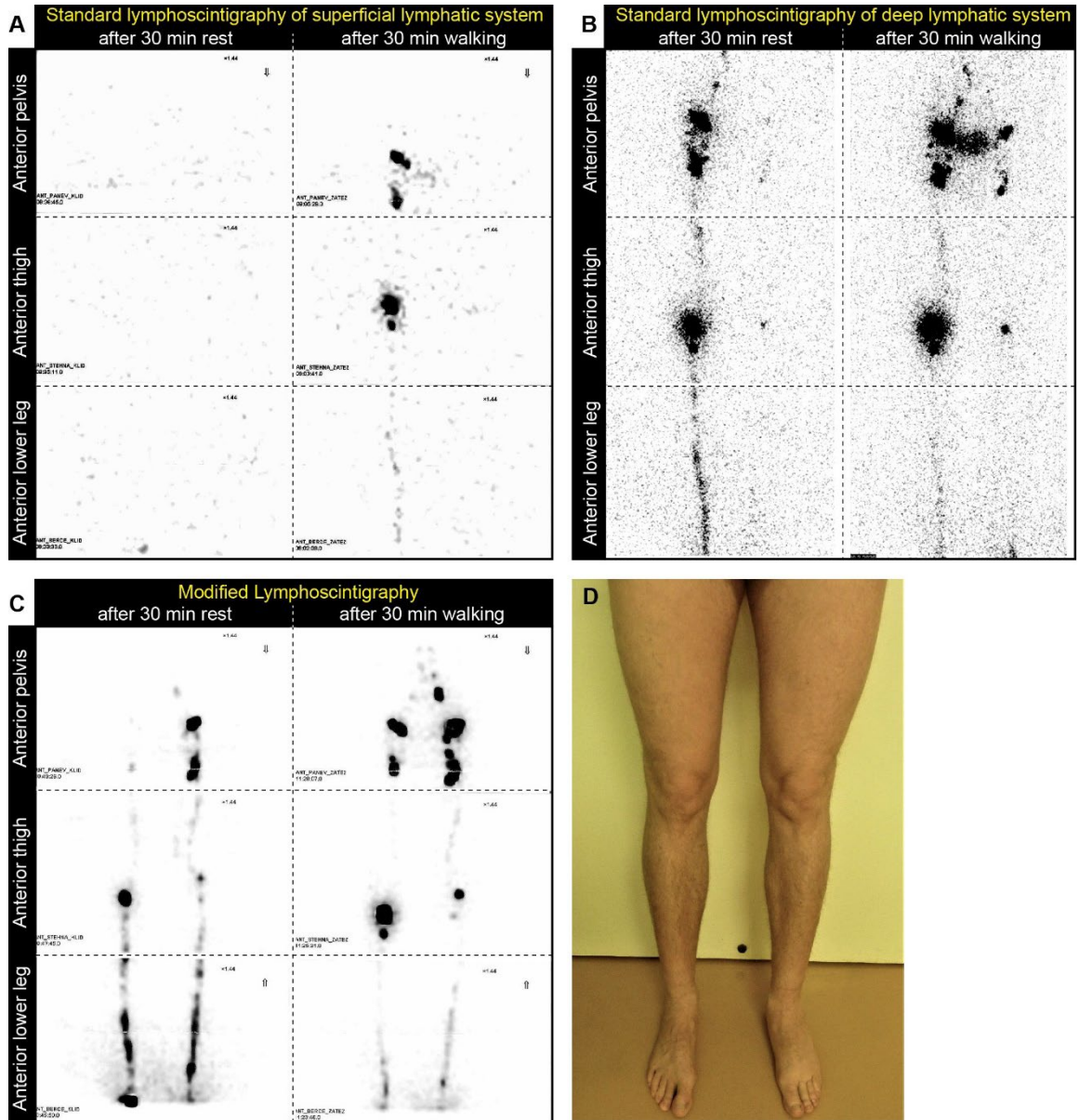
On the basis of the developmental theories, we speculate that the different results of standard and Modified lymphoscintigraphy of the distal form of lymphedema of the lower limb may be explained by a defect in the development of the foot lymphatic capillaries including lymphatic network and their connections with the lymphatic collectors above the ankle. However, up to date no evidence regarding genetic predispositions exists.



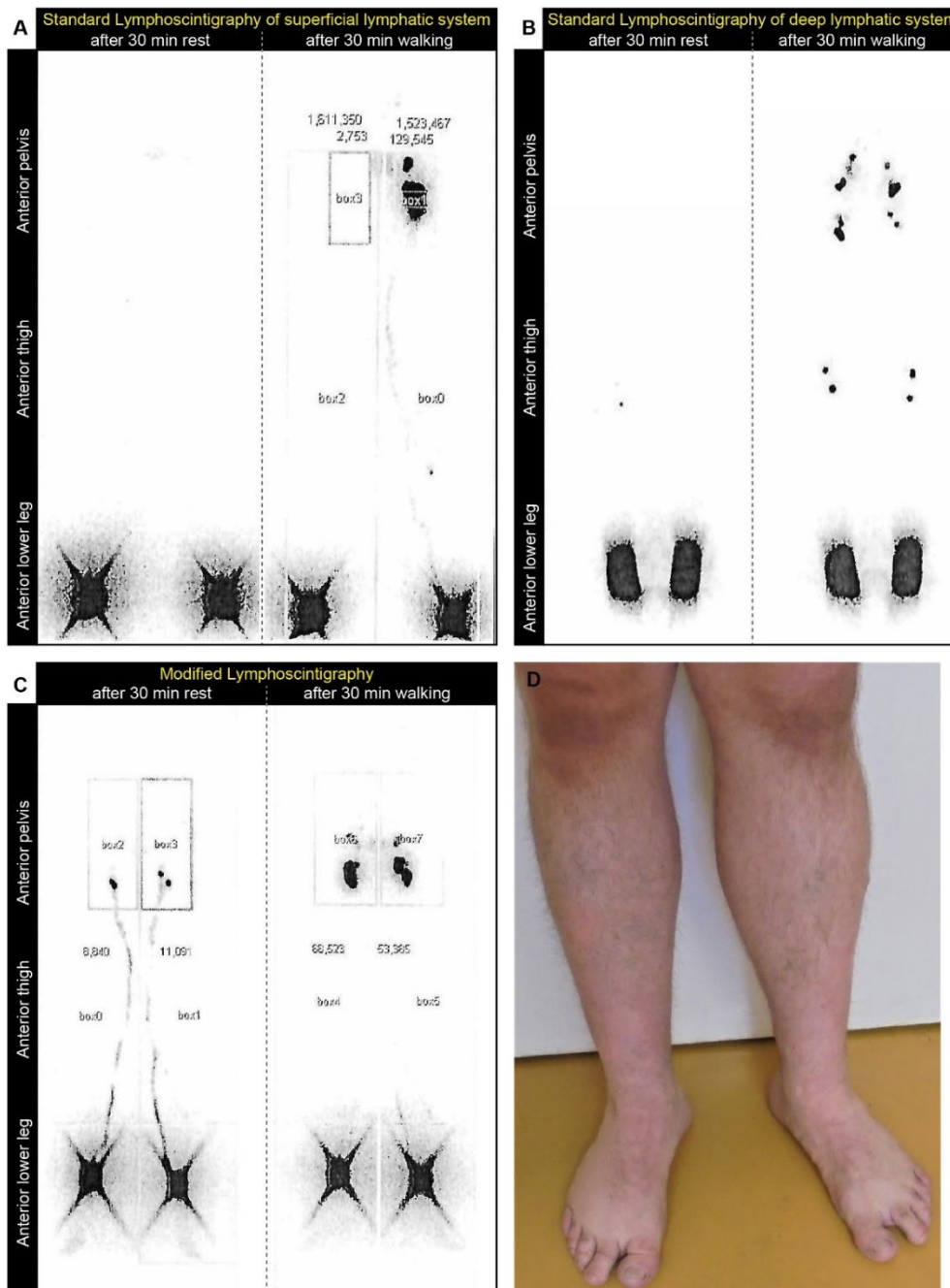
**Fig. 2. Primary lymphatic insufficiency of both lower limbs according to the standard lymphoscintigraphy in a girl with edema clinically visible immediately after birth only in feet and toes. (A and B) Standard lower limbs lympho-scintigraphy with application of radiotracer for investigation of (A) superficial and (B) deep lymphatic systems in rest and after walking. (C) Modified lympho-scintigraphy with application of radiotracer subcuta-neously to clinically healthy tissue above the inner ankle of the lower limbs in rest and after exercise. (D-F) Clinical pictures of development of soft tissues condition (D) at birth in 2001, (E) at 13 years, and (F) 20 years of her age.**



**Fig. 3. Primary lymphatic insufficiency of both lower limbs according to the standard lympho-scintigraphy in a boy with edema clinically visible immediately after birth only in feet and toes. (A) Standard lymphoscintigraphy of the lower limbs with application of radiotracer for investigation of superficial lymphatic system in rest and after exercise. (B) Modified lymphoscintigraphy with application of radiotracer subcutaneously right above the inner ankle of the lower limbs into the clinically healthy tissue in rest and after walking. (C and D). Clinical pictures at (C) 2 years of age (2013), and (D) at 8 years of age (2019).**

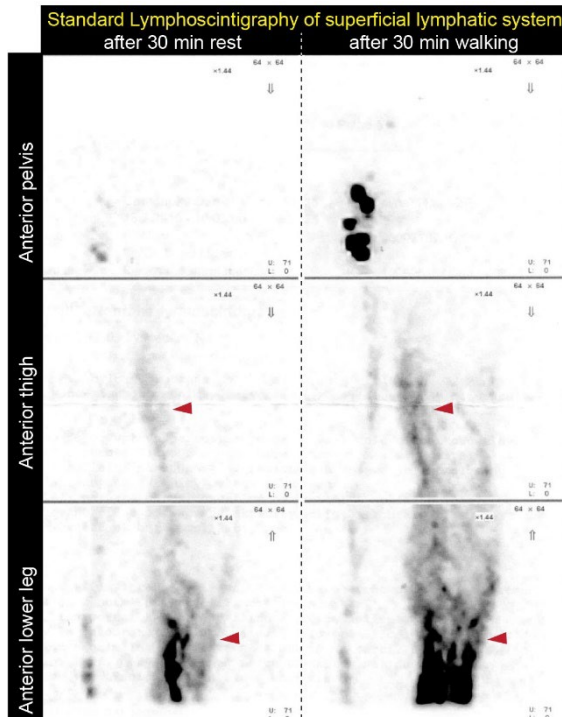


**Fig. 4. Edema of the left foot and toes in male manifested for the first time at 32 years of age and diagnosed by standard lymphoscintigraphy as the lymphatic insufficiency of the entire lower limb including absence of inguinal nodes. (A and B) Standard lymphoscintigraphy of the lower limbs with application of radiotracer for investigation of (A) superficial, and (B) deep lymphatic system in rest and after walking. (C) Modified lymphoscintigraphy with application of radiotracer subcutaneously right above the inner ankle of the lower limbs into the clinically healthy tissue in rest and after walking. (D) Clinical picture of patient (2016).**



**Fig. 5. Edema of the right foot and toes in male manifested for the first time at 37 years of his age and diagnosed by standard lymphoscintigraphy as the lymphatic insufficiency of the entire lower limb. (A and B) Standard lymphoscintigraphy of the lower limbs with application of radiotracer for investigation of (A) superficial, and (B) deep lymphatic system in rest and after walking. (C) Modified lymphoscintigraphy with application of radiotracer subcutaneously above the inner ankle of the lower limbs into the clinically healthy tissue in rest and after walking. (D) Clinical picture of patient at 40 years of age.**





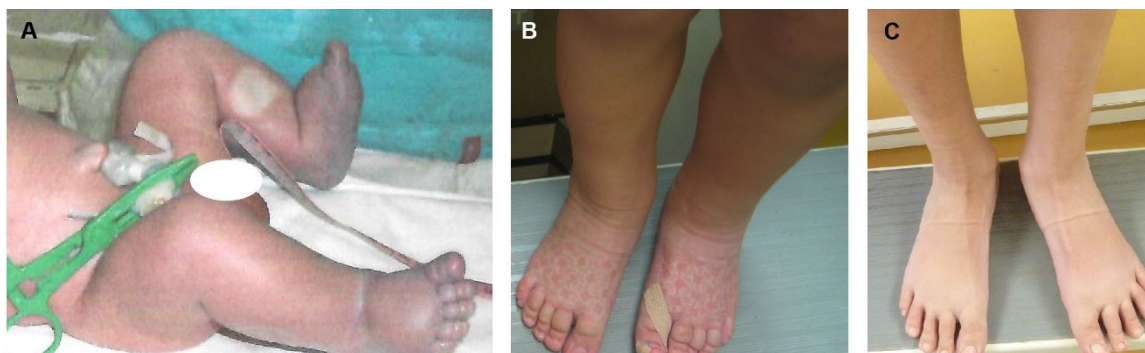
**Fig. 6. Dermal backflow in a patient with primary lymphatic insufficiency of the left lower limb.** Dermal backflow is present in the lower leg and thigh of one of the patients, in whom both standard and Modified lymphoscintigraphy showed severe lymphatic insufficiency (dermal backflow highlighted by arrowheads).

Dermal backflow indicates the presence of radiotracer in dermal lymphatics, and it indicates that lymph flows from collectors back to the dermis due to incompetence of valvules. It seems logical, that dermal backflow did not appear on standard lymphoscintigrams in cases characterized by simultaneous presence of the following two conditions: 1) there were no clinical signs of lymphedema in lower leg and thigh, and 2) Modified lymphoscintigraphy showed normal or near-normal morphology and function of the lymphatic system in lower leg and thigh as well as inguinal nodes. Altogether, the absence of dermal backflow during standard lymphoscintigraphy of the superficial and deep lymphatic system, which suggests the absence or dysfunction of lymphatic collectors in the

lower limb and inguinal lymph nodes, should be the reason for performing a modified lymphoscintigraphy.

We are aware that this has not to be a rule, however, to clarify the extent of primary lymphatic insufficiency on the lower limb, the absence of dermal back flow in the above combination of findings 1) and 2) may be a reason to further clarify the diagnosis, for example contrast MR or Near-infrared fluorescence lymphatic imaging (19). To choose an adequate therapy a precise knowledge of the morphology and function of the lymphatic system is essential. This is even more important in infants, toddlers and children, where the first-choice treatment usually consists of CDT, and it should be started as soon as the diagnosis of lymphatic insufficiency as the cause of foot swelling is confirmed. In our experience, the earlier the treatment with application of compression to the area with clinical signs of lymphatic insufficiency starts the better is the treatment outcome and prognosis on the future condition of soft tissues affected by lymphatic insufficiency (Figs. 7, 2D-F). In case of normal or nearly normal lymphoscintigram in modified lymphoscintigraphy it is possible to apply compression only to the affected part of the lower limb (toes, foot, and ankle area). This is even more important in infants and toddlers because the appropriate compression does not limit their normal physical development and prevents sense of handicap in adolescents (20). Importantly, appropriate compression also results in higher compliance to wearing compression, and increased treatment effectiveness ultimately leading to better clinical outcomes. However, clinical follow-up and repeated lymphoscintigraphy over the next few years are necessary, as we do not yet have enough information to decide whether there might occur a progressive deterioration of the function of both the lymphatic collectors in the proximal parts of the lower limb and the inguinal and pelvic lymph nodes over the course of life.

In adults, a precise knowledge of the morphology and function of the lymphatic system is important for determining the extent of conservative therapy, and for surgical treat-



**Fig. 7.** Early start of the treatment with application of compression to the area with clinical signs of edema can have a significant positive impact on the future condition of soft tissues affected by lymphatic insufficiency. Development of soft tissues condition in boy (A) at birth 2011, (B) at 3 years, and (C) at 10 years of age. (Pictures of the development of soft tissues condition of his sister see Figures 2D-F).

ment if indicated. It is questionable whether it is appropriate to perform lympho-venous anastomosis in primary lymphatic insufficiency based on standard lymphoscintigraphy only, if lymphedema is clinically visible only in foot and toes. The Modified lymphoscintigraphy can show normal or nearly normal morphology of the superficial lymphatic vessels of the lower leg and thigh, and sufficient number of inguinal and pelvic lymph nodes. For this reason, we always perform additional modified lymphoscintigraphy with subdermal application of radiotracer to clinically healthy tissue in the inner side of the lower limb right above the ankle before making the decision of applying lympho-venous anastomosis in primary lymphatic insufficiency. This approach has repeatedly proved to be successful for two reasons. If the modified lymphoscintigraphy demonstrated a functional superficial lymphatic system with a sufficient number of inguinal lymph nodes, we did not consider the indication for a lympho-venous anastomosis. If the Modified lymphoscintigraphy revealed a functional collector below the groin but did not show the presence of inguinal lymph nodes, lympho-venous anastomosis was indicated.

## CONCLUSION

The use of Modified lymphoscintigraphy

in the distal form of primary lymphedema of the lower limb reveals two important findings. First, if edema is present only in the foot and toes, it does not necessarily mean that the superficial lymphatic system of the proximal part of the lower limb is also affected by hypoplasia or aplasia of lymphatic vessels and/or lymph nodes. Second, if standard lymphoscintigraphy demonstrates hypoplasia or aplasia of lymphatic vessels and/or lymph nodes of the lower limb without dermal backflow, this should be a reason to perform modified lymphoscintigraphy.

Implementation of Modified lymphoscintigraphy allowed us to focus the CDT on the affected area, with very good, and importantly, long-lasting improvement. Especially in young children with clinical signs of primary lymphedema of the distal type, the performance of Modified lymphoscintigraphy may make long-term conservative complex treatment more efficient.

## ACKNOWLEDGMENTS

Authors are grateful to Prof. Oldrich Eliska MD (†) for his contribution to the discussion about theories of lymphatic system development.

## CONFLICT OF INTEREST AND DISCLOSURE

The authors declare no competing financial interests exist.

## REFERENCES

1. Lymphology, Exec. Committee of the ISL: The Diagnosis and Treatment of Peripheral Lymphedema: 2020 Consensus Document of the International Society of Lymphology. *Lymphology* 53 (2020), 3-19.
2. Ly, CL, RP Kataru, BJ Mehrara: Inflammatory manifestations of lymphedema. *Int. J. Mol. Sci.* 18 (2017).
3. Kataru, RP, I Wisner, JE Baik, et al: Fibrosis and secondary lymphedema: Chicken or egg? *Transl. Res.* 209 (2019), 68-76.
4. Grada, AA, TJ Phillips: Lymphedema: Pathophysiology and clinical manifestations. *J. Am. Acad. Dermatol.* 77 (2017), 1009-1020.
5. Mortimer, PS. Swollen lower limb-2: Lymphoedema. *BMJ.* 320 (2000), 1527-1529.
6. Schook, CC, JB Mulliken, SJ Fishman, et al: Differential diagnosis of lower extremity enlargement in pediatric patients referred with a diagnosis of lymphedema. *Plast. Reconstr. Surg.* 127 (2011), 1571-1581.
7. Bourgeois, P, D Munck, C Becker, et al: A three-phase lymphoscintigraphic investigation protocol for the evaluation of lower limb edemas. *The Eur. J. Lymphology Rel. Prob.* 6 (1997), 10-21.
8. Szuba, A, WS Shin, HW Strauss, et al: The third circulation: Radionuclide lymphoscintigraphy in the evaluation of lymphedema. *J. Nucl. Med.* 44 (2003), 43-57.
9. Villa, G, CC Campisi, M Ryan, et al: Procedural recommendations for lymphoscintigraphy in the diagnosis of peripheral lymphedema: The Genoa protocol. *Nucl. Med. Mol. Imaging* 53 (2019), 47-56.
10. Hassanein, AH, RA Maclellan, FD Grant et al: Diagnostic accuracy of lymphoscintigraphy for lymphedema and analysis of false-negative tests. *Plast. Reconstr. Surg. Glob. Open* 5 (2017), e1396.
11. Bourgeois, P, O Leduc: Value of one additional injection at the root of the limb in the lymphoscintigraphic evaluation and management of primary and secondary lower-limb lymphedemas. *Plos One* 16 (2021), e0253900.
12. Brouillard, P, MW Witte, RP Erickson, et al: Primary lymphoedema. *Nat. Rev. Dis. Primers* 7 (2021), 77.
13. Gordon, K, R Varney, V Keele, et al: Update and audit of the St George's classification algorithm of primary lymphatic anomalies: A clinical and molecular approach to diagnosis. *J. Med. Genet.* 57 (2020), 653-659.
14. Amore, M, R Bernardez, V Sgarbanti, et al: Plantar lymphatic network. *Lymphology* 51 (2018), 119-124.
15. Sabin, FR: The lymphatic system in human embryos, with a consideration of the morphology of the system as a whole. *Am. J. Anat.* 9 (1909), 43-91.
16. Semo, J, J Nicenboim, K Yaniv: Development of the lymphatic system: New questions and paradigms. *Development* 143 (2016), 924-935.
17. Martinez-Corral, I, MH Ulymar, L Stanczuk, et al: Nonvenous origin of dermal lymphatic vasculature. *Circ. Res.* 116 (2015), 1649-1654.
18. Brouillard, P, L Boon, M Vikkula: Genetics of lymphatic anomalies. *J. Clin. Invest.* 124 (2014), 898-904.
19. Sevic-Muraca, EM, CE Fife, JC Rasmussen: Imaging peripheral lymphatic dysfunction in chronic conditions. *Front. Physiol.* 14 (2023), 1132097.
20. Hanson, CS, J Newsom, D Singh-Grewal, et al: Children and adolescents' experiences of primary lymphoedema: Semistructured interview study. *Arch. Dis. Child.* 103 (2018), 675-682.

**Martin Wald MD PhD**  
**Assistant Professor**  
**2<sup>nd</sup> Medical Faculty of Charles University**  
**and University Hospital Motol**  
**Prague, V Úvalu 84, 150 06**  
**Czech Republic**  
**E-mail: martin.wald@telecom.cz**