

EXPANDING THE SPECTRUM OF GORHAM STOUT DISEASE EXPLORING A SINGLE CENTER PEDIATRIC CASE SERIES

**I. Rana, P.S. Buonomo, G. Mastrogiorgio, A. Del Fattore, A. Jenkner,
D. Barbuti, R. De Vito, M. Pizzoferro, M. Callea, M. Crostelli,
O. Mazza, R. Rotunno, A. Bartuli**

Rare Diseases and Medical Genetics (IR,PSB,GM,AB); Bone Physiopathology Research Unit (ADF); Division of Immunology and Infectious Diseases (AJ); Pediatric Radiology (DB); Laboratory of Histopathology (RDV); Nuclear Medicine (MP); Unit of Dentistry (MCa); Vertebral Surgery (MCR); Pediatric Department (OM) and Pediatric Dermatology (RR), Bambino Gesù Children's Hospital, IRCCS, Rome, Italy

ABSTRACT

Gorham-Stout Disease (GSD), also named vanishing bone disease, is an ultrarare condition characterized by progressive osteolysis with intraosseous lymphatic vessel proliferation and bone cortical loss. So far, about 300 cases have been reported. It may occur at any age but more commonly affects children and young adults. The aim of this study is to retrospectively review our internal patient series and to hypothesize a diagnostic-therapeutic protocol for earlier diagnosis and treatment. Clinical datasets from our center were examined to identify all GSD patients for collection and analysis. We identified 9 pediatric cases and performed a retrospective case-series review to examine and document both diagnosis and treatment. We found that delay in diagnosis after first symptoms played a critical role in determining morbidity and that multidisciplinary care is key for proper diagnosis and treatment. Our study provides additional insight to improve the critical challenge of early diagnosis and highlights a multidisciplinary treatment approach for the most appropriate management of patients with rare GSD disease. Although GSD is an ultrarare disease, physicians should keep in mind the main clinical features

since neglected cases may result in potentially fatal complications.

Keywords: Gorham-Stout Disease, rare diseases, pediatric

Gorham-Stout disease (GSD), also known as vanishing bone disease, is characterized by extensive and progressive osteolysis with angiomatous proliferation and a replacement of bone by fibrous tissue. It is considered an ultrarare disease: since the first description, published in 1838 and so named by Gorham and colleagues (1954) and by Gorham and Stout (1955), only approximately 300 patients have been so far reported worldwide (1,2). This is not only due to the rarity of the disease but probably also to the diagnostic difficulties caused by its wide variety of clinical presentations. Many patients go undiagnosed from months to years after the onset of symptoms.

The etiology and pathogenesis of the disease still remain unknown, although several studies have discussed the potential role of endothelial cells, osteoclasts, and osteoblasts in its pathogenesis (3-8).

The onset of the disease can occur at any age (ranging from 5 months to 75 years) but it is more commonly diagnosed in children and

young adults. The disease does not show a clear gender or ethnic bias or inheritance pattern. Until now, the possible genetic alterations involved in its pathogenesis have not been completely understood. Preliminary studies by Lorenzo et al have revealed genetic imbalance in GSD patients (9) but no strong candidate mutant gene has yet been identified. There is one recent report identifying a KRAS mutation in a single patient from a small series of six (10).

The clinical presentation of GSD is heterogeneous. It varies according to the involved skeletal segment and to the extension of the lesions. GSD may develop at any site: ribs, skull, clavicle, and cervical spine are more frequently involved; however, pelvis, humerus, scapula, and femur can be affected as well (11-15).

The disease is progressive in most patients, although in few cases it can be self-limiting. The most common symptom is localized pain but swelling, weakness, and functional impairment of affected limbs may also occur. Asymptomatic cases have been reported as well as cases diagnosed after a pathological fracture. Patients with thoracic involvement (ribs, scapula, vertebrae) may develop a chylothorax due to propagation of the disease to the pleural cavity or the thoracic duct. This occurs in approximately 25% of GSD patients and can result in respiratory distress and failure (15). Blood tests are usually unremarkable.

GSD diagnosis is challenging and based on clinical, radiological, and histological findings. Moreover, neoplastic processes, infection, metabolic, and endocrine disorders need to be ruled out (11,16).

Heffez et al in 1983 (17) suggested the following diagnostic criteria: presence of angiomatous tissue in biopsy; absence of cellular atypia; minimal or absent osteoblastic response and no dystrophic calcifications; evidence of local, progressive, bone resorption; non-expansive, non-ulcerative lesion; absence of visceral involvement; osteolytic radiographic pattern; negative hereditary, metabolic, neoplastic, immunological, or infectious etiology.

Due to its rarity, no accepted guidelines are currently available for treatment and management of GSD. The therapeutic options are

based on medical treatment, radiation and/or surgery (18-26).

The aim of this study is to retrospectively review the Bambino Gesù Children's Hospital GSD patient series and to generate a diagnostic-therapeutic protocol for earlier diagnosis and treatment.

PATIENTS AND METHODS

Clinical, radiological, and histological features of all consecutive patients diagnosed at or referred to the Rare Diseases Unit at Bambino Gesù Children's Hospital, IRCCS, Rome, Italy from 2013 onwards are reported. The study was approved by our local ethical committee. According to our internal protocol, each patient underwent clinical evaluation, imaging studies (CT, MRI, X-rays, bone scan, lymphoscintigraphy), dental evaluation (orthopantomography), and biopsy of the lesion. Other conditions that may cause bone resorption (endocrine, malignant, metabolic, infectious) were excluded. Biopsy is presently considered the gold standard diagnostic criterion (27). Treatment plan was established according to recent literature data and after a multidisciplinary team meeting including biologists, clinicians from different specialties, and pathologists. The decision to start therapy was principally based on the presence of symptoms (i.e., pain) and/or of rapidly progressive disease.

RESULTS

In order to design a consistent clinical pathway for all patients referred to our hospital, a standardized approach was devised and utilized since 2016. Based on this, diagnosis was supported by clinical, radiological, and histopathological data according to the criteria proposed by Heffez (17).

Nine patients (7 males, 2 females) followed in our pediatric center since 2013 were included.

The median age at diagnosis was 7.5 years (range 1 month - 25 years). The median age at onset of symptoms was 1.7 years (range 1 month - 6 years). The median interval between initial symptoms and GSD diagnosis was

TABLE 1
Clinical Findings, Biopsy Analysis and Treatments of Patients Affected by Gorham-Stout Disease

Patient	Sex	Age of onset	Age of diagnosis	Symptoms/Signs	Localization	Histology	Treatment
1	F	3 years	25 years	Left groin pain and swelling	Left ilium-sacral region	Vascular malformation (venous-lymphatic)	Bisphosphonates and sirolimus
2	M	2 years	4 years	Pathological fracture	Left femur	Vascular malformation (venous-lymphatic)	Bisphosphonates
3	M	6 years	6 years	Swelling of axillary and left dorsal region; chylothorax	Vertebrae, ribs, left scapula, left humerus	Vascular malformation (venous-lymphatic)	Bisphosphonates and sirolimus
4	M	At birth	3 months	Right half-face swelling	Skull base	Vascular malformation	Bisphosphonates and interferon-alfa2b
5	M	At birth	13 years	Spine pain and angiomatous lesion of the left upper limb	Skull (frontal and temporal bone), vertebrae, sacrum, left ileum, left supra-acetabular region, left humerus and right fifth rib	Vascular malformation (venous-capillary)	Bisphosphonates and interferon-alfa2b
6	M	4 months	5 months	Chylothorax	Vertebrae, right scapula, left humerus and femur, ilium and sacrum	Vascular malformation (venous-lymphatic)	Bisphosphonates and sirolimus
7	M	Prenatal	6 years	Lymphangiomas and meningitis	Skull (petrous, occipital, and sphenoid bone)	Vascular malformation (venous-lymphatic)	Bisphosphonates and sirolimus
8	M	Prenatal	14 years	Lymphangiomas, meningocele and meningitis	Sphenoid bone and left mandible	Vascular malformation (venous-lymphatic)	No treatment
9	F	At birth	2 months	Swelling of the left mandible	Left mandible	Vascular malformation (venous-lymphatic)	No treatment

6.38 years. Two patients had been initially diagnosed elsewhere and then referred to our Center.

The principal characteristics of patients are summarized in *Table 1*. The involved sites observed in our series were: skull (four), vertebral column (three), humerus (three), sacrum, ilium (three), ribs (two), femur (two), mandible (two), and scapula (two). Two patients presented with dyspnea due to chylothorax.

All biopsies showed benign vascular malformation, simple or combined, according to ISSVA (International Society for the Study of Vascular Anomalies) classification (27), with progressive osteolysis, cortical resorption, and activation of osteoclasts.

Most patients showed multiple areas of bone osteolysis: only one had a monostotic lesion (patient #9). Two patients suffered from a massive destruction with disappearance of the affected bone (patient #2 and #4).

Osteolytic lesions were more evident at CT while MRI disclosed infiltrative soft-tissue changes surrounding bony lesions and abnormal lymphovascular proliferation.

Lymphoscintigraphy was performed in 6 out of 9 patients. All patients displayed some lymphatic anomalies in the affected bone district. In the two patients with previous chylothorax, lymphoscintigraphy revealed residual pleural effusion. Late scintigraphic images (at 24 hours) showed presence of tracer accumulation in the abdomen in 5/6 patients, corresponding to intestinal loops by fusion imaging evaluation.

Bone scan was performed in 7/9 patients, showing no abnormal findings in 3/7 children and a decreased uptake in the affected bones in 4/7 children. Follow-up bone scans demonstrated a complete metabolic response after treatment at sites of increased uptake and a stable disease in the lytic lesion sites.

Seven patients received medical treatment: four with sirolimus and zoledronic acid; two with interferon plus bisphosphonates, and one with bisphosphonates alone because admission was prior to adoption of our internal protocol. Additional therapy was refused by parents of patient #4, who had received previous treatment at another hospital.

Patients #8 and #9 did not receive any treatment (one patient for stable disease over three years and the other because of a recent single lesion diagnosed in a newborn baby). Starting in 2016, a standardized schedule with sirolimus and zoledronic acid was administered to all eligible patients.

Therapy was generally well tolerated, and no severe adverse events were noted. Only patient #7 presented flu-like symptoms 24 hours following the zoledronic acid infusion. No cases of hypocalcemia or hypophosphatemia were registered. In patient #6, we observed mild hyperlipidemia, which rapidly normalized after low fat diet. Patient #1 suffered from transient leukopenia and lymphocytopenia secondary to sirolimus treatment.

Detailed Patient Data

Patient #1: 25 year-old young woman with onset of disease at the age of 3 years, presenting with left inguinal pain and swelling. A diagnosis of mixed venous-lymphatic malformation of the left lumbosacral region was established elsewhere. During the following years, course of the disease was mainly characterized by intermittent painful symptoms. Because of intractable pain, she was referred to our hospital and a clinical-radiological reassessment was performed. Imaging (CT, MRI) disclosed lumbosacral lymphatic malformation with secondary osteolysis (*Fig. 1*). Biopsy confirmed GSD diagnosis.

The patient was initially treated only with bisphosphonates (pamidronate) and subsequently, due to refractory disease, with combination therapy including sirolimus and zoledronic acid. Clinical response was very satisfactory with rapid regression of pain. Furthermore, whole body MRI, bone scan, and lymphoscintigraphy performed after 16 months of treatment demonstrated stable disease. Transient leukopenia with lymphocytopenia, most likely related to sirolimus treatment, was the only side effect of treatment observed.

Patient #2: 4 year-old boy who presented with a pathological fracture of the left femur at the age of 2 years. After 18 months he was

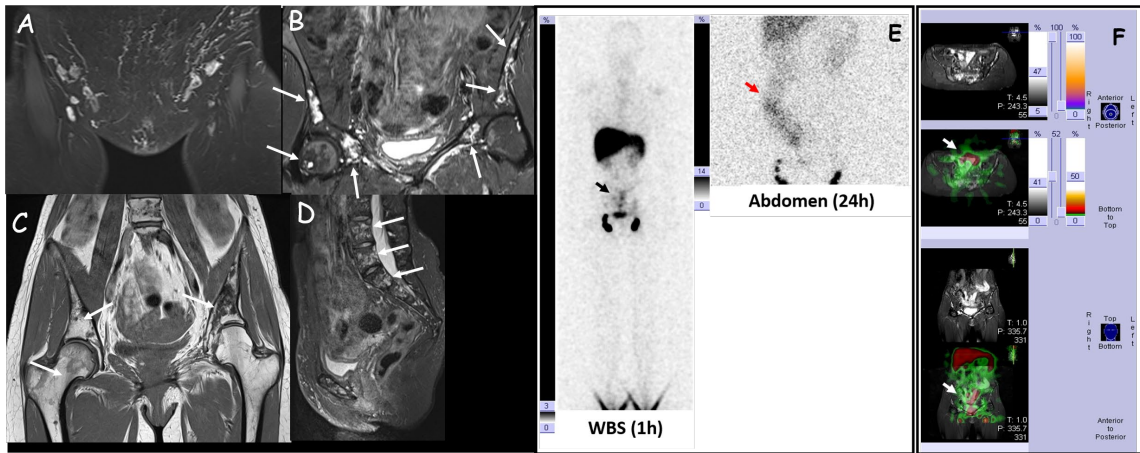


Fig. 1. Imaging characteristics of patient 1. A) Pelvic MRI with fluid-sensitive coronal scan (STIR) showing hypersignal streaks due to expansion of the lymphatic ducts of the abdominal wall with enlarged iliac and inguinal lymph nodes. B) MRI with fluid-sensitive coronal scan (STIR) of pelvic bones showing bilaterally multiple small areas of increased signal (fluid type) in the iliac wings, ileopubic branches and right femoral neck (arrows). C) T1 weighted MRI coronal scan of pelvic bones showing reduced signal areas in the right femoral neck and both iliac wings (arrows). D) Fluid-sensitive sagittal scan (STIR) on the lumbosacral tract showing multiple small hypersignal areas in the lumbosacral vertebral bodies. E) Left- Lower limb lymphoscintigraphy showing tracer accumulation in the pelvis (black arrow). Right- late 24-hour scintigraphic image demonstrates presence of tracer accumulation in abdomen (red arrow), corresponding to an intestinal loop (right colon). F) Hybrid imaging confirming lymphoscintigraphic planar findings.

admitted for local pain and gait disturbance. MRI and CT of the lower limbs documented extensive osteolysis with vanishing of the left femur, which appeared completely replaced by soft tissue (Fig. 2). Biopsy of affected bone demonstrated vascular proliferation associated with fibrosis of the intertrabecular spaces and osteoclastic resorption. GSD diagnosis was made and bisphosphonate therapy was started for a total of 6 courses (2 of neridronic acid and 4 of pamidronate). At the time of our observation, stable disease with no further skeletal involvement was observed.

Patient #3: 6 year-old boy who was admitted for extensive swelling of the axillary and left dorsal regions. Chest X-ray and CT showed a massive left-sided pleural effusion. Thoracentesis revealed milky white fluid consistent with chylothorax. CT scan, thoracic MRI, and bone scintigraphy documented osteo-structural alterations with multiple small bone gaps affecting multiple vertebral bodies (C4, C5, C6, C7, T1, T2), osteolytic al-

teration of left scapula, proximal metaphysis of left humerus and ribs. Soft tissue swelling of laterocervical, supraclavicular, axillary, and left arm region with linear hypodense images suggestive of lymphangectasis were also evident. Bone and soft tissue biopsies showed findings consistent with GSD. The patient was treated with sirolimus and intravenous zoledronic acid. Sirolimus was discontinued for 2 weeks due to a febrile pharyngotonsillitis. Relapse of the known laterodorsal swelling occurred during interruption with resolution upon resumption of therapy. No treatment-related side effects were recorded. Assessment after one year of treatment with zoledronic acid and sirolimus disclosed improvement of lymphatic dysplasia and stable bone disease.

Patient #4: 3 year-old boy who had been diagnosed at birth with cystic lymphangioma of head and neck associated with a capillary vascular malformation. CT scan and brain MRI after 2 years revealed bone resorption of the skull base (Fig. 3). Bone biopsy confirmed

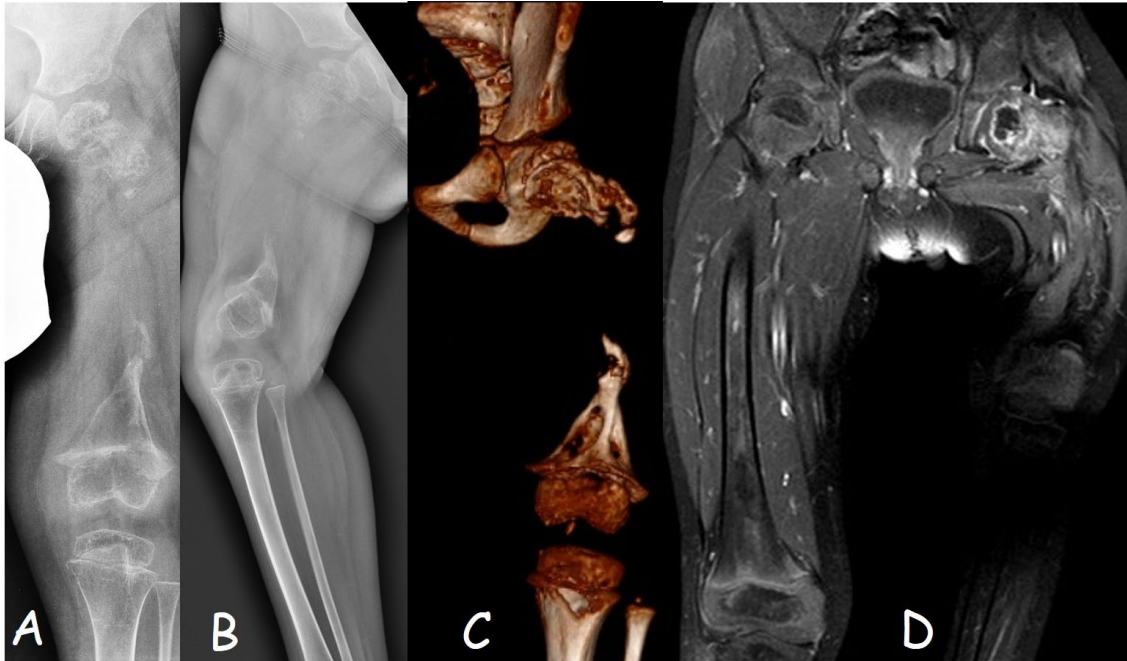


Fig. 2. Imaging characteristics of patient 2. A-B) A-P (A) and LL (B) radiography of the left femur showing complete bone osteolysis of femoral shaft with shortening and “vanishing bone” aspect. Any osteosclerotic or osteoblastic bone reaction is typically absent. C) 3D-CT confirms complete destruction of the bone without any osteoblastic reaction. D) MRI with fluid-sensitive coronal sequence (STIR) showing bone destruction with marked shortening.

a GSD diagnosis (proliferation of vascular channels associated with fibrosis and osteoclastic resorption). He had initially been treated elsewhere with 5 intravenous zoledronic acid courses, subcutaneous pegylated interferon-alfa-2b and steroids, which he received for 12 months without further skeletal changes. However, instability of the cranio-cervical hinge with rotation of nervous structures was noted, which prompted adoption of a cervical collar. After referral to our hospital, he suffered from 2 episodes of bacterial meningitis (*Streptococcus pneumoniae*) at the age of 3 and 4 years. Severe bilateral sensorineural hearing loss occurred as a complication. Brain CT and bone scintigraphy showed stable disease. No additional treatment was administered due to parents' refusal.

Patient #5: 13 year-old boy with a history of congenital angiomatous lesion in the left

upper limb for which he had not received any treatment. He presented after a fall with persistent back pain. Skeletal X-ray and CT scan disclosed extensive osteolysis of several vertebral bodies (C5, T5, T6, T8, T9, L3, L4), sacrum, left ileum, left supra-acetabular region, left humerus, and the right fifth rib. Furthermore, skull X-ray documented multiple osteolytic lesions throughout the left frontal and right temporal regions. Bone scintigraphy and MRI confirmed the involvement of these skeletal segments. Involved vertebral body needle biopsy proved inconclusive but ileal trephine biopsy disclosed changes consistent with GSD.

He was treated with weekly subcutaneous pegylated interferon-alfa-2b injections and quarterly intravenous pamidronate infusions for 12 months without any further skeletal changes or symptoms.

Patient #6: 4 month-old boy who was ad-

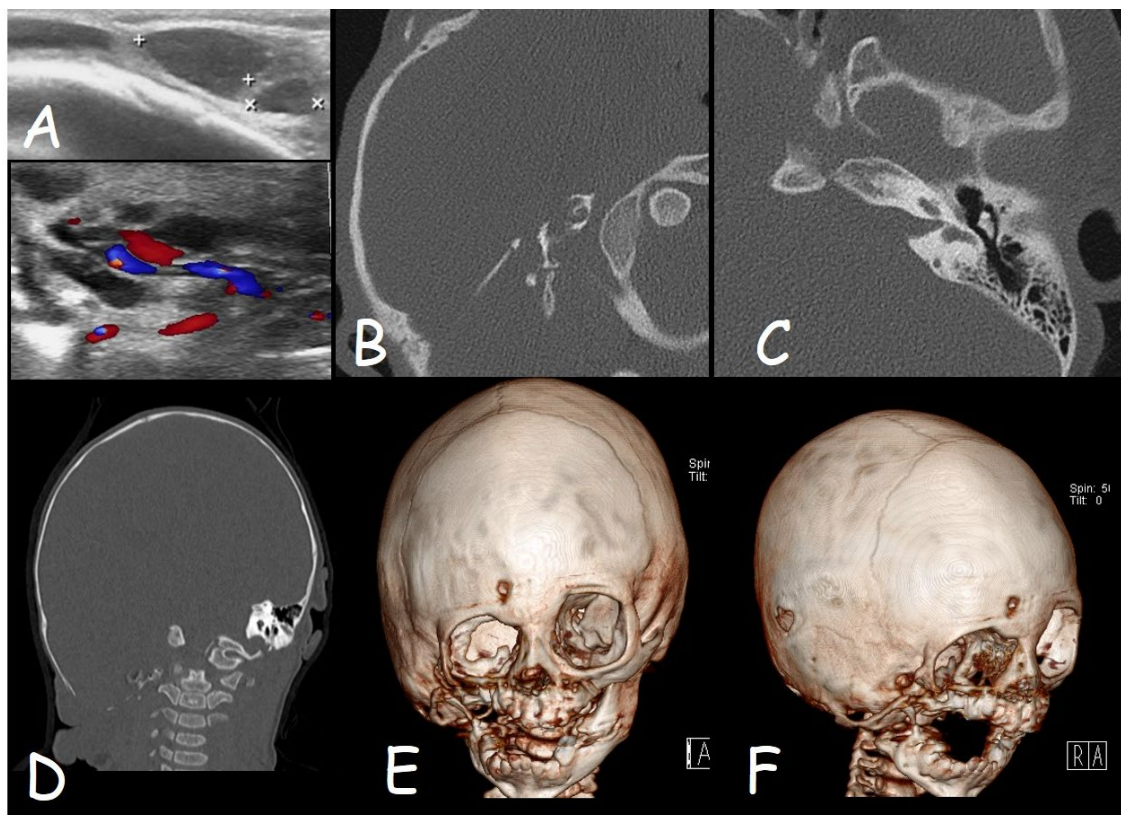


Fig 3. Imaging characteristics of patient 4. A) Ultrasound and echo-color doppler (ECD) scan of the right temporal and latero-cervical region. Presence of some transonic (fluid) areas and multiple vascular signals interposed between them by ECD. B-C) Axial CT of the right temporal area with disappearance due to erosion of all the structures of the ear which are instead clearly recognizable on the left side. D) CT with coronal reconstruction: downwards right bone expansion of the squamous part of the temporal bone with absence of the structures of the right temporal pyramid. E-F) CT with 3D bone reconstruction. Marked cranial asymmetry with lowering of the right orbit and the right temporal region. Reabsorption of part of the vertical branch of the right jaw with absence of the right mandibular condyle.

mitted for dyspnea and acute respiratory failure. The thoracic X-ray revealed massive right-sided pleural effusion. Therapeutic thoracentesis revealed a milky white fluid whose composition was consistent with chylothorax. CT scan documented osteolytic lesions of several vertebral bodies (L4, L5, S1), right scapula, proximal metaphysis of the left humerus and femur, ilium and sacrum, and surrounding lymphatic malformation (*Fig. 4*). Bone biopsy showed findings compatible with GSD (vascular proliferation associated with osteoclastic resorption). The patient was treated with sirolimus and intravenous zoledronic

acid. A mild hyperlipidemia, rapidly normalizing after a low-fat diet, was observed at the beginning of sirolimus treatment. Clinical-radiological reassessment showed no disease progression after one year of treatment.

Patients #7: 6 year-old boy, who had been diagnosed prenatally with a latero-cervical lymphangioma which underwent spontaneous regression in the first year of life. Subsequently, the patient developed 4 episodes of meningitis at age 4, 5 and 6 years, complicated by unilateral deafness. At this time, he was referred to our hospital for a new episode of

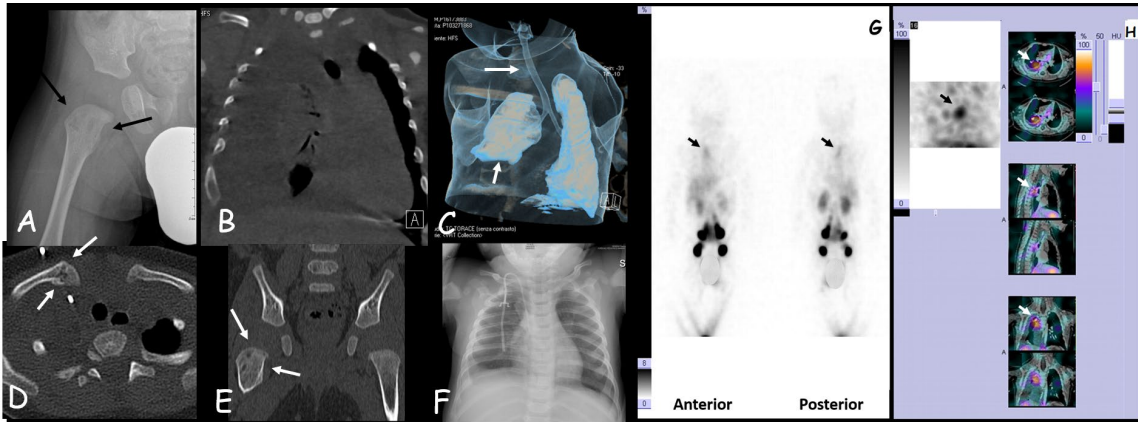


Fig. 4. Imaging characteristics of patient 6. A) A-P radiography of the right femur showing small areas of osteolysis (arrows). B) CT with coronal reconstruction of the chest showing massive right chylothorax with dislocation of the mediastinal structures. C) 3D CT with airway algorithm showing collapse of the right lung (arrow) and dislocation of the trachea (arrow). D) Axial CT scan showing areas of osteolysis of the right clavicle (arrows). E) Coronal CT of the pelvis showing small areas of osteolysis involving iliac wings and right femoral neck (arrows). F) Chest X-ray after draining the right chylothorax showing re-expansion of the right lung. G) Lymphoscintigraphy showed tracer accumulation in the right hemithorax/paramedian site (black arrow), which was the site of previous chylothorax. H) Hybrid imaging improving interpretation of lymphoscintigraphic planar finding in patients with thorax tracer accumulation (white arrow).

streptococcal meningitis only 3 months after the previous one. CT scan and MRI disclosed a bone resorption of the skull involving the petrous, occipital, and sphenoid bones. A cystic mass localized at the right temporal bone was evident at MRI. Biopsy confirmed the diagnosis of GSD. Combined therapy with sirolimus and intravenous zoledronic acid was recently started and is ongoing; and he has not suffered new infectious episodes since then. Flu-like symptoms within 24 hours following the zoledronic acid infusion were observed as the only side effect.

Patient #8: 14 year-old boy, who had been diagnosed prenatally (35th week of gestational age) with a parotid lymphangioma. During the first 4 years of life, he experienced a progressive reduction of superficial swelling, but deepening of lesion to the sphenoid bone. He suffered 3 episodes of bacterial meningitis and underwent surgical treatment for meningocele at 5 years of age. A GSD diagnosis was established when he was 14 years old. After referral, no further treatment was given as he showed stable disease, which has remained

unchanged during three years of follow-up MRIs.

Patient #9: 2-week-old girl, presented at birth with a swelling of the left mandible. CT scan revealed bone resorption involving the mandible associated to a vascular malformation partially occupying the oral cavity. Whole body MRI did not show any other osteolytic lesions. Histological examination confirmed GSD (Fig. 5). The patient did not experience functional limitations nor feeding difficulties nor pain. Due to stable disease and absence of infectious complications, no treatment was administered.

DISCUSSION

GSD is a rare and enigmatic disease. Since its first description, it remains poorly understood and largely underdiagnosed. Most of the GSD studies are case reports or retrospective or multicenter reviews. Our relatively large series might contribute to a better understanding of GSD.

Imaging studies (plain radiographs, bone

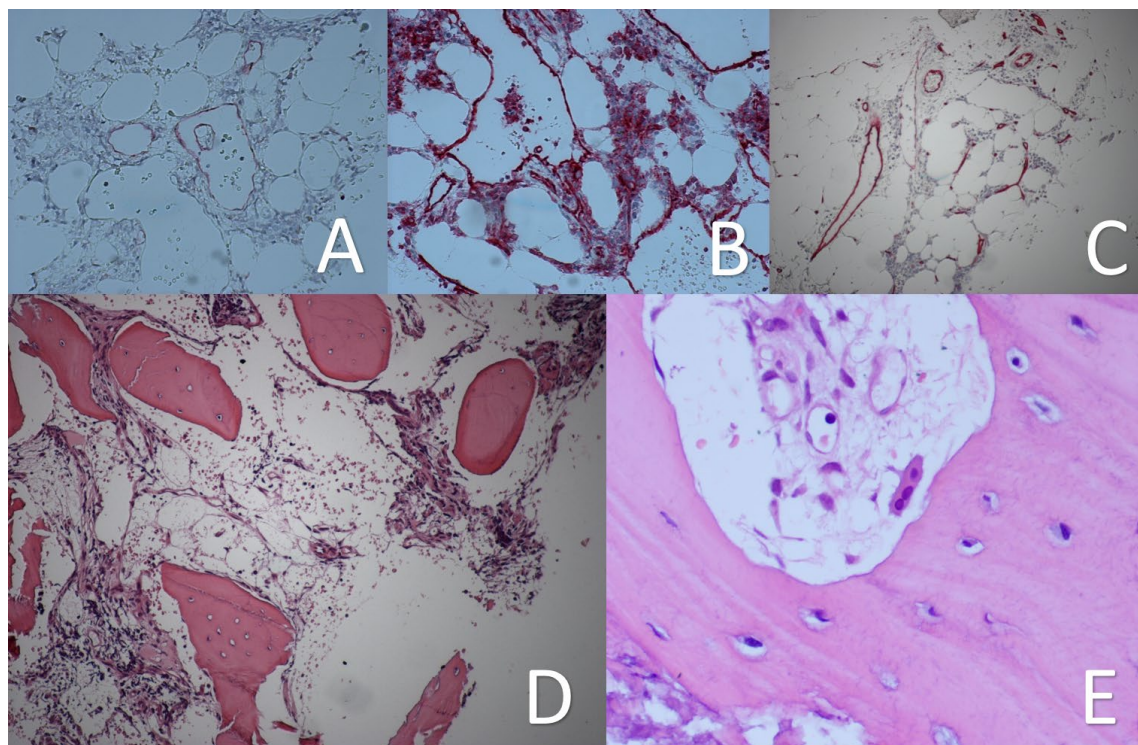


Fig. 5. Histological characteristics of patient 9. A) Trabecular bone resorbed by increased number of osteoclasts and irregularly dilated vascular channel in fibrous stroma (H&E, original magnification 20x). B) Vascular channel immunohistochemically staining positive for CD 31 (original magnification 20x). C) Vascular channel partially positive for CD34 (original magnification 20x). D) Vascular channel partially positive for D2-40 (original magnification 20x). E) Osteoclasts and irregularly dilated vascular channels in fibrous stroma (H&E, original magnification 40x).

scan, lymphoscintigraphy, computed tomography and magnetic resonance) played a significant diagnostic role. Bone X-rays initially show radiolucent foci in the intramedullary or subcortical regions and later on, cortical loss, lytic lesions, and slowly progressive resorption, fracture, fragmentation, and bone disappearance, with targeting or "pointing" of the remaining osseous tissue and atrophy of soft tissues. Bone scan can integrate radiological imaging by adding osteometabolic data. Park et al (28) described different scintigraphic patterns at diagnosis and during follow-up, suggesting that bone scan could be useful to evaluate disease activity and treatment response.

Lymphoscintigraphy should be considered as a valuable imaging modality to investigate patients with GSD, allowing a whole-body

lymphatic mapping.

CT findings are useful to assess the extent of bone destruction, while MRI (T2-weighted) reveals the extent of abnormal lympho-vascular proliferation.

According to previous reports (13,14,16, 28), our series confirms that disease localizations include different bone sites, which in turn are reflected in a variety of signs and symptoms. The relevance of localization in term of complication risk is well supported in our series.

All the patients with skull-base lesions (patients #4, #7, and #8) experienced meningitis, one of the life-threatening complications of GSD. In isolated mandibular localization, no meningitis occurred, as reported in a previous study (29). It may be argued that the interrup-

tion of the blood-brain barrier, secondary to the osteolytic lesion, facilitates the meningeal infection by microbial agents colonizing the upper airway.

Interestingly, two patients (#7 and #8) had prenatal evidence of lymphangioma in the parotid/cervical region, which is in line with the natural history of the disease, which generally increases during infancy.

Patients #3 and #6 presented chylothorax as the first sign of GSD. This is another important red flag to keep in mind because of the risk of sudden respiratory compromise. Chylous effusion may occur due to mediastinal extension from contiguous vertebra, scapula, rib, or sternum, and can be life threatening.

Moreover, after chylous effusion has resolved, it is mandatory to search for osteolytic lesions explaining the etiology and suggesting a GSD diagnosis. Indeed, diagnostic criteria mandate biopsy in addition to imaging and careful exclusion of confounding similar pathological conditions.

Histologically, it is possible to identify different stages of the disease: florid vascular malformation with an increased number of osteoclasts and resorbed bone are evident in the active phase, while fibroconnective tissue replaces vascular tissue in the inactive phase. Vascular lesions according to ISSVA 2018 are classified as simple or combined and identified immunohistochemically by D2-40, CD31, CD34, smooth muscle actin, and WTI staining (Fig. 5).

The mechanism of bone destruction and resorption is still unknown, and there is controversy regarding the presence or absence of osteoclasts (30,31). Based on these observations, recently our research team demonstrated in an experimental setting that osteoclast differentiation and activity is increased in cultures of cells isolated from our patients. Moreover, GSD osteoblasts differentiated from mesenchymal stem cells showed reduced ability to mineralize bone. These autonomous cell defects can be exacerbated by systemic factors contributing to the impairment of bone remodeling (8).

The development of next-generation sequencing has identified somatic mutations in

sporadic lesions of vascular anomalies (32). There are over 40 genes that are associated with vascular anomalies. Although no clear evidence exists about the causative mutation related to GSD, some observations in lymphatic research have identified several lymphangiogenic pathways that may play a relevant role, including the PIK3/AKT/mTOR pathway (33,34) and there is a single case for a *KRAS* mutation in one patient with GSD (10).

The appropriate treatment remains unsettled. A medical approach, surgery, and radiotherapy are treatment modalities that have been attempted in isolated cases, with differing degrees of success (35). Surgical strategies are definitely indicated in cases of pathological fracture (36). Radiotherapy with moderate doses was attempted in several adult patients described in the literature, yet its role remains controversial and should be avoided in pediatric patients due to the long-term sequelae such as radiation-induced malignancy and inhibition of skeletal growth.

Several medical treatments have been so far attempted, varying from anti-VEGF-A antibodies to interferon alpha-2b, bevacizumab, sirolimus, propranolol, steroids, vitamin D, calcitonin and bisphosphonates (BP) (18-26, 34,37).

Although so far no standardized treatment is available for GSD, in recent studies (33,34) the role of mTOR inhibitors seems to play a crucial role and this observation suggests the involvement of PIK3/AKT/mTOR pathway in the etiology of the disease.

Sirolimus is known to inhibit lymphangiogenesis and is thought to act on lymphatic tissues within lesions to regulate the production and leakage of lymph by decreasing lymphatic endothelial cell activity. Accordingly, bisphosphonates have been shown to display anti-angiogenic properties and seem able to induce apoptosis of proliferating cells while exerting a sustained analgesic effect (38).

Since these treatments may have additive effects, sirolimus in combination with zoledronic acid was used in our patients with the aim of slowing down and stabilizing disease progression.

Sirolimus was given initially at the dose

of 0.05 mg/kg twice daily orally and then adjusted to achieve serum levels between 5 and 15 ng/ml. Serum levels were checked at least monthly. Zoledronic acid was administered intravenously (0.1 mg/kg/dose, 0.015 mg/kg if age < 1year) every 3 months. (39-41). The scheduled treatment administered to our patients was well tolerated and no cases of disease progression were recorded, yet its actual efficacy still needs further confirmation.

CONCLUSIONS

In our clinical series, delay in diagnosis after first symptoms played a crucial role in determining the rate of morbidity. This temporal gap has been reduced in our most recent patients, demonstrating that more health care providers have been acquainted with the disease. This demonstrates that any effort in arousing specific clinical interest for a given rare condition may actively promote awareness of the disease in the greater medical community. In our opinion, multidisciplinary care is a key resource for the proper diagnosis and treatment of patients with GSD.

ACKNOWLEDGMENT

Authors Ippolita Rana, MD and Paola Sabrina Buonuomo, MD equally contributed to the work.

We thank and acknowledge the assistance of Adriana Mandarino and Alessandra Serpi for help in collecting patient's data.

Authors' roles. Ippolita Rana and Paola Sabrina Buonuomo: Conceptualization, Methodology, Writing- Original draft preparation; Gerarda Mastrogiorgio, Andrea Del Fattore, Alessandro Jenkner: Methodology, Writing- Original draft preparation; Domenico Barbuti, Rita De Vito, Milena Pizzoferro: Data curation, Writing- Reviewing and Editing; Michele Callea, Osvaldo Mazza, Marco Crostelli, Roberta Rotunno, Alessandro Inserra: Investigation, Writing- Reviewing and Editing; Andrea Bartuli: Supervision.

Each author listed on the manuscript has

seen and approved the submission of this version of the manuscript and takes full responsibility for the manuscript.

CONFLICT OF INTEREST AND DISCLOSURE

The authors declare no competing financial interests exist. No specific funding was received from any bodies in the public, commercial, or not-for-profit sectors to carry out the work described in this article.

REFERENCES

1. Gorham, LW, AW Wright, HH Shultz, FC Maxon, Jr: Disappearing bones: A rare form of massive osteolysis: Report of two cases, one with autopsy findings. *Am. J. Med.* 17 (1954), 674-682.
2. Gorham, LW, AP Stout: Massive osteolysis (acute spontaneous absorption of bone, phantom bone, disappearing bone): Its relation to hemangiomas. *J. Bone Joint Surg. [Am.]* 37-A (1955), 985-1004.
3. Bruch-Gerharz, D, CD Gerharz, H Stege, et al: Cutaneous lymphatic malformations in disappearing bone (Gorham-Stout) disease: A novel clue to the pathogenesis of a rare syndrome. *J. Am. Acad. Dermatol.* 56 (2007), S21-25.
4. Hammer, F, W Kenn, U Wesselmann, et al: Gorham-Stout disease-stabilization during bisphosphonate treatment. *J. Bone Miner Res.* 20 (2005), 350-353.
5. Hagendoorn, J, TP Padera, TI Yock, et al: Platelet-derived growth factor receptor-beta in Gorham's disease. *Nat. Clin. Pract. Oncol.* 3 (2006), 693-697.
6. Radhakrishnan, K, SG Rockson: Gorham's disease: An osseous disease of lymphangiogenesis? *Ann. NY Acad. Sci.* 1131 (2008), 203-205.
7. Hagendoorn, J, IH Yocke, T Padera, et al: Novel molecular pathways in gorham disease: Implications for treatment. *Pediatr. Blood Cancer* 61 (2014), 401-406.
8. Rossi, M, PS Buonuomo, G Battafarano, et al: Dissecting the mechanisms of bone loss in Gorham-Stout disease. *Bone* 130 (2020), 115068
9. Iacobas, I, L Klepper, J Kelly, et al: Meeting Report for the 2016 Conference on GLA and

- Gorham-Stout Disease. *IBMS BoneKEy* 13 (2016), 847.
10. Nozawa, A, M Ozeki, T Niihori, et al: A somatic activating KRAS variant identified in an affected lesion of a patient with Gorham-Stout disease. *J. Hum. Genet.* 65 (2020), 995-1001. doi: 10.1038/s10038-020-0794-y.
 11. Dellinger, MT, N Garg, BR Olsen: Viewpoints on vessels and vanishing bones in Gorham-Stout disease. *Bone* 63 (2014), 47-52.
 12. Patel, DV: Gorham's disease or massive osteolysis. *Clin. Med. Res.* 3 (2005), 65-74.
 13. Hu, P, XG Yuan, XY Hu, et al: Gorham-Stout syndrome in mainland China: A case series of 67 patients and review of the literature. *J. Zhejiang Univ. Sci. B* 14 (2013), 729-735.
 14. Ruggieri, P, M Montalti, A Angelini, et al: Gorham-Stout disease: The experience of the Rizzoli Institute and review of the literature. *Skeletal Radiol.* 40 (2011), 1391-1397.
 15. Fujiu, K, R Kanno, H Suzuki, et al: Chylothorax associated with massive osteolysis (Gorham's syndrome). *Ann. Thorac. Surg.* 73 (2002), 1956-1957.
 16. Nikolaou, VS, D Chytas, D Korres, N Efstathiopoulos: Vanishing bone disease (Gorham-Stout syndrome): A review of a rare entity. *World J. Orthop.* 5 (2014), 694-698.
 17. Heffez, L, HC Doku, BL Carter, JE Feeny: Perspectives on massive osteolysis: Report of a case and review of the literature. *Oral Surg. Oral Med. Oral Pathol.* 55 (1983), 331- 343.
 18. Duffy, BM, R Manon, RR Patel, et al: A case of Gorham's disease with chylothorax treated curatively with radiation therapy. *Clin. Med. Res.* 3 (2005), 83-86.
 19. Dunbar, SF, A Rosenberg, H Mankin, et al: Gorham's massive osteolysis: The role of radiation therapy and a review of the literature. *Int J. Radiat. Oncol. Biol. Phys.* 26 (1993), 491-497.
 20. Heyd, R, O Micke, C Surholt, et al: Radiation therapy for Gorham-Stout syndrome: Results of a national patterns-of-care study and literature review. *Int. J. Radiat. Oncol. Biol. Phys.* 81 (2011), e179-185
 21. Grunewald, TG, L Damke, M Maschan, et al: First report of effective and feasible treatment of multifocal lymphangiomatosis (Gorham-Stout) with bevacizumab in a child. *Ann. Oncol.* 21 (2010), 1733-1734.
 22. Mignogna, MD, S Fedele, L Lo Russo, R Ciccarelli: Treatment of Gorham's disease with zoledronic acid. *Oral Oncol.* 41 (2005), 747-750.
 23. Nir, V, L Guralnik, G Livnat, et al: Propranolol as a treatment option in Gorham-Stout syndrome: A case report. *Pediatr. Pulmonol.* 49 (2014), 417-419.
 24. Hagberg, H, K Lamberg, G Astrom: Alpha-2b interferon and oral clodronate for Gorham's disease. *Lancet* 350 (1997), 1822-1823.
 25. Elera-Fitzcarrald, C, MF Ugarte-Gil: Gorham-stout syndrome: A phantom bone disease treated with bisphosphonates. *J. Clin. Rheumatol.* 26 (2020), e135-e136.
 26. Liu, Y, DR Zhong, PR Zhou, et al: Gorham-Stout disease: Radiological, histological, and clinical features of 12 cases and review of literature. *Clin. Rheumatol.* 35 (2016), 813-823.
 27. Sadick, M, R Müller-Wille, M Wildgruber, WA Wohlgemuth: Vascular anomalies (Part I): Classification and diagnostics of vascular anomalies. *Rofo.* 190 (2018), 825-835.
 28. Park, SB, JY Choi, SJ Kim: Gorham-Stout disease affecting the mandible: Bone scintigraphy and computed tomography findings. *Clin. Nucl. Med.* 42 (2017), 779-781.
 29. Simon, F, R Luscan, RH Khonsari, et al: Management of Gorham stout disease with skull-base defects: Case series of six children and literature review. *Int. J. Pediatr. Otorhinolaryngol.* 124 (2019), 152-156.
 30. Sage, MR, PWL Allen: Massive osteolysis: Report of a case. *J. Bone Joint Surg. [Br]* 56 (1974), 130-135.
 31. Dickson, GR, RAB Mollan, KE Carr: Cytochemical localization of alkaline and acid phosphatase in human vanishing bone disease. *Histochemistry* 87 (1987), 569-572.
 32. Brouillard, P, L Boon, M Vikkula: Genetics of lymphatic anomalies. *J. Clin. Invest.* 124 (2014), 898-904.
 33. Hagendoorn J, TI Yock, IH Borel Rinkes, et al: Novel molecular pathways in Gorham disease: Implications for treatment. *Pediatr. Blood Cancer* 61 (2014), 401-406.
 34. Cramer, SL, S Wei, AC Merrow, JG Pressey: Gorham-Stout disease successfully treated with sirolimus and zoledronic acid therapy. *J. Pediatr. Hematol. Oncol.* 38 (2016), e129-132.
 35. Li, MH, HQ Zhang, YJ Lu, et al: Successful management of Gorham-Stout Disease in scapula and ribs: A case report and literature review. *Orthop. Surg.* 10 (2018), 276-280.
 36. Chong Ng, L, P Sell: Gorham disease of the cervical spine-a case report and review of the

- literature. *Spine* 28 (2003), E355-E358.
37. Koto, K, K Inui, M Itoi, K Itoh: Gorham-Stout disease in the rib and thoracic spine with spinal injury treated with radiotherapy, zoledronic acid, vitamin D, and propranolol: A case report and literature review. *Mol. Clin. Oncol.* 11 (2019), 551-556.
 38. Sun, S, X Liu, B Ma, et al: Could local delivery of bisphosphonates be a new therapeutic choice for Gorham-Stout syndrome? *Med. Hypotheses* 76 (2011), 237-238.
 39. Baroncelli, GI, S Bertelloni: The use of bisphosphonates in Pediatrics. *Horm. Res. Paediatr.* 82 (2014), 290-302.
 40. Simm, PJ, A Biggin: Consensus guidelines on the use of bisphosphonates therapy in children and adolescents. *J. Paed. Child. H.* 54 (2018), 223-233.
 41. Schneider, KN, M Masthoff, G Gosheger, et al: Gorham-Stout disease: Good results of bisphosphonate treatment in 6 of 7 patients. *Acta Orthop.* 91 (2020), 209-214.

Paola Sabrina Buonomo, MD
Rare Diseases and Medical Genetics,
Bambino Gesù Children's Hospital, IRCCS
Rome, Italy
Phone: +39 06 68593642
E-mail: psabrina.buonomo@opbg.net