

## A NEW COMBINED OPERATIVE TECHNIQUE USING CROSSED INGUINAL LYMPHATIC RESCUE FOR PEDIATRIC PATIENTS WITH MIXED LYMPHATIC AND VENOUS MALFORMATIONS

C.M. Papendieck, L. Barbosa, M. Amore, R. Martínez Allende,  
G. Mogollon, S. Gómez Rueda, M. Gómez

Grupo Angiopediatria, Buenos Aires. Grupo Fronteras de la Linfología.(CMP, MG, MA, RMA) Hospital de Niños R. Gutiérrez, Buenos Aires (LB, MG); Hospital Militar Central, Cirugía Vascular, Buenos Aires (MA); Hospital del Quemado, Buenos Aires, Argentina (RMA); and Hospital Roosevelt de Ortopedia Infantil (GM, SGR), Bogotá, Colombia

### ABSTRACT

*Truncular venous malformations and acquired functional or anatomical venous occlusions (or sub-occlusions) can be the cause of secondary lymphedema and even the cause of primary lymphedema when they are associated with lymphatic malformations (lymphangiodyplasia – LAD I, lymphadenodyplasia – LAD II, or a combination of both) in pediatric patients. This understanding recognizes the shared and successive embryogenesis of both systems. These conditions can exhibit hypertension in the venous pedicles intended for lymph-venous anastomosis, and this finding would be a formal contraindication to the procedure. However, this hypertension is a rarely considered condition and is not commonly identified. As a technique to solve this problem, we have combined Nielubowicz, Olszewski, Campisi, and Palma's proposals and created a lymph-venous anastomosis from the side with lymphedema and venous hypertension (lymphatic donor and venous recipient) with an internal suprapubic saphenous venous bridge (from the normal side to the lymphedematous side with venous hypertension) to enable a crossed inguinal lymphatic/venous rescue. We believe this newly synthesized approach will allow*

*better clinical care of pediatric patients with complex and combined lymphatic-venous malformations and is worthy of further investigation.*

**Keywords:** primary lymphedema, secondary lymphedema, pediatrics, venous hypertension, lymphatic venous anastomosis, overgrowth syndrome, vascular malformation, lipomatous overgrowth

The lymphatic and venous systems develop in parallel with average lymphatic pressure being slightly higher allowing transport into the venous system. Secondary lymphedema associated with lymphatic and/or venous malformations can affect this pressure differential, and these changes can also be seen in primary lymphedema due to lymphangiodyplasia and/or lymphadenodyplasia (LAD I-II). Primary lymphedemas not associated with lymphatic-venous malformations do not exhibit these changes. If the pressure differential is reversed for any reason, lymph nodes will encounter some difficulty in reabsorbing water, and transference to the blood system will be inhibited. In addition, if venous pressures are markedly higher than lymphatic, lymphatic-venous anastomosis would not make physiological sense.

Truncular venous hypertension is commonly found in many primary syndromes in pediatrics. It can also develop secondarily due to venous alterations from any cause, or as an iatrogenic disorder. Primary syndromes with high venous pressure are usually the consequence of truncular venous malformations. It must be recognized that given the shared and sequential or successive veno-lymphatic embryogenesis that simultaneous congenital malformations are commonly found, and they frequently result in a progressive lymphatic overload. These truncular venous malformations (1), or acquired functional or anatomical venous occlusions, can also be the cause of secondary lymphedema (2) or even primary lymphedema when associated with a variety of lymphatic malformations (lymphangio-dysplasia – LAD I, lymphadenodysplasia – LAD II, or a combination of both) (3) in pediatrics.

Surgical techniques attempting lympho-venous (LV) bypass need to take many factors into consideration: pressure gradient between both systems, vascular motricity, diameter of the possible anastomosis, technical exactness of anastomosis, volume or load circulating through both systems, etc. Selecting the lymphatic vessel or node to be used in the bypass (donor) identified by lymphochromy with patent blue dye is obviously fundamental. The vein should not have any reflux and be functioning at the lowest possible pressure (no venous backflow, normal valves). A lymph node receives 2-10 collecting lymphatic vessels as afferents and is capable of incorporating 5-20 cc/day of lymph through it. This volume can be reduced to 10% through the intranodal venous system reabsorbing water. Venous malformations with hypertension can disrupt these normal pressure gradients and the flow in the venous system. The exception to this physiology is lymph that flows from the cisterna chyli in which 100% moves forward through the thoracic duct.

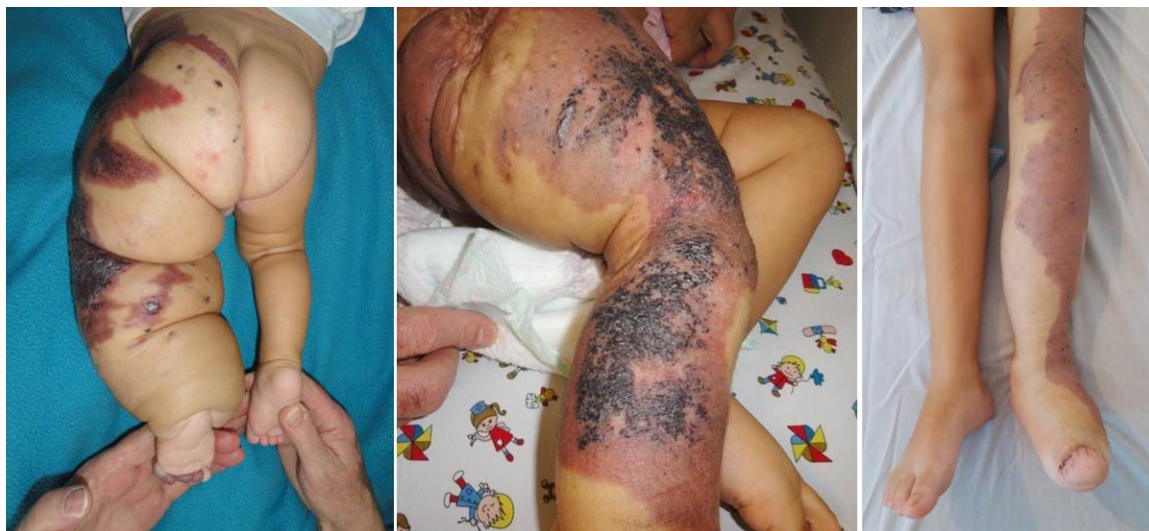In principle, and whenever possible, the venous defects in angiodyplastic syndromes

should be repaired first. However, it is not always feasible to do so adequately. Translocations, bypasses, opening of classical occlusive anatomical defects, prostheses, and stents are all possible alternatives. Unfortunately, some of these have limitations or are insufficient due to the age of the pediatric patient (e.g., the congenital occlusion of the external iliac vein).

In many of the various lymphatic and/or venous malformations, the veins on the same side of the lymph node to be bypassed all exhibit high pressure. This issue has been addressed by Palma using his receiving venous bridge with a contralateral saphena magna vein and venous-venous anastomosis to bypass and reduce the high pressure venous circuit.

The techniques we describe to address these issues in pediatrics involve incorporation of a crossed inguinal lymphatic/venous rescue. Occasionally we have combined Palma's original venous-venous idea and performed one or two lymph node-vein anastomoses on the same (lateral in this case) vein, in which case we have gone back to Nielubowicz- Olszewski's original design combined with the initially described Palma procedure (4-8).

The procedure was originally designed to address a thrombotic or post-thrombotic syndrome. Following this Palma venous bypass, we perform a lymphatic-venous anastomosis between a lymph node or a set of sentinel lymphatic vessels and the internal saphenous vein from the normal or donor side. The circuit has a positive lymphatic pressure and venous pressure equal to 0 (or without reflux) because the translocated vein is normal and, hence, valves are healthy. The Venturi effect at the confluence of the common or superficial femoral vein is normal. Obviously, this proposal is not viable in bilateral syndromes. As the caliber of the translocated internal saphenous vein is proportionally considerable, using it in hypertensive, non-venous primary or secondary lymphedemas is not generally indicated.



*Fig. 1. CLOVES Syndrome in a baby displaying lipomatous overgrowth, hypertrophy, vascular nevi, and vascular malformation without lymphedema (left). Klippel Trenaunay Syndrome in a young child demonstrating hypertrophy and vascular nevi (center). This patient was selected to undergo treatment using the proposed Palma-Olszewski technique. Klippel Trenaunay Syndrome in an older child three years post-operation using the Palma-Olszewski Technique (right).*

A complicating problem is fibrosis at the level of the anastomosis, which is a common issue with all techniques. As this technique is performed with a terminal vein that has a good caliber, the suture involves the area around the lymph node and the entire venous wall to ensure closure as well as to inhibit the development of fibrosis. In addition, because thrombosis is possible at a lympho-venous or nodal-venous anastomosis, local endovenous heparin is mandatory to inhibit clot formation.

#### *PATIENTS AND EVALUATION*

Our clinic is a center (Grupo Angio-pediatria) for pediatric patients (1-15 years of age) in Buenos Aires. The majority of patients exhibit signs of lymphatic dysplasia (with or without reflux) or are patients affected with an overgrowth syndrome with venous or AV malformations. These patients present with known syndromes such as Klippel-Trenaunay, Parkes Weber, Servelle-Martorell (*Fig. 1*) (9,10), Proteus (11,12), CLOVES (13,14), Gorham-Stout (15,16) or

those with specific clinical features such as primary and/or secondary lymphedema [stage/grade II-III, with overgrowth because of LAD I and/or LAD II (lymphangiodyplasia, lymphadenodyplasia) (3)], lipomatous overgrowth with lymphatic dysplasia, lymphatic nodal hypoplasia and/or agenesis with truncular venous malformations, or chylous reflux. In all cases, the venous hypertension at the level of the future lympho-venous anastomosis is the reason to elect the proposed combined crossed technique.

There are a variety of specific pre-operative imaging evaluations which are indispensable for delineating these conditions: AV Echo Doppler of both lower limbs and pelvis, digital radiological measurement of lower limb bones and soft tissue, Magnetic Lympho(angio) Resonance without contrast media (*Fig. 2*), lymphochromy using vital blue dye (0.5%) with simultaneous endovenous rescue with ascorbic acid (*Fig. 2*), direct phlebography of both lower limbs and pelvis (*Fig. 2*), and lymphoscintigraphy

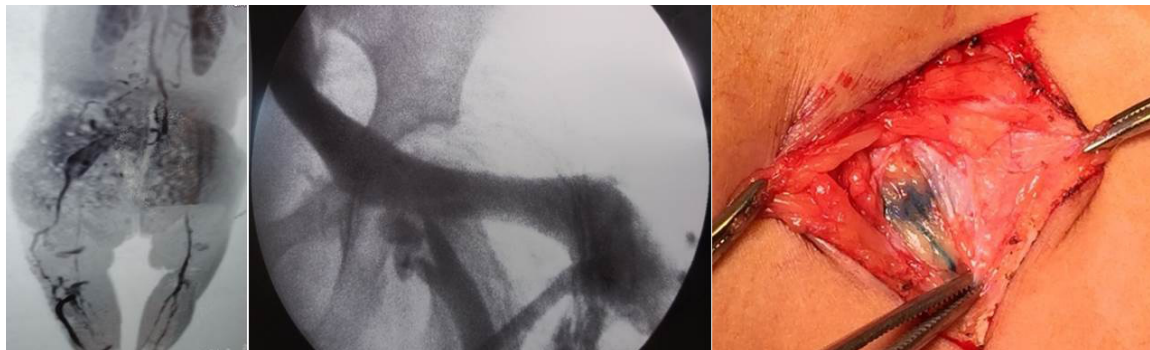

Fig. 2. Imaging options for patients include: (left) Angio Magnetic Resonance with contrast, as seen here in the venous sequence of a baby with Klippel Trenaunay Syndrome and Lipomatous Overgrowth demonstrating truncular and extratruncular venous-lymphatic malformation on the legs and pelvis; (center) Phlebography via the saphena externa on a lower limb demonstrating persistent vena marginalis, and hypoplasia of the superficial femoral vein with avaluatation in this patient with Klippel Trenaunay Syndrome; and (right) Lymphochromy in a lower limb following dissection to identify a sentinel lymph node and vessel as the first step for a lymphovenous shunt with the Palma-Olszewski alternative.

with  $^{99m}\text{Tc}$ , if necessary for a dynamic evaluation.

### SURGICAL TECHNIQUES

The Palma operation consists of the release of internal (magna) saphenous vein from proximal to distal, donor (healthy) side, distal section and its subcutaneous supra-pubic translocation (after perfusing with heparin), through a suprapubic subcutaneous way to the opposite inguinal region (receptor side) (Figs. 3,4). In addition, these two secondary procedures are utilized in a patient-specific manner:

- a. Modified Olszewski technique utilizes a sagittal biopsy of a lymph node without removing the efferent lymphatics. The lymph node is identified using blue dye as the sentinel node and a terminal venous anastomosis is made with the translocated free saphena magna using 3 to 5 stitches of 5/0 Monofilament (Fig. 4, right).
- b. C. Campisi alternative uses patent blue lymphochromy to identify and collect a group of lymphatic vessels

at the compromised inguinal level and then anastomose to the free, sectioned saphena magna vein with one 5/0 suture.

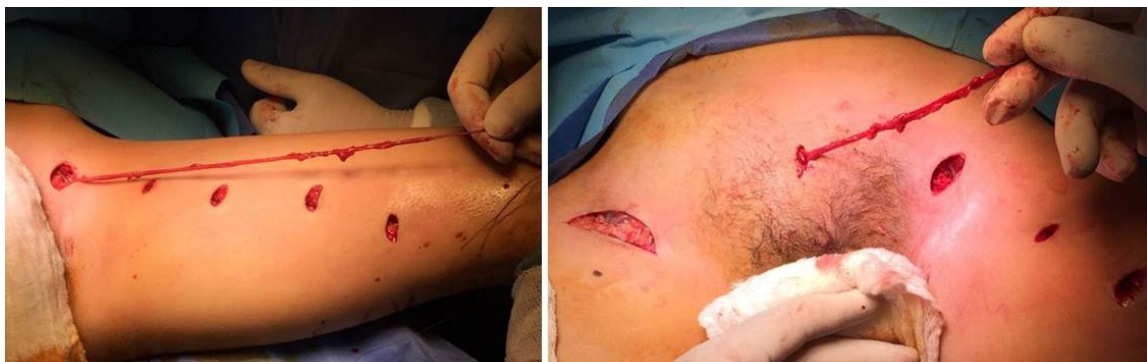If lymph nodes can be identified by imaging (Lymphatic Magnetic Resonance Imaging, blue dye, or ultrasound), we use alternative a. If nodes are not identified or the patient condition requires an amplified dissection, we use alternative b.

All procedures have the percutaneous accesses closed with acrylate and elastic bandages are applied as a dressing. To inhibit clotting, manual lymphatic drainage is applied in two 1-hour sessions per day starting on the first post-op day. Daily oral acetylsalicylic acid for the first 3 months is administered.

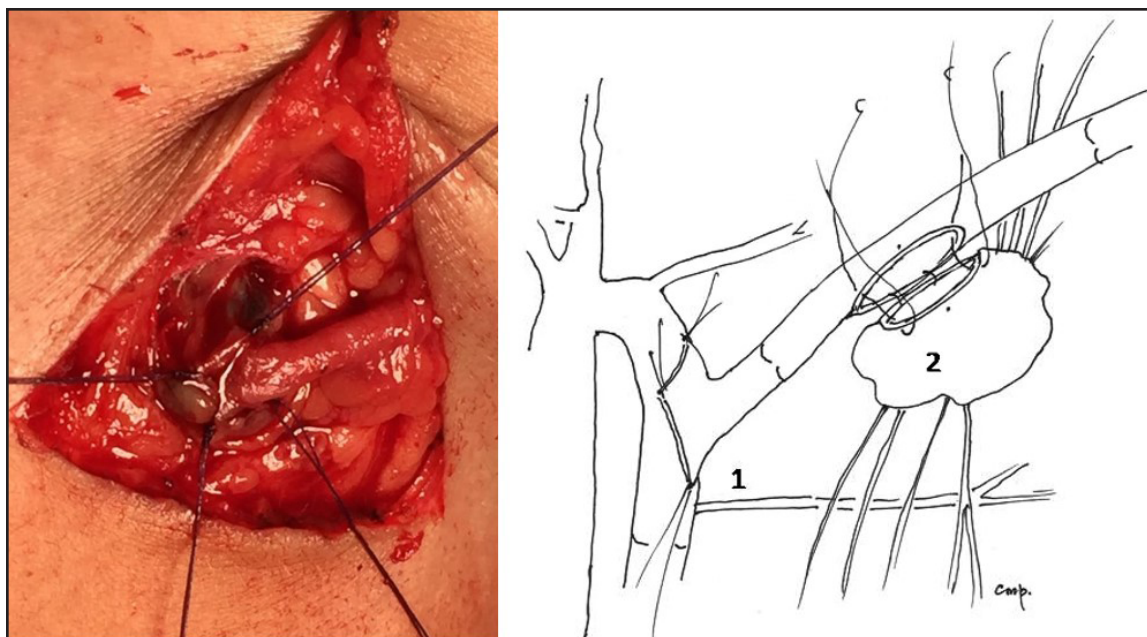
### RESULTS

Detailed analysis and long-term follow up of the operative results in children is complicated due to growth of the child, avoidance of unnecessary biopsies in infants and small children, difficulties in imaging, and in our case, the often long distance and expense of travel to the clinic for patients





*Fig. 3. The Palma technique includes the dissection and collection of a vena saphena magna in a 5-step procedure (left) and then the suprapubic, subcutaneous translocation of the vein connecting to the opposite side to reduce venous pressure (right).*



*Fig. 4. Terminal anastomosis of the translocated vena saphena magna with the lateral side of an inguinal lymph node (left) and schematic (right) of the Palma-Olszewski technique (modified) depicting the terminolateralvenovenous anastomosis (between the translocated vena saphena magna (terminal) with the homolateral vena saphena magna (lateral) (1) and a side to side lateral anastomosis between the translocated crossed vena saphena magna to a lymph node (shown without the efferent lymphatic vessels for clarity) on the compromised inguinal side with venous hypertension (2).*

from all over South America. In addition, these complex patients with multiple syndromes and presentations are each unique without enough similarities to compose even a small series. Our focus is primarily to ensure the survival of the patient and to offer

them the highest level of individualized function, form, and comfort. Considering those desired outcomes, we have accomplished the Palma technique in combination with either the modified Olszewski technique or the C. Campisi alternative as specifically

indicated in appropriate patients. These cases have included multiple children with Klippel Trenaunay, CLOVES, and chylous reflux syndromes as well as in one case with external lymphatic fistulae due to lymphatic malformation and one case as a result of trauma. These patients did not experience complications, and short-term followup shows no closures of the venous anastomosis (by ultrasound) or development of fibrosis. The techniques employed are a logical surgical alternative, and both combinations have been successfully performed technically. However, these novel techniques need further application in other specialized centers to generate small series for more extensive evaluation.

### CONCLUSION

In the entire context of the analysis of patients with lymphedema, assessment of venous and lymphatic pressures has not been adequately approached in pediatrics vis-a-vis the large number of surgical and therapeutic alternatives for lymphedema. These critical pressures bear directly on lymphatic-venous anastomosis, which can provide impressive results along with a variety of alternatives and opportunities. Pressure differences in a large number of syndromes and clinical presentations need to be fully recognized. Very likely, vascular dynamics – the relationship between the volume and the pressure of circulating fluids – in addition to density and the Venturi effect at the site of the lymphatic-venous anastomosis – are important factors influencing the transit of lymph into the venous system. Our new procedure utilizing the Palma operation and then combining it with other lymphatic-specific techniques addresses these differences in pressures and strives to approach the optimal treatment in these pediatric patients with lymphatic/venous malformations.

A great step forward in these procedures has been the advancement of specific arterial and venous sutures/techniques and heparinization for the patient. The next future goal

is the spontaneous or induced synthesis of lymphatic vascular continuity through a variety of developing ideas (growth factors, genetic manipulation, stem cells, etc.), which is a pathway that began more than 40 years ago.

In addition, we should recognize that there is a difference in rehabilitating a secondary lymphedema with a system that was previously normal compared to rehabilitating a congenital primary lymphedema in a system which was never successfully developed. Finally, since our developed protocols are patient-specific and so far not systematically applied, future research should test whether these techniques (with possible modifications) or others will be applicable to more pediatric and adult patients with these syndromes and clinical presentations.

### CONFLICT OF INTEREST AND DISCLOSURE

All authors declare that no competing financial interests exist.

### REFERENCES

1. Belov S, DA Loose, J Weber: Vascular malformations. *Periodica Angiologica* 16 (1989), 25-27.
2. Papendieck, CM: Linfedema en Pediatría. Clasificación y Etiopatogenia. *Rev Hosp Niños Buenos Aires* 45 (2005), 14-22.
3. Papendieck, CM: Lymphatic dysplasias in pediatrics. *Intern. Angiol.* 18 (1999), 5-9.
4. Nielubowicz, J, W Olszewski, J Sokolovsky: Lymphovenous anastomosis. *J. Cardiovasc. Surg.* (1968), Special issue 98-105.
5. Olszewski, W: Microsurgical lymphovenous anastomosis after 45 years follow up and indications. *EJLRP* 2012. 23(66) 36 XXXVIII ESL Congress Berlin, 2012.
6. Cheng M-H, DW Chang, KM Patel: *Principles and Practice of Lymphedema Surgery*. Elsevier, 1st Ed., 2016.
7. Campisi, C, C Bellini, C Campisi, et al. Microsurgery for lymphedema: Clinical research and long-term results. *Microsurgery* 30 (2010), 256-260.
8. Palma EC, R Esperon: Vein transplants and grafts in the surgical treatment of the

- postphlebotic syndrome. *J. Cardiovasc. Surg.* 1 (1960), 94-107.
9. Servelle, M: *Pathologie Vasculaire.* 2, Les affections Veineuses. Masson, Paris. 1978.
  10. Papendieck, CM, L Barbosa, P Pozo, et al: Klippel-Trenaunay-Servelle syndrome in pediatrics. *Lymphat. Res. Biol.* 1 (2003), 81-84.
  11. Wiedemann HR: The Proteus Syndrome. *Eur. J. Pediatr.* 149 (1983), 5-12.
  12. Papendieck CM: Pie de la sombra. Dialogo entre Historia, Arte y Enfermedad. *Rev. Hosp. Niños (B. Aires)* 56 (2014), 221-236.
  13. Alomari AI, PZ Burrows, EY Lee, et al: CLOVES Syndrome with thoracic and central phlebotasias. Increased risk of pulmonary embolism. *J. Thorac. Cardiovasc. Surg.* 140 (2010), 459-463.
  14. Alomari AI, R Thiek, JB Mulliken: Hermann Friedbergs case report: An early description of CLOVES syndrome. *Clin. Gen.* 78 (2010), 342-347.
  15. Gorham WI, PH Stout: Massive osteolysis (acute spontaneous absorption of bone, phantom bone, disappearing bone); its relation to hemangiomatosis. *J. Bone Joint Surg. Am.* 37A (1955), 985-1004.
  16. Papendieck, CM: Sindrome de Gorham Stout Haferkamp con reflujo de quilo. *Rev. Argent. Cirugia* 79 (2000), 7-10.

**Cristobal M. Papendieck, MD, FACS**  
**Pediatric Surgeon, Prof. Consulto Titular**  
**Universidad del Salvador (USAL)**  
**Buenos Aires, Argentine**  
**Email:**  
**[cmpapendieck@angiopediatria.com.ar](mailto:cmpapendieck@angiopediatria.com.ar)**