

Lymphographic Appearance of Nodal Extramedullary Hematopoiesis Simulating Lymphoma

J. J. Cunningham

Department of Radiology, Bowman Gray School of Medicine, Winston-Salem

Summary

A 63 year old man underwent lymphography because of anemia, splenomegaly, and fever. Nodes in the high para-aortic region had the appearance of involvement with malignant lymphoma. Subsequent biopsy showed that these changes were due to the partial replacement of nodal tissue with extramedullary hematopoiesis.

Patients who have constitutional symptoms, blood dyscrasias, and splenomegaly often are suspected of harboring occult malignancies and these individuals may undergo lymphography as part of their diagnostic evaluation. We recently examined the radiographs of such a patient and found changes quite consistent with malignant lymphoma in the opacified retroperitoneal nodes. Subsequently, these lymph nodes were biopsied and the alterations proved to be due to extramedullary hematopoiesis. We were unable to find any similar case recorded in the literature.

Case report

A 63 year old man complained of malaise, weakness, and anorexia for two months. Physical examination was unremarkable except for scattered ecchymoses over the lower legs, fever, and splenomegaly. There was no palpable adenopathy. An examination of the peripheral blood showed pancytopenia with a hemoglobin of 8.3 gms%, white blood cells totaling $3,300/\text{mm}^3$ (67% lymphocytes), and platelets reduced to $58,000/\text{mm}^3$. The reticulocyte count was 3.4%. Serum bilirubin was slightly elevated. A Coombs test was positive. Stool specimens were negative for blood.

Bone marrow preparations showed a marked generalized cellular hyperplasia. There was a slight granulocyte dysplasia and dyserythro-

poiesis. A simple hemolytic anemia was thought unlikely on the basis of the peripheral blood count and marrow analysis.

No mediastinal adenopathy was seen on chest radiographs. Radiologic examination of the gastrointestinal tract was normal except for diverticulosis. Lymphograms were made and these were abnormal (Fig. 1A, 1B). Nodes high in the paraaortic area showed a slight generalized increase in size. The nodal margins were ill defined and the nodal architecture was distorted by irregular filling defects of varying sizes and shapes. Nodes in the more distal retroperitoneal chains such as the common iliac groups were normal.

Exploratory laparotomy was performed by an experienced oncologic surgeon. He found and biopsied enlarged paraaortic nodes which had the gross appearance and palpable consistency expected with nodal involvement by malignant lymphoma. The spleen was enlarged and it was removed.

Microscopic examination of the liver revealed moderate fatty change with diffuse nodules of extramedullary hematopoiesis. Old and recent hemorrhages in addition to extramedullary hematopoiesis and erythrophagocytosis could be seen on histologic sections of the spleen. Each of ten retroperitoneal lymph nodes contained extensive extramedullary hematopoietic tissue with red cell, white cell, and platelet precursors (Figs. 2A, 2B). The lymph nodes also showed evidence of red cell phagocytosis, hemosiderin deposition, and lymphogram effect.

Three weeks following surgery, the patient felt well. His hemoglobin had risen to 12.5 gms, platelets were 130,000 and the white cell count was $4,000/\text{mm}^3$.

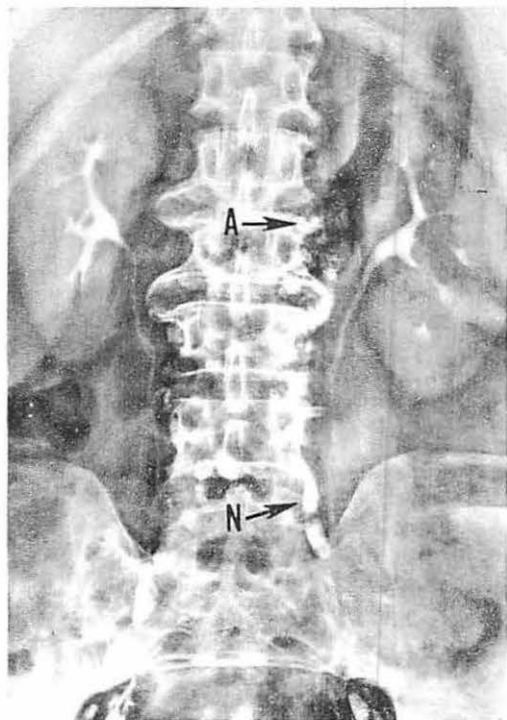

Fig. 1A Anterior-posterior lymphogram film. The more distal lymph nodes are normal (N). Nodes in the high para-aortic area (A) are enlarged and partially replaced.

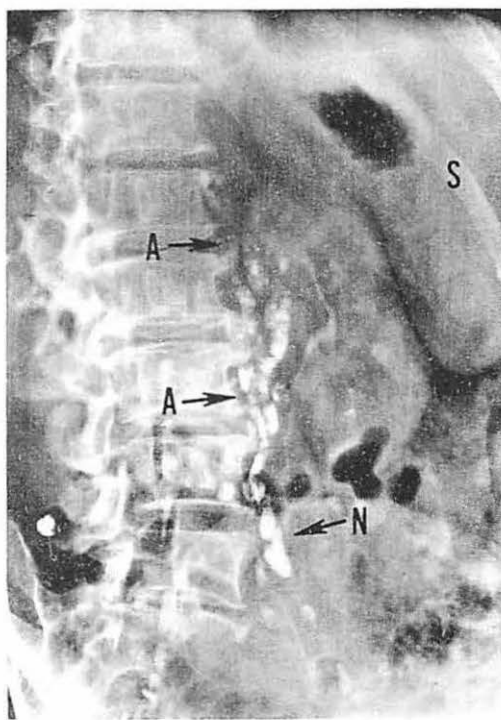


Fig. 1B Left posterior oblique lymphogram film. The abnormal high para-aortic nodes (A) are seen to better advantage. The margins are irregular and there are filling defects of varying sizes and shapes rendering a replaced appearance. Nodes in the left common iliac chain are normal (N). The spleen (S) is enlarged.

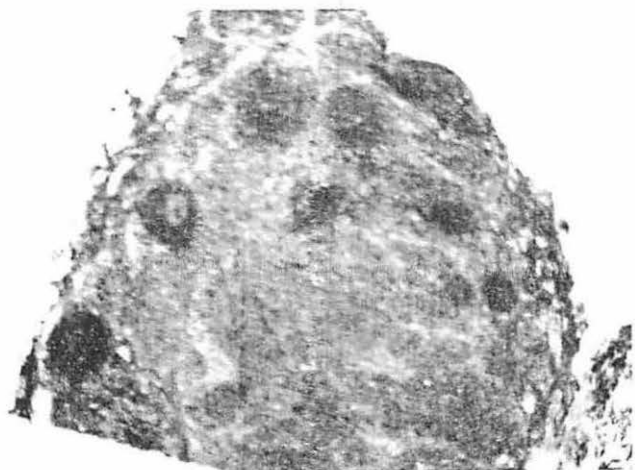


Fig. 2A Low power (10X) photomicrograph of a high paraaortic lymph node. A few darkly staining ovoids of residual lymph follicles are surrounded by a dense infiltrate replacing the remainder of the node.

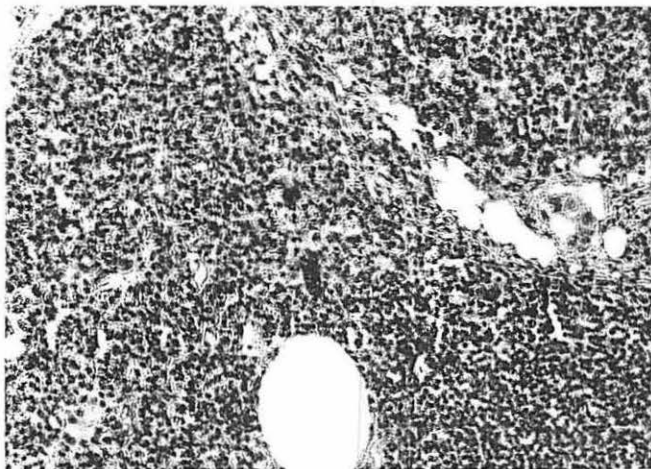


Fig. 2B High power (160X) view of this same node. A small portion of the edge of a remaining intact lymph follicle can be seen at the lower right hand portion of the photomicrograph. The cellular infiltrate consists of extramedullary hematopoiesis with prominent megakaryocytes.

Comment

Bottomly (1975) mentioned in a brief communication that he found lymphograms normal in two patients with myelofibrosis and extramedullary hematopoiesis (1). No illustrations or details were given. *Bree* and co-workers reported one year earlier that they observed anterior displacement of the thoracic duct on the lateral chest film of a patient with cyanotic heart disease and bulky masses of extramedullary hematopoietic tissue who had undergone lymphography (2). The appearance of the abdominal nodes was not described.

We would agree with the inference of *Parker*, *Blank*, and *Castellino* that any disease capable of affecting lymph nodes is capable of simulating lymphoma (3). We would suspect that pa-

tients with anemia who have lymphography frequently have changes secondary to ectopic blood forming tissues but that these alterations go unreported or unrecognized.

References

- 1 *Bottomly, J.P.*: Proceedings: Lymphographic Appearances of Some Uncommon Haematological Disorders. *Br. J. Radiol.* 48 (1975) 946
- 2 *Bree, R.L., H.L. Neiman, J.A. Hodak, R.E. Flynn*: Extramedullary Hematopoiesis in the Spinal Epidural Space. *J. Can. Assoc. Radiol.* 25 (1974) 297-299
- 3 *Parker, B.R., N. Blank, R.A. Castellino*: Lymphographic Appearance of Benign Conditions Simulating Lymphoma. *Radiology* 111 (1974) 267-274

Jerome J. Cunningham, M.D., Associate Professor, Department of Radiology, Bowman Gray School of Medicine, Winston-Salem, N.C. 27103 (919) 727-5297