

Passage through the Lymph Node. Studies with Watered and Oiled Contrast Medium given into an Afferent Lymphatic

K. Kett, L. Illényi, L. Lukács, J. Nyárady

1st Department of Surgery, University Medical-School Pécs/Hungary
(Head: Prof. T. Karlinger)

Summary

The authors investigated the passage of watered and oiled contrast media through the lymph node. Patent Blue dye diluted in saline has delineated as a rule only a circumscribed area of the lymph node according to the supplying area of the afferent cannulated. Lipiodol Ultrafluid has been found suitable for filling up the whole node: at first only a small part of the node became filled primarily from the afferent, while other parts were filled secondarily from the hilus. The compartmentalisation of the lymph node has been proved by autoradiography (^3H -thymidine), too.

Introduction

Recent observation and experimental data point more and more to the fact that the lymph nodes do not represent a homogenous structure but according to the afferent lymphatics they have rather separated compartments.

Hall and Morris, by means of translymphatic perfusion of the lymph node with ^3H -thymidine were not able to label but a part of the cellular output gained from the efferent lymphatics (1).

Richter assumes an other point of view, i.e. he says that afferent lymph vessels supply as a rule a not strictly delimited sector of the lymph node (4).

Hobbs and Davidson injected Microfil into one of the afferent vessels and found that the flow of the contrast medium from afferent to efferent lymphatics frequently occurred only through a segment of the lymph node with non-filling of many adjacent areas (2).

Zyb analysed the lymphographic picture of the lymph nodes in the first phase of filling and saw mostly a striped or even racemous structure which corresponded to separated

areas delimitable by their sinuses at the hilus (5).

Kinmonth reported on his own finding in a personal communication as follows: "We have often seen one afferent lymphatic fill a whole node. Obviously there cannot be strict compartmentalisation in the nodes. It must be possible for spillover to occur from one sector to another, to allow the whole node to fill. Certainly, whatever the explanation, it is an observation frequently made" (3).

However, we have the experience gained from our own studies, that the injection of Patent Blue V. into one of the afferent lymphatics will visualize a rather strict sector of the popliteal node in rabbits, in contrast to the direct lymphography of the human breast, by which the whole Sorgius node can be filled through a single lymphatic.

In order to clear this contradiction we have studied the intranodal flow of watered and oiled contrast media.

Material and Methods

The experiments were carried out on albino New-Zealand-rabbits. 0,2-0,3 ml. of 4 % Patent Blue dye was injected intracutaneously into the hind pads in order to study the popliteal lymph nodes, the efferent lymphatics and the afferent lymph vessels, respectively.

By the investigations with contrast medium and isotope-containing solution only 0,05-0,1 ml. of Patent Blue dye was applied for visualizing the afferent lymphatics. Immediately after the injection of the dye one of the bluish-stained afferents was exposed on the medial side of the leg, then cannulated with a 20-gauge needle. In order to hinder further inflow of the dye,

the distal part of the hind limb was strangulated by a thread. Following this manoeuvre, 1 ml. of 4 % Patent Blue was now injected utmost slowly into the cannulated afferent vessel, then washed out, after taking a photo, with physiological saline. Subsequently we injected 1 ml. Lipiodol Ultrafluid stained with Chlorophyll and took a photograph after each 0,1 ml. injected. Finally the popliteal lymph node was removed and radiographed.

The study of intranodal microcirculation of lymph was also supplemented by investigating the distribution of ^3H -thymidine (50 uCi diluted in 0,2 ml. saline) administered through the cannulated afferent lymphatic. 50 minutes later the popliteal nodes were removed, fixed in 4 % formol for 24 hours, then embedded in paraffin to prepare $4\ \mu$ thick sections. The cuts were covered with Ilford G4 emulsion at 4°C for 10 days, then fixed and stained with hematoxylin-eosin.

Results

Following the intracutaneous injection of 0,2–0,3 ml. Patent Blue dye into the hind pad, there were generally 2–4 medially located afferent lymphatics visible, while 2–3 also afferent lymphatics took their course along the lateral margin of the leg. The medial ones turned lightly backwards filling as a rule only the lower part of the popliteal node, while the afferent vessels running laterally, made all of a sudden, a sharp-curved wind to the medial backside and supplied the upper part of the node. From the hilus of the node we found generally two, bluish-stained efferents running towards the inguinal region.

The vital dye (Patent Blue V.) given into one of the medial afferents delineated at the beginning only the minute lymphchannels of second and third degree, spreading along the anterior surface of the node (Fig. 1). Further, continuous injection of the dye yielded two ovalshaped spots according to the cannulated afferents. These spots maintained their sharp-lined limits even if further injection of the dye was performed, and did not change in extension (Fig. 2).

Fig. 2 Further continuous perfusion with Patent Blue dye (1,0 ml.) resulted in filling up two oval-shaped areas, according to the supplying field of the afferent cannulated.

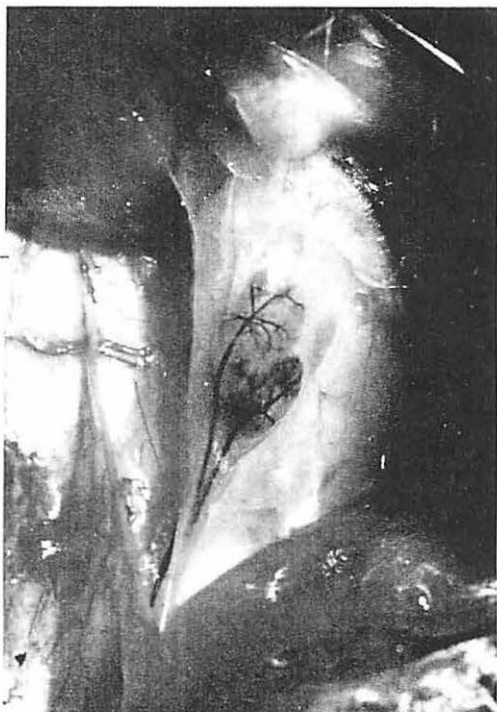
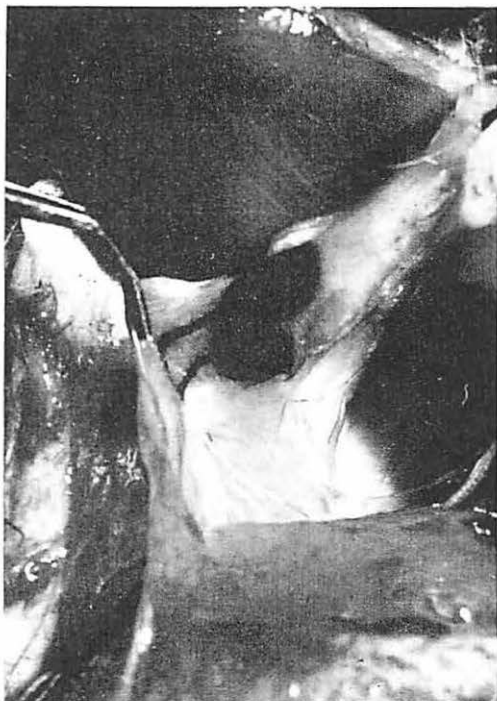
Fig. 1 Macroscopic view of the popliteal node in the rabbit, immediately after the injection of 4 % Patent Blue dye into an afferent lymphatic.



We had the same experience, when the popliteal node washed out first with saline had been repeatedly filled with 1,0 ml. Lipiodol Ultrafluid stained with Chlorophyll. On the roentgenogramm made after the removal of the popliteal node we also saw only one or two oval-shaped areas containing the contrast medium, while both efferent lymphatics had been visualized either after the intralymphatic injection with diluted Patent Blue dye or following the administration of the Chlorophyll-stained oily contrast medium (Fig. 3).

However, further continuous injection of Lipiodol-Ultrafluid resulted in more and more oval-shaped spots, attached to each other, although the "newly-stained" areas had become less green of Chlorophyll than the spots delineated at first and showed a fine granulation (Fig. 4 and Fig. 5).

During the lymphography it has become quite clear, that there are generally two spots bulging out beneath the efferent lymphatics which correspond to their sources. They are slowly growing in size until some side-lobules also become filled with contrast medium. However it suggests that a great part of the node becomes stained by the turn-back of the contrast material from the hilus (Fig. 6a-f).

The removed lymph nodes showed a rather strict compartmentalization, according to to supplying area of the afferent lymphatic stained intensively green and a faintly stained part, delineated only later. The roentgenograms corresponded well to the macroscopic observation showing a more intensive filling in the lymph node part which had been perfused by the afferent lymphatic. As to the autoradiographic studies, labelled cells have been seen only in the cortical region of a limited area mentioned above and marked by a distinct furrow after perfusion with Patent-Blue dye. However, this delimitation was far not so unambiguous in the medullary area in contrast to the cortical area, where labelled cells were only sparsely encountered in the neighbouring cortical part of the nodes beyond the "furrow" seen macroscopically (Fig. 7). The compartmentalization of the cortex was

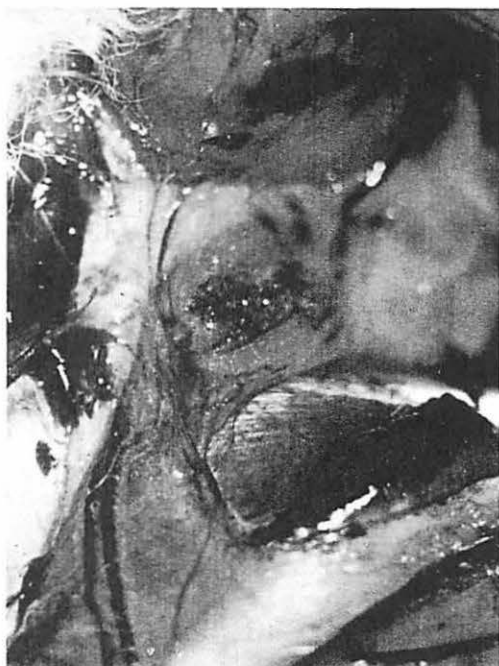

Fig. 3 The translymphatic perfusion with Chlorophyll-stained oiled contrast medium (Lipiodol Ultrafluid) delineated first also two "lobules" supplied from the afferent lymphatic which had been cannulated. Two tortuous efferent vessels became also visible.

so distinct that cutting along the edge of the stained area we succeeded to obtain sections which showed a striking difference in labelling of follicles situated next to one another.

Discussion

The popliteal lymph node of rabbits can mainly be divided into two parts: the lower pole is supplied by the medial lymphatics, while the upper pole of the node is generally perfused by a laterally placed lymphatic plexus. The two plexus consist of 4-7 afferent lymphatics, while there are only two efferent lymphatics emerging from the lymph node. Watered solutions such as Patent Blue dye in saline, or saline containing tritiated thymidine will fill only a rather strict area of the node, if injected into one of the exposed afferent lymphatics. This area corresponds only to the supplying field of the afferent cannulated. However these solutions pass through the

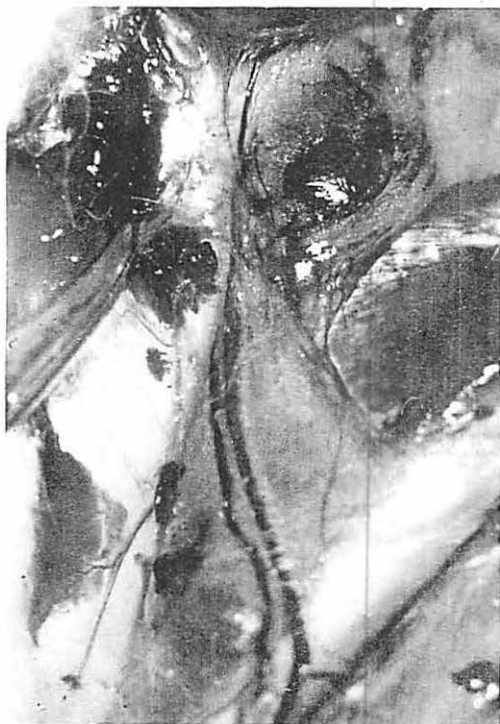

Fig. 4

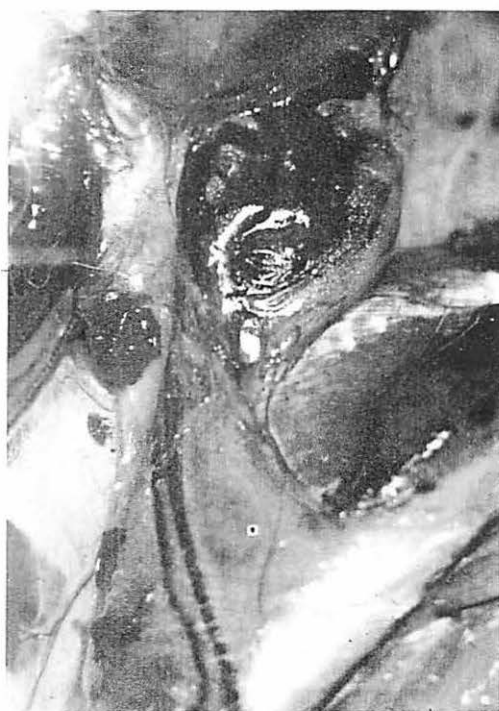

Fig. 5

Fig. 4 u. Fig. 5 Further perfusion with Chlorophyll-stained Lipiodol: more and more oval-shaped spots appear and merge into one another. However, the newly-stained areas are less green and show a fine granulation.

effluent lymph vessels, too, which all goes to show that there must be a communication in the hilus of the node.

The afferent lymphatics entering the lymph node on its convexity do not fill immediately the marginal sinus, but passing intermediary sinuses (5) quite similar to the circulation of blood within the node (2) they do form small supplying units.

Oily contrast media such as Lipiodol Ultrafluid will pass first also as a rule only a small part of the node supplied from the afferent vessel and fill both efferent vessels, too. Thereafter as one can see on the roentgenograms and by the naked eye, respectively, the contrast medium will stain more and more of the node, forming a lobe to merge finally into a common shape representing the whole lymph node. It means that only a small part of the node will be

passed primarily from the afferent, while other parts will be filled secondarily from the hilus. The cause for this phenomenon lays in all probability in the different viscosity of oiled contrast medium, and that is why watered contrast media are unsuitable for lymphographic examinations.

The mechanism of filling described above makes it possible to perform direct lymphography of the breast where collector lymphatics, situated centrally of the areolar and subareolar plexus, usually do not ramify and the oiled contrast medium injected into a single afferent lymphatic will get immediately into the Sorgius node. Furthermore, this mechanism of filling is responsible for the imperfect delineation of lymph nodes by an interrupted examination or if the amount of the contrast medium injected was not sufficient to fill up the whole node.

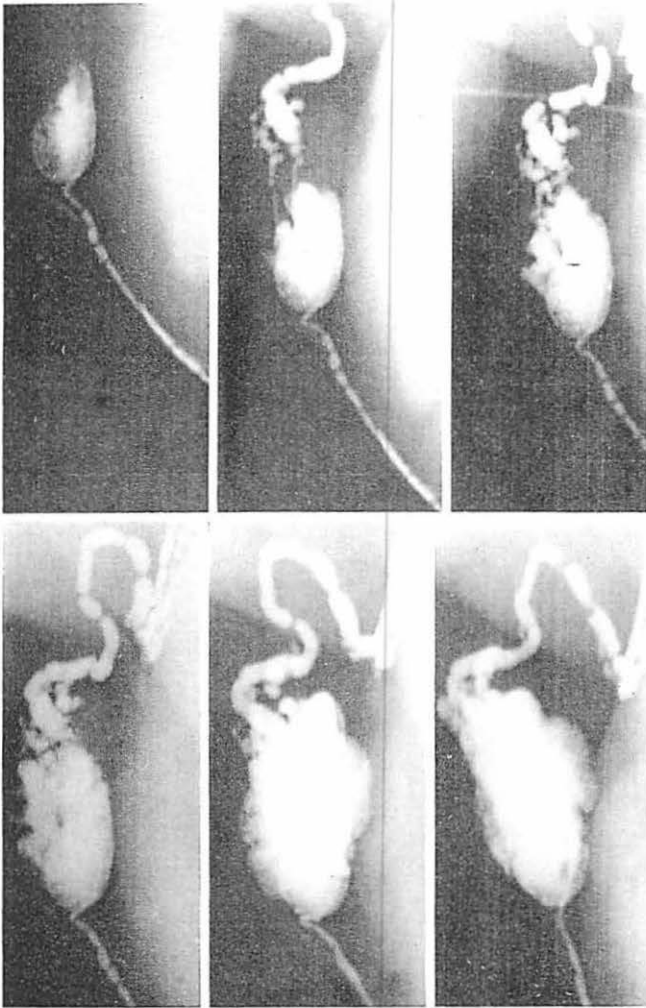


Fig. 6 Different phases of contrast-filling during lymphography with Lipiodol Ultrafluid.

- a) afferent vessel and its supplying area
- b) two efferent lymphatics and two spots according to their "source" are visible
- c) and d) the two spots where the afferents take their source are enlarged
- e) a new side-lobule is getting filled
- f) lymph node fully delineated



Fig. 7 Compartmentalization of the cortex as seen by autoradiography (^3H -thymidine). Labelled cells were mainly seen in follicles of a delimited segment supplied by the afferent vessel which had been used for perfusion.

References

- 1 *Hall, J.G., B. Morris*: The immediate effect of antigens on the cell output of a lymph node. *Brit. J. Exp. Pathol.* 46 (1965) 450–454
- 2 *Hobbs, B.B., J.W. Davidson*: The microcirculation of the mammalian lymph node. *Lymphology* 9 (1976) 155–157
- 3 *Kinmonth, J.B.*: Personal communication (letter of 16^h March 1977)
- 4 *Richter, J.*: Entwicklung, Struktur u. Aufgabe des Lymphsystems. In: Lünig-Wiljasalo-Weissleder: *Lymphographie bei malignen Tumoren*. 2. Kapitel. VEB Georg Thieme, Leipzig 1976
- 5 *Zyb, A.F.*: Spezielle Röntgenanatomie der Lymphgefäße und Lymphknoten. 8. Kapitel in: Lünig-Wiljasalo-Weissleder: *Lymphographie bei malignen Tumoren*. VEB Georg Thieme, Leipzig 1976

Dr. K. Kett, 1st Department of Surgery, University Medical School Pécs, Pécs/Ungarn