

Cannulation of the Thoracic Duct in Man

Allan E. Dumont

New York University School of Medicine, New York, N.Y., USA

"The contents of the thoracic duct in the human subject having never been obtained in sufficient quantity for the purposes of chemical analysis, I resolved to avail myself of an opportunity which lately presented itself in the execution of a criminal at the Old Bailey.

"I was enabled to commence operating upon the body one hour and a quarter after death and before it had become cold, although the thermometer stood considerably below 32° Fahr., and the body had been exposed on the scaffold during one hour."

(On the chemical analysis of the contents of the thoracic duct in the human subject by G. Owen Reese, M.D., F.G.S., Physician to the Northern Dispensary. Philosophical Transactions, Royal Society of London 1842, p. 81).

Access to human thoracic duct lymph is no longer the problem it was in 1842. Shortly after the turn of the century, it became clear that the thoracic duct could be ligated without sequelae. By 1960 difficulties in collecting thoracic duct lymph had been overcome, and it was established that the duct could be safely cannulated in the neck. Now that misgivings about manipulation of the duct in man have finally been resolved, examination of its flow and contents has become an important frontier in clinical investigation.

Functioning as an appendage of the cardiovascular system, lymph vessels carry out the vital operation of collecting and transporting plasma protein from capillary filtrate back to blood. Normally about 40% of the total plasma-protein pool plus a volume of fluid equal to plasma volume are returned to the blood via the thoracic duct every 24 hours. The system comprises an extensive network of distensible

vessels which resemble and develop from veins. Lymphatics from the abdominal viscera and lower half of the body converge just below the diaphragm to form the cisterna chyli.

From the cisterna the thoracic duct ascends as a single or double channel through the mediastinum into the left side of the neck where it empties into the angle of the jugular and subclavian veins. From its origin at the diaphragm to its termination in the neck, the duct receives no important tributaries (except for a component of lung lymph) and is uninterrupted by the interposition of nodes. Under normal circumstances thoracic duct lymph derives almost entirely from the liver and from the extrahepatic portal bed in approximately equal amounts.

The thoracic duct is an extremely thin-walled, flimsy structure and its junction with the vein is often rather inconspicuous. Manipulation of such an unsubstantial structure requires patience and a gentle hand; with experience, cannulation of the cervical portion of the duct may be carried out successfully in 80% to 90% of patients. Since a number of recent observations indicate that alterations in flow and composition of thoracic duct lymph are important components of disease in man, interest in thoracic duct lymph is no longer confined to theoretical considerations. Details concerning the collection of thoracic duct lymph in man and the nature of information which may be derived from its study form the basis for this review.

Anatomical Features of the Thoracic Duct Venous Junction

In most patients the duct forms a slightly inverted "U" on the dorsal aspect of the

internal jugular vein and crosses the ventral aspect of the vertebral vessels, the thyrocervical trunk, the phrenic nerve, and the scalenus anterior muscle. Jugular and subclavian lymph tributaries empty into the thoracic duct at various distances from the latter's entry into the venous system. In 30 dissections of the duct in man, *Shafiroff* found that the duct entered the terminal portion of the internal jugular vein in 63%, the subclavian vein in 23%, the angle between the two veins in 10%, and the innominate vein in 6%(1).

The site and mode of entry of the duct into the venous system vary within certain limits. Ampullary dilatation of the duct just before its entry into the venous system is found in at least 50% of human subjects; two to three small ducts rather than a single trunk frequently course from this ampulla to the junction with the venous system. Two valves near the 1-v junction appear to be situated in order to prevent backflow of blood from the venous system. According to *Pflug* and *Calnan*, the valves are unusually long and situated obliquely in the duct about 1 cm from its termination (2). They appeared to remain competent, even when the duct is fully distended. Differences in the tension of the vein wall seem to determine whether the valves are open or closed. On the vein side, a single larger valve at the junction of the jugular with the innominate vein overlies the opening of the thoracic duct. In normal man the diameter of the duct in the neck averages about 2 to 3 mm, and the duct wall thins out as it approaches the 1-v junction (3).

Layers corresponding to the interna, media, and adventitia of a vein can also be identified histologically in the mammalian thoracic duct, although they are much less substantial in the latter. There are species differences with respect to the amount of smooth muscle in the media.

Anesthesia for Cannulation

While either general or local anesthesia may be utilized, the latter is preferred in most cases; preanesthetic medication is usually helpful.

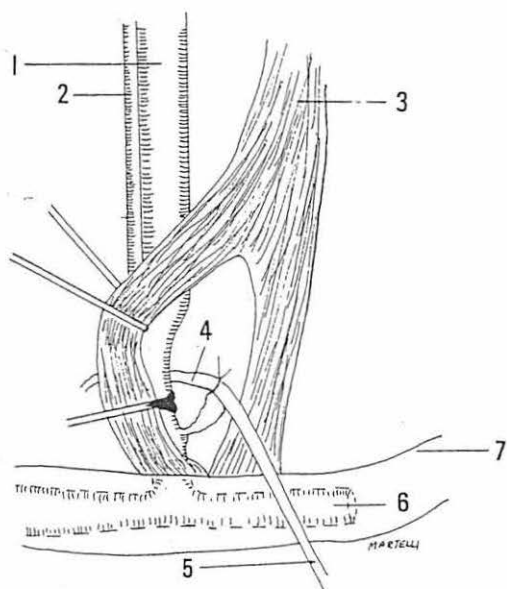


Fig. 1 Cannulation of the thoracic duct.

1. Internal jugular vein - 2. Common carotid artery
3. Sternocleidomastoid muscle - 4. Thoracic duct
5. Cannula in thoracic duct - 6. Subclavian vein
7. Left clavicle.

According to *Werner* conduction and infiltration anesthesia may be combined in the following manner (4). After a preliminary injection of local anesthetic into the region in which the transverse cutaneous nerve emerges from behind the left sternocleidomastoid muscle (SCM), the anesthetic is infiltrated subcutaneously along the line of the proposed incision, that is, a finger-breadth above and parallel to the inner end of the left clavicle. During the subsequent dissection, anesthetic is injected into the SCM and into the deep cervical fascia.

Exposure and Cannulation of the Duct (Fig. 1)

Most surgeons prefer to position the patient with the neck hyperextended with a pillow in the midline between the shoulders; the operating table is tilted so that the head end is elevated (in order to lower distension of the cervical veins). While some prefer to turn the head slightly to one side or the another, other surgeons find the midline position most satisfactory.

In preparing and draping the lower left side of the neck, it is useful if the skin towel placed over the patient's head and face is fastened at the upper end of the field to an instrument tray (Mayo stand). A 4-cm skin incision is made about one fingerbreadth above and parallel to the inner end of the left clavicle, the incision is carried down through the platysma. The interval between the sternal and clavicular heads of the SCM is then identified, and the sternal portion is freed up and retracted medially. The lateral head may be divided if additional exposure is necessary. With the omohyoid muscle retracted laterally and superiorly, the deep cervical fascia is opened carefully, and the lateral border of the internal jugular vein is identified. The vein is then gently dissected to its junction with the subclavian so that it may be retracted medially. The terminal ampullary dilatation of the thoracic duct is then exposed by extremely careful dissection of the loose areolar tissue behind and/or lateral to the lowest portion of the internal jugular vein. The duct is gently cleared of surrounding tissue for a distance of about 1 cm, and with the help of a small right angle clamp, a ligature is placed around it for gentle retraction. A small opening is then made in the duct with iris scissors. To avoid retrograde bleeding, the opening in the duct should be placed far enough (at least 1 cm) from the thoracic duct-venous junction to insure the interposition of a competent valve between the junction and the duct opening. (In patients with long-standing dilatation of the duct, this valve may be incompetent). A plastic catheter (silastic is considered the least likely to clot) is then inserted in a retrograde direction into the duct, and the ligature is tied to secure the cannula in place. Resistance to passing the cannula into the duct is usually encountered quickly due to the presence of a valve. For this reason it is not possible to place more than a few millimeters of tubing into the duct. Under no circumstances should the cannula be passed forcibly as the thin-walled duct is easily perforated. When the duct is distended and the valves have become incompetent, retrograde bleeding from the venous end of

the duct during cannulation can be avoided by temporarily placing a second untied ligature close to the venous junction for gentle retraction.

Various techniques have been used in an attempt to avoid kinking of the cannula and/or its accidental withdrawal. Some surgeons prefer to bring the cannula out through a subcutaneous tunnel exiting several centimeters away from the skin incision. Others bring the tubing out through the incision and then suture a coil to the skin. If the lateral head of the SCM has been divided, it should be resutured and the platysma approximated with one or two sutures. The skin is closed in the usual manner without drainage.

When plans call for intermittent sampling of lymph, the technique described here can be modified to allow lymph to flow or be pumped into the venous system (10). This requires an indwelling venous catheter which is connected to the cannula in the thoracic duct by means of external tubing. At times, and depending on the anatomical arrangement of the duct, intermittent sampling can also be accomplished by inserting the cannula into a side branch of the thoracic duct (11).

Prior to removing the cannula, it may be important (particularly in patients with excessive flow rates) to raise the level of the draining end for 6 to 12 hours in order to impair flow and promote rerouting of lymph into the venous system through collateral pathways. Most investigators then simply remove the cannula at the bedside and apply a snug pressure dressing with an elastic bandage for 2 to 3 days. Drainage usually stops within a few hours in patients for whom flow rate was normal. Other surgeons prefer to reopen the wound in the operating room, identify the duct, remove the cannula, and close the incision in the duct with fine vascular sutures.

Replacement Therapy

During short periods of external lymph drainage, when lymph flows at a normal rate of 1 cc per minute or less, loss of water and electrolytes may be replaced by increasing the oral intake of salt-containing fluids. At

times, lymph may be cooled and returned to the patient by mouth. If adequate amounts of fluid cannot be given by the oral route, salt-containing solutions (Ringer lactate, isotonic saline, or plasma) are administered intravenously. Intravenous administration of albumin is usually not required. Hematocrit is determined 2 to 3 times daily as a useful guide to fluid replacement. When lymph flow is excessive, careful replacement is vital. Under these circumstances monitoring the fluid balance is managed best with the patient on a metabolic bed scale or in a clinical research or intensive care unit. The volume and composition of the fluid administered intravenously is then determined by vital signs, hematocrit, central venous pressure, urinary output, BUN, and serum content of electrolytes and protein. When large volumes of lymph are drained, protein depletion can be avoided by intravenous administration of albumin, plasma or anticoagulated lymph in sufficient amounts.

Complications

The most frequent complication is accidental displacement of the cannula from the lumen of the duct. Lymph flow may cease however, even though the end of the cannula remains fixed in the duct. This is usually caused by kinking of the tubing followed by formation of a clot. In this event a sterile wire suture may be introduced into the cannula to withdraw the clot and reestablish flow. Attempts to reestablish flow by forcible injections of heparinized saline or any other fluid into the duct may be hazardous since the force of the injection usually serves to dislodge the internal end of the cannula from the duct. Some accumulation of chyle in the wound, in the pleural cavity, or in both locations occurred in about 20% of patients according to some early reports; both problems usually resolve spontaneously (8). The incidence of pneumothorax after thoracic duct cannulation is unknown, but all patients should undergo radiographic examination of the chest postoperatively to determine if this has occurred. In patients for whom the flow rate of thoracic duct lymph is not excessive, neither acute nor chronic problems due to lymph stasis have

been reported following cannulation. Postoperative lymphangiographic studies have confirmed that the duct usually remains patent after removal of the cannula (12). Should the leakage of lymph continue after removal of the cannula, however, ligation of the thoracic duct may be carried out in most patients without sequelae. On the other hand, experience in patients with Laennec's cirrhosis and an excessive rate of lymph flow has shown that ligation of the duct may be hazardous, resulting in either hemorrhage from esophageal varices, exacerbation of ascites, or both (13).

A small proportion of patients complain of low back pain upon removal of the cannula and application of a pressure dressing. This pain usually subsides gradually but may be relieved immediately by reestablishing lymph drainage. This suggests that such pain is due to sudden stretching of the retroperitoneal lymph trunks (14).

Information from Studies of Thoracic Duct Lymph

Information concerning an almost endless variety of physiological and pathophysiological problems can be obtained in man through studies of thoracic duct lymph (15-19). A partial list of normal lymph constituents and/or pharmacologically active substances studied to date in man under various conditions includes the following: lipids, fat-soluble vitamins, proteins and amino acids, urea, clotting factors, enzymes (particularly those formed in the liver and gastrointestinal tract including the pancreas), respiratory gases, and immunologically active cells and protein. Among the abnormal constituents found in patients with various disorders are tumor cells (particularly in abdominal neoplasia, Hodgkin's disease and other lymphomata), Whipple cells, bilirubin, and bacteria. Abnormally large lymph flows are found in patients with systemic or portal venous circulatory congestion who convert plasma into lymph at an abnormally high rate. In such patients the volume of excess lymph can amount 3 to 4 times the blood volume in a 24-hour period, a derangement which appears to underlie some common clinical manifestations of these disorders.

References

- 1 *Shafiroff, B.G.P., Q.Y. Kau*: Cannulation of the human thoracic lymph duct. *Surgery* 45 (1959) 814-819
- 2 *Pflug, J., J. Calnan*: The valves of the thoracic duct at the angulus venosus. *Br. J. Surg.* S5 (1956) 911-916
- 3 *Lindeman, C., F. Borchard, F. Huth*: Morphometric investigations of the thoracic duct in cirrhosis of the liver. *Folia Angiol.* 21 (1973) 274-277
- 4 *Werner, B.*: Thoracic duct cannulation in man. *Acta. Chir. Scand. Suppl.* 353 (1965)
- 5 *Bierman, H.R., R.L. Byron, K.H. Kelly, R.S. Gilfillan, L.P. White, N.E. Freeman, N.L. Petrakis*: The characteristics of thoracic duct lymph in man. *J. Clin. Invest.* 32 (1953) 637-649
- 6 *Linder, E., R. Blomstrand*: Technic for collection of thoracic duct lymph in man. *Proc. Soc. Exp. Biol. Med.* 97 (1958) 653-657
- 7 *Shafiroff, B.G.P., Q.Y. Kau*: Cannulation of the human thoracic lymph duct. *Surgery* 45 (1959) 814-819
- 8 *Werner, B.*: Thoracic duct cannulation in man. *Acta. Chir. Scand. Suppl.* 353 (1965)
- 9 *Tilney, N.L., J.E. Murray*: Chronic thoracic duct fistula. *Ann. Surg.* 167 (1968) 1-8
- 10 *Lilliequist, L., B. Larsson, S.I. Jacobson, A.A. Alveryd*: A technique for creating a thoracic duct shunt. *Surg. Gyn. Obst.* 132 (1971) 896-897
- 11 *Girardet, R.E., D.L. Benninghoff*: Thoracic duct lymph and lymphocytic studies in man using a thoracic duct side fistula. *Cancer* 29 (1972) 666-669
- 12 *Werner, B.A.*: Thoracic duct cannulation in man II. A follow-up study on 22 patients. *Acta. Chir. Scand.* 132 (1966) 93-105
- 13 *Dumont, A.E.*: Unpublished observations.
- 14 *Shelradeh, I.H., R.D. Guttmann, J.E. Murray, J.P. Merrill*: Thoracic duct drainage and low back pain. *J. Amer. Med. Assn.* 207 (1969) 558-559
- 15 *Dumont, A.E., M.H. Witte*: Clinical usefulness of thoracic duct cannulation. (In) *Advances in Internal Medicine*; G. Stollerman ed. Vol. 15. Year Book Medical Publishers pp. 51-71. Chicago, USA 1969
- 16 *Evans, J.T., E.D. Holyoke*: Thoracic duct drainage: current status. *Rev. of Surg.* 32 (1975) 77-83
- 17 *Cevese, P.G., R. Vecchioni, C. Cordiano, D.F. D'Amico, G.A. Forello, G. Favia, R. Biasiato*: Surgical techniques for operations on the thoracic duct. *Surg. Gyn. Obst.* 140 (1975) 957-965
- 18 *Blomstrand, R., C. Franksson, B. Werner*: The transport of lymph in man *Appelbergs Boktryckeri A.B.*, Uppsala 1965
- 19 *Dumont, A.E.*: The flow capacity of the thoracic duct-venous junction. *Am. J. Med. Sci.* 269 (1975) 292-301

Allan E. Dumont, M.D. New York Univ. School of Medicine, 550 First Avenue, New York, N.Y., 10016 USA