

Effects of Corticosteroid and Radiation on Lymphoid Tissue in Mice. Comparisons and Mutual Interactions.*

P. Lundin, B. Järplid

Institute of Pathology, University of Göteborg, Sweden and Division of Radiobiology, Research Institute of National Defense, Sundbyberg, Sweden

Summary

The phases of involution and regeneration in the lymphoid tissues of mice were compared between total body irradiation with a single dose of 500 R and injection of a single dose of 8 mg prednisolone. These dosages induced a comparable degree of acute involution of the thymic cortex, and were the minimum dosages which, in the acute phase, produced cytolysis of all cortical small lymphocytes, with a largely preserved medulla.

After steroid treatment the lymphocytolysis in the lymph nodes, spleen and the Peyers patches was most marked in the germinal centres whereas the so-called thymic dependent areas were mainly preserved. After irradiation compared to steroid-treatment the cytolysis was definitely more pronounced in all parts of these lymphoid tissues, including the white pulp of the spleen, the whole follicles and the subcapsular parts of the lymph node cortex and the follicles and partially the inter-follicular areas of the Peyers patches.

From the time of the first regeneration of the thymic cortex after irradiation, steroid sensitive cells could be found in all lymphoid tissues, indicating that the pool of these cells regenerates rapidly after irradiation.

The intensive research during the last few years on the structure and function of lymphoid tissues has, among other things, proved the heterogeneity of the lymphoid cell population. Many of the pertinent problems are still unsolved but it seems obvious that lymphocytes may be short-lived or long-lived, they may or may not belong to a thymus dependent or thymus derived population, and they may be more or less sensitive to radiation or to the lytic action of corticosteroids. The relationship of these morphologically identifiable lymphocyte population is still not satisfactorily defined.

The strong destructive effect of ionizing radiation on normal lymphoid tissue and lymphocytes is well known (c.f. Murray, 1, Trowell, 2). The extreme sensitivity to corticosteroids of some lymphocytes, especially the small lymphocytes of the thymic cortex has been known since Selye (3) described his adaptation syndrome. The morphology of this acute involution is thoroughly described among others by Dougherty (4, 5).

In short-time radiation experiments Dougherty and White (6) showed that a small dose (10 R) essentially influenced the lymphoid tissue by augmenting the adrenal cortical secretion, while a larger dose (200 R) could produce lymphocytolysis without adrenal mediation.

*This work was supported by a grant from Swedish Medical Research Council (B71-12X-592-06c)

The modern views on cell cooperation in the immune response, where a special role is assigned to a thymus derived or dependent lymphocyte (T-cell, c.f. *Miller & Mitchell, 7, Miller & Sprent, 8*) warrant more penetrating studies of the apparently short-lived steroid and radiation sensitive lymphocyte, which is the dominating cell type in the thymic cortex.

The aim of the work presented below is to compare the steroid sensitive lymphocyte population to the radiation sensitive with special reference to the thymic cortex and the thymic dependant areas (*Parrot et al. 9*) in the lymphoid tissue, and a possible influence of the adrenal function on the radiation effects in the lymphoid tissue.

Material and Methods

Female CBA mice, 70 to 80 days old were used. They were fed ad libitum with a standard mouse diet and water.

Irradiation. The animals were given one single dose of irradiation (500 R) in a plastic "wheel" as described earlier (*Järplid, 10*). This radiation dose was found to be the minimum dose which apparently disintegrated all the small lymphocytes in the thymic cortex.

Steroid treatment. The water soluble prednisolone succinate (Precortalone Ciba) was used as corticosteroid. This preparation has, in contrast to the crystalline suspensions mostly used, no depot effect (c.f. *Lundin & Schelin, 11*). After preliminary experiments with 150 to 550 R and 1 to 16 mg of prednisolone, 500 R of irradiation and 8 mg of prednisolone were used in the main experiments. These doses were found to be the minimum doses to give a maximal response observed as a total involution of the thymic cortex.

Adrenalectomy was done by the dorsal route under ether anesthesia. At the end of the experiments the animals were anesthetized with ether and a blood sample was obtained from the retroorbital veins for counting of mononuclear cells (lymphocytes and monocytes) and granulocytes.

The animals were killed by ether. The thymus and spleen, and axillary, brachial, inguinal and mesenteric lymph nodes and adrenals were dissected out and weighed. In addition parts of the distal ilium with *Peyers* patches and sternal and femoral bone marrow were saved. All specimens were fixed in *Stieve's* fluid (*Romeis, 12*) and conventional histologic methods were used.

Planning of the Experiments

The main outlines of the experiments and the experimental groups are apparent from Figs. 1 and 2 where the weights of the thymus are presented.

Experimental groups:

1. One untreated control group. 20 animals.
2. One group irradiated on day 0 and followed 35 days (radiation group). 60 animals.
3. One group given 8 mg prednisolone on day 0 and followed 35 days (prednisolone group). 60 animals.
4. Smaller groups ($n = 3-5$) irradiated on day 0 and, at various times later, adrenalect-

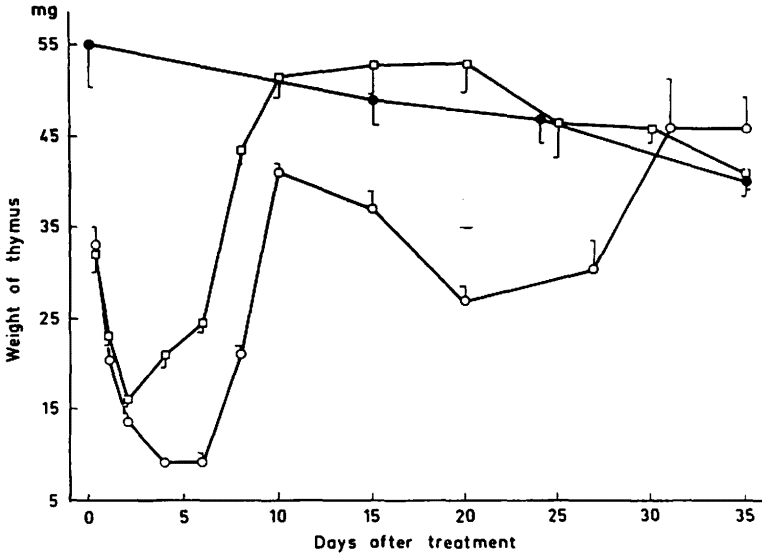


Fig. 1. The weight of the thymus after prednisolone treatment or irradiation.

Symbols: ● controls
 □ prednisolone
 ○ irradiation

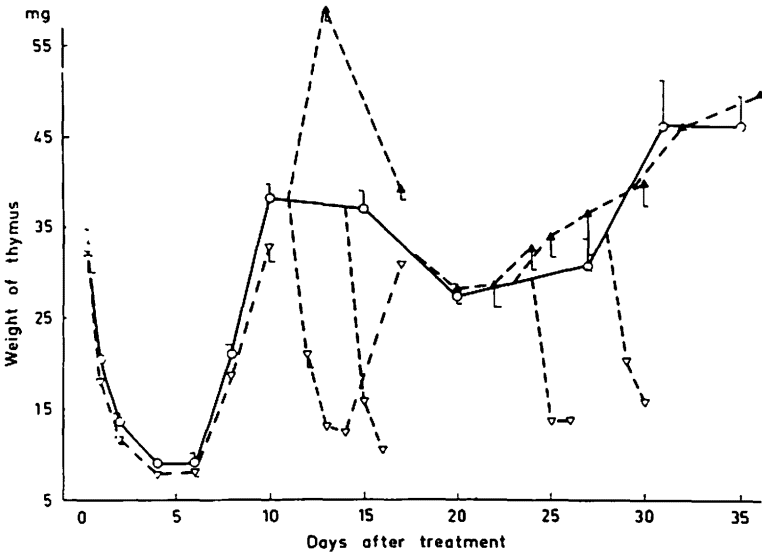


Fig. 2. The weight of the thymus after irradiation and treatment with prednisolone or adrenalectomy various times after the irradiation.

Symbols: ○ irradiation
 △ irradiation + prednisolone
 ▲ irradiation + adrenalectomy

tomized (days 0, 11, 17, 26, 29) or given 8 mg prednisolone (days 11, 14, 24, 28). These animals were killed 1 to 7 days after the last treatment.

The morphological effects of radiation or of corticosteroids on lymphoid tissue are described earlier in detail and our present results agree with these. Consequently, the presentation of the data and the discussion following are mainly restricted to a comparison between the effect of radiation and steroids and to the influence of adrenal cortical function on the radiation induced involution.

Results

Thymus. The weight of the thymus at various times after a single dose of 500 R or 8 mg of prednisolone is seen in Fig. 1. After steroid treatment the weight reached its minimum on day 2, whereafter it increased to a normal value at day 10 and then seemed to remain at a normal level. After irradiation, on the other hand, the thymus regenerated biphasically as is described earlier (c.f. *Järplid*, 10). No apparent histological differences were observed between the two groups in the acute involution and regeneration of the thymus.

The effect of prednisolone on the thymus weight at different times after irradiation is seen in Fig. 2. Neither the weight decrease nor the histological picture in the first involution phase after irradiation was apparently affected by prednisolone treatment.

In the first regeneration phase on days 10 to 14, the thymus was very sensitive to the prednisolone treatment and the weight reduction was of the same magnitude as in the first involution phase. Histologically the cortex showed a pronounced cytolysis but also some small preserved areas with smaller or medium sized cells. The regeneration of the cortex after the prednisolone induced involution on day 11 was rapid and the thymus weight reached the level of the radiation group on day 17.

In the second involution phase and in the following regeneration, the steroid sensitivity of the cortex was still preserved, observed both as a weight decrease and a microscopically pronounced cytolysis.

The effect of adrenalectomy on the different phases of the involution and regeneration after irradiation is also seen in Fig. 2. Adrenalectomy did not change the first acute involution. In the first regeneration phase a fairly pronounced weight increase was observed and, in the second involution phase an insignificant increase of the weight.

Lymph nodes. The weights of the lymph nodes after irradiation or prednisolone treatment are seen in Fig. 3. Compared to the steroid the regeneration induced involution after irradiation was very slow and on day 35 weight was still significantly lower than in the controls.

Histologically the most pronounced cytolysis after both types of treatment was observed in the germinal centres, but in addition the irradiation resulted in a wide spread cytolysis in all the cortex especially the subcapsular part and also in the paracortical area.

Prednisolone treatment at various times after irradiation resulted, except in the first acute phase, in an additional decrease in the lymph node weight (Fig. 4). Adrenalectomy in the same phases increased the weight, without any apparent histological changes.

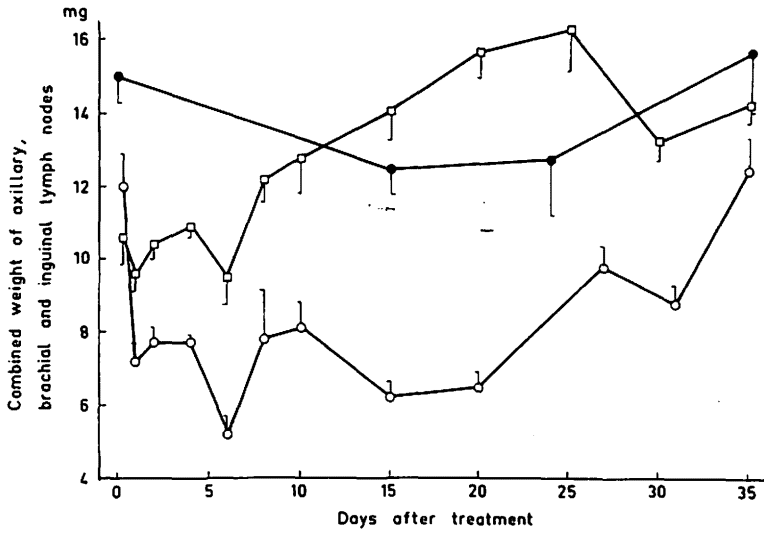


Fig. 3. The combined weight of lymph nodes after prednisolone or irradiation. Symbols as in Fig. 1.

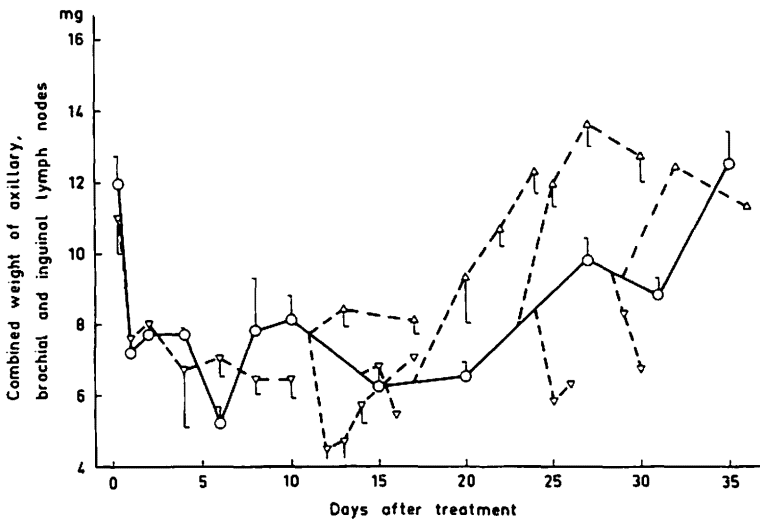


Fig. 4. The weight of lymph nodes after irradiation and prednisolone or adrenalectomy various times after the irradiation. Symbols as in Fig. 2.

Spleen. The effects of irradiation or prednisolone treatment on the weight of the spleen are seen in Fig. 5. The maximum effect after steroid treatment was seen after eight hours. The normal weight was reached on day 8. The radiation-induced hypoplasia was mainly reached after 24 hours and a rapid weight increase started after day 10 with a maximum on day 15.

Histologically, both types of treatment caused a strong lymphocytolysis in the germinal centre. In addition the irradiation resulted in a pronounced cytolysis in all parts of the follicles and in the perifollicular zones. After irradiation from day 10 to day 20 the histological picture of the spleen was totally dominated by the haemotopoiesis in the red pulp.

Steroid treatment at various times after irradiation resulted in a slight decrease of the spleen weight and adrenalectomy increased.

Peyers patches. After prednisolone treatment a pronounced cytolysis and phagocytosis of disintegrating cells were observed in the germinal centres. Few pycnotic cells were seen in the periphery of the follicles and in the interfollicular areas.

Radiation induced a pronounced cytolysis in all parts of the follicles including the germinal centres. Some pycnotic cells were also seen in the interfollicular areas, but most of these cells and the lymphoid cells in the stroma of intestinal villi were apparently intact.

Mononuclear cells in the peripheral blood.

The changes in the number of mononuclear cells in the peripheral blood are seen in Fig. 6. Prednisolone treatment caused a very short depletion and the normal level was reached after only 24 hours. After irradiation a pronounced depletion was observed from day 1 to 10 and by day 35 a significant reduction still remained.

A slight effect on the number of cells from adrenalectomy and steroid treatment in the regeneration phase could be seen.

Discussion

The morphology and the course of events in the steroid-induced and the radiation induced involution are well known (5, 10, 11, 13, 15, 16, 17).

With the fairly large doses of steroid or radiation used in this investigation, the first acute involution reactions were to a large extent similar. The small lymphocytes were within a few hours destroyed in the thymic cortex, and in the germinal centres of lymph nodes and spleen as well. In both cases the thymic medulla, parts of the paracortical areas of the lymph nodes and parts of the white and red pulp of the spleen were intact.

Compared to the steroid treatment, the irradiation resulted in a definitely more pronounced cytolysis of the small and medium sized lymphocytes in the follicles of the spleen, the Peyers patches, and in the subcapsular parts of the lymph node cortex.

In the steroid induced involution the parts of lymph nodes, spleen and Peyers patches which are described as thymus dependent (*Parrot et al.* 9) were mainly intact. In contrast, within a few days the irradiation resulted in a strong atrophy of these areas al-

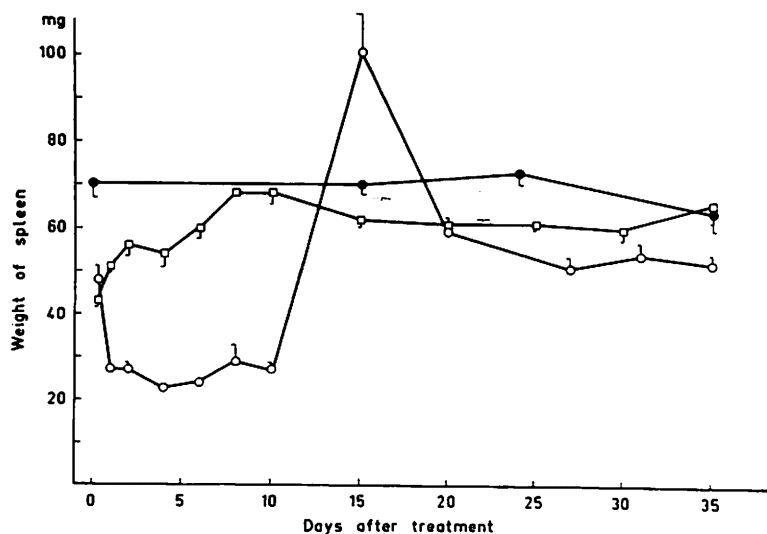


Fig. 5. The weight of the spleen after prednisolone or irradiation. Symbols as in Fig. 1.

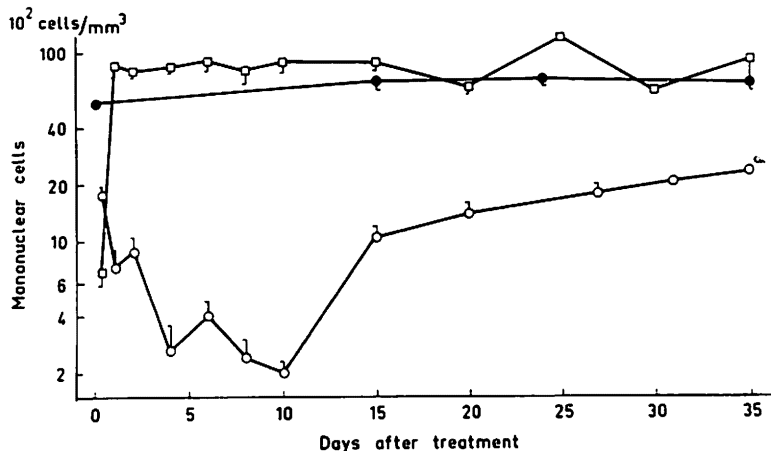


Fig. 6. The number of mononuclear cells in peripheral blood after prednisolone treatment and irradiation. Symbols as in Fig. 1.

though the acute cytotoxicity seen as pycnotic cells seemed to be less apparent. Thus, it is apparent that all the steroid sensitive cells were killed in the acute phase by the radiation, but in addition the radiation destroyed other cells in the spleen and lymph nodes. After irradiation compared to the steroid treatment the regeneration was much delayed with the exception of the first regeneration phase in the thymic cortex. Whether this difference depends on damage from the irradiation to a stem cell population, or/and to a more direct retardation effect on the cell proliferation within the lympho-

cyte compartment is not clear. However, the rapid regeneration of the thymic cortex in the first phase indicates a preserved cell proliferation capacity in this lymphocyte population.

The effect of prednisolone on the weight of lymph nodes and thymus during different phases of the radiation-induced involution, and the weight increase after adrenalectomy show that, except for the first acute involution phase, a steroid-sensitive population is present in the tissues. Part of the weight reduction is apparently dependant on a preserved, or an increased adrenal cortical function. A hyperfunction of the adrenal cortex after total irradiation, is reported by *Fleming et al.* (18). He observed a dose-related increase of corticosteroids in the adrenals and in the blood after roentgen irradiation. *Fedotov and Podzdnakov* (19) did not see an increase in the blood level of corticosteroids after 150 R, but observed a dependance of the radiation-induced involution on a preserved adrenal function. They assumed an increased sensitivity to the hormones of the lymphocytes injured by radiation.

The steroid-sensitive lymphocyte has been claimed to be more or less identical to the short-lived lymphocyte (*Esteban*, 20). However, according to *Everett et al.* (21) the cells circulating in the blood and lymph are to a large percentage long-lived. The rapid and pronounced disappearance of about 80% of the lymphocytes from the blood and thoracic duct lymph (*Lundin and Schooley*, 22) after steroid involution is hardly consistent with these statements.

One explanation could be that no definite correlation exists between the life-span of the cells and the steroid sensitivity. Thus the steroid sensitive cells may be either short-lived or long-lived.

Another explanation may be, that the disappearance of the lymphocytes after the steroid treatment does not depend on a lysis of the circulating cells, but on a redistribution of the cells to other compartments. The rapid restoration of the number of cells after steroid treatment may speak in favour of this view, but these findings do not exclude a mobilization of "resting" cells from some depots or release of cells newly formed in the lymphoid tissue.

The relationship between the short-lived lymphocyte pool and the radiation sensitivity is also a complex problem. Apparently the irradiation with 500 R destroys all the short-lived cells but does not prevent the rapid restoration of the cell proliferation capacity, judged from the first regeneration of the thymic cortex. However, the second involution of the thymic cortex and the prolonged atrophy in other parts of the lymphoid tissue show that the cell proliferation is more profoundly disturbed. This may depend on an injury to the stem cell compartment in the bone marrow or in the lymphoid tissue. These problems need further studies.

References

- 1 *Murray, R.G.*: The Thymus. In: *Histopathology of Irradiation from External and Internal Sources*. Chapter 9, p. 446. Edited by W. Bloom. Mc GrawHill Book Company, New York 1948
- 2 *Trowell, O.A.*: Radiosensitivity of the Cortical and Medullary Lymphocytes in the Thymus. *Int.J.Radiat.Viol.* 4 (1962) 163
- 3 *Selye, H.*: Thymus and Adrenals in the Response of the Organism to Injuries and Intoxications. *Brit.J.Exp.Path.* 17 (1936) 234-248
- 4 *Dougherty, T.F.*: Effect of Hormones on Lymphatic Tissue. *Physiol.Rev.* 32 (1952) 379-401

- 5 *Dougherty, T.F., M.L. Berliner, G.L. Schneebeli, D.L. Berliner*: Hormonal Control of Lymphatic Structure and Function. *Ann. N.Y.Acad.Sci.* 113 (1964) 825-843
- 6 *Dougherty, T.F., A. White*: Pituitary-Adrenal Cortical Control of Lymphocyte Structure as Revealed by Experimental X-irradiation. *Endocrinology* 39 (1946) 370-380
- 7 *Müller, J.F.A.P., G.F. Mitchell*: Thymus and Antigen-reactive cells. *Transplant.Rev.* 1 (1969) 3-46
- 8 *Miller, J.F.A.P., J. Sprent*: Cell to Cell Interaction in the Immune Response. *J.Exp. Med.* 134 (1971) 66-82
- 9 *Parrot, D.M.V., M. de Sousa, J. East*: Thymus Dependant Areas in the Lymphoid Organs of Neonatally Thymectomized Mice. *J.Exp.Med.* 123 (1966) 191-203
- 10 *Järplid, B.*: Radiation Induced Assymetry and Lymphoma of Thymus in Mice. *Acta Radiol.Suppl. No. 279* (1968)
- 11 *Lundin, P., U. Schelin*: The effects of steroids on the histology and ultrastructure of lymphoid tissue. II. Regeneration of the rat thymus after pronounced involution. *Path.Europ.* 4 (1968) 531-541
- 12 *Romets, B.*: *Mikroskopische Technik.* Leibniz Verlag, München 1948
- 13 *Craddock, C.G., A. Winkelstein, Y. Matsuyuki, J.S. Lawrence*: The Immune Response to Foreign Red Blood Cells and the Participation of Short-lived Lymphocytes. *J.Exp.Med.* 125 (1967) 1149-1172
- 14 *Congdon, C.C.*: The Destructive Effect of Radiation on Lymphatic Tissue. *Cancer Res.* 26 (1966) 1211-20
- 15 *Lundin, P.*: Anterior Pituitary Gland and Lymphoid Tissue Growth. *Acta Endocr. Kbh. Suppl.* 40 (1958)
- 16 *Ishidate, M., D. Metcalf*: The Pattern of Lymphopoiesis in the Mouse Thymus after Cortisone Administration or Adrenalectomy. *Austral.J.Exp.Biol.* 41 (1963) 637-649
- 17 *Smith, C., D.A. Kieffer*: Studies on Thymus of the Mammal. X. Regeneration of Irradiated Mouse Thymus. *Proc.Soc.Exp.Biol.Med.* 94 (1957) 601
- 18 *Fleming, K., B. Gellerstas, W. Henesing, U. Mannigel*: Strahlenwirkung und Nebennierenrinde. *Int.J.Radiat.Biol.* 14 (1968) 93-105
- 19 *Fedotov, V.P., A.L. Podzdnjakov*: *Radio-biologica* 8: 2 (1968) 305-307
- 20 *Esteban, J.*: The Differential Effect of Hydrocortisone on the Shortlived Small Lymphocyte. *Anat.Rec.* 162 (1968) 349-356
- 21 *Everett, N.B., R.W. Tyler*: Lymphopoiesis in the Thymus and other Tissues. *Internat.Rev. Cytol.* 22 (1967) 205-237
- 22 *Lundin, P., J. Schooley*: The Influence of Prednisolone on the Rat Thymus after Pronounced Involution. *Lymphology* 6 (1973) 90-97

Dr. P. Lundin, Institute of Pathology, University of Göteborg, Göteborg/Sweden