

- 15 Rake, P., H.P. Jones: Studies on lymphogranuloma venereum. I. Development of the agent in the yolk sac of the chick embryo. *J.Exp.Med.* 75 (1942)
- 16 Reeve, P., J. Taverne: Some properties of the complement-fixing antigens of the agents of trachoma and inclusion blenorhea and the relationship of the antigens to the developmental cycle. *J.Gen.Microbiol.* 27 (1962) 501
- 17 Reeve, P., J. Taverne: Observations on the growth of trachoma and inclusion blenorhea in viruses in embryonated eggs. *J.Hyg. Camb.* 61 (1963) 67
- 18 Schacter, J., M.G. Barnes, J.P. Jones, E.P. Engleman, K.F. Meyer: Isolation of bedsoniae from the joints of patients with Reiter's syndrome. *Proc.Soc.exp.Biol.Med.* 122 (1966) 283
- 19 Stewart, F.N., N. Treves: Lymphangiosarcoma in postmastectomy lymphedema. *Cancer* 1 (1948) 64
- 20 Storz, J.: Chlamydia and chlamydia-induced diseases. Charles C. Thomas, Springfield, Ill. 1971
- 21 Stryker, G.V., B. Ploch: Elephantiasis of the penis and scrotum: a sequela of lymphogranuloma inguinale. *Arch.Derm.and Syph.* (1933) 86
- 22 Sutton, G.C., J.A. Demakis, T.O. Anderson, R.A. Mortissey: Serologic evidence of a sporadic outbreak in Illinois of infection by Chlamydia (psittacosis-LGV agent) in patients with primary myocardial disease and respiratory disease. *Am.Ht.J.* 81 (1971) 597
- 23 Wang, S.P., J.T. Grayston: Egg infectivity assay of trachoma virus. *Proc.Soc.exp.Biol.Med.* 115 (1964) 587
- 24 Weinbren, M.P.: Report of the East African Virus Research Institute 1957-1958. East African High Commission Nairobi.
- 25 Whittle, R.J.M.: An angiosarcoma associated with an oedematous limb. *J.Fac.Radiol.* 10 (1959) 111

M. Elvin-Lewis, Ph.D., Chairman, Department of Microbiology, School of Dentistry, Washington University, St. Louis, Missouri 63110/U.S.A.

Mariys Witte, M.D., Charles Witte, M.D., Department of Surgery, J. Davis, M.D., Department of Pathology, University of Arizona College of Medicine, Tucson, Arizona 85724/U.S.A.

W. Cole, M.D., Department of Surgery, University of Missouri School of Medicine, Columbia, Missouri 65201/U.S.A.

Lymphology 6 (1973) 121-12
© Georg Thieme Verlag, Stuttgart

The Effect of Arterio-Venous Fistula on the Lymphatics

K.G. Callum, J.B. Kinmonth*

Department of Surgery, St. Thomas's Hospital Medical School, London, S.E. 1, England

Summary

Arterio-venous fistulae were made in young growing pigs and lymphography was performed before and at regular intervals after operation. Animals were sacrificed at periods of two to six months. Small but consistent increases in limb growth resulted, but there was no change in the lymphatic vessels or nodes on lymphography or histological examination.

*Requests for reprints should be addressed to Professor J.B. Kinmonth, Department of Surgery, St. Thomas's Hospital Medical School, London, S.E. 1

The alterations in limb circulation brought about by arterio-venous fistula formation did not produce any alteration in regional lymph pathways as measured by lymphography.

Introduction

In eight patients in whom arterio-venous fistula had been made for short limb of congenital origin (or of acquired disease such as epiphysitis which had occurred in early childhood) and in whom lymphography was performed, only one had normal sized regional lymph nodes compared with the normal limb (1, 2). In six the nodes were enlarged and in one child they appeared smaller than normal. It was impossible to tell whether these changes shown in the lymphograms had resulted from the arterio-venous fistula or from the factors which had caused the original limb deformities.

Children with multiple congenital arterious malformations in the limbs have also been found to have abnormalities of the lymph pathways (7).

Experiments were therefore done in animals to create an arterio-venous fistula and study the possible effect on the lymph vessels and nodes.

Methods

Experimental Animals

Pigs were used for this project because they are easy to handle and keep for a length of time, the lymph vessels are large and easy to cannulate on a number of different occasions and the lymph nodes are clearly seen on lymphangiograms.

The animals were of the "large white" variety, four were females and two were males. At the time of operation they were 4-8 weeks old and weighed 10-20 kg.

They have three to six afferent lymphatics from the legs which drain to the superficial inguinal lymph nodes which consist of one or two large and several small nodes which form a conglomerate mass (Fig. 1 and 2). These nodes also drain from the anterior abdominal wall and lower tunk. From these nodes, usually, two large and a few small efferents pass to the external and internal iliac lymph nodes in the pelvis, and thence to the lumbar lymph nodes and trunks (Figs. 1-4).

Anaesthesia

Premedication was obtained using 0.5-3 ml of "Suicalm" (Azaperone, Janssen Pharmaceutica, Belgium) and anaesthesia was induced and maintained with Halothane, Nitrous Oxide and Oxygen. A cone shaped rubber mask was used which was strapped on the head, and this method of anaesthesia was found to be very satisfactory.

Lymphography

Lymphograms were performed before the operation to create an arteriovenous fistula, and at monthly intervals thereafter, because it was found that the contrast medium was cleared from them by a month. In each case lymphadenograms were taken 3-5 days later.

Each lymphographic injection had to be done under general anaesthesia. Patent blue violet 2.5% was injected subcutaneously into the dorsum of the hind foot. The lymph vessels were visible through the skin, and were easily exposed via a longitudinal incision about 1/2" long on the dorsum of the foot. The lymph vessels were cannulated using a St. Thomas's Hospital pattern lymphangiogram set (3)

Ultrafluid lipiodol in a dose of 0.25 ml/kg was injected (4), half the dose being given on each side, using a Lund constant rate injector (5) at a rate of 1 ml every 15 minutes.

Assessment of any change in the lymphatics was by naked-eye assessment, and by planimetry of the lymphadenograms (tracing the nodes on X-ray film and measuring the area by counting squares on graph paper.

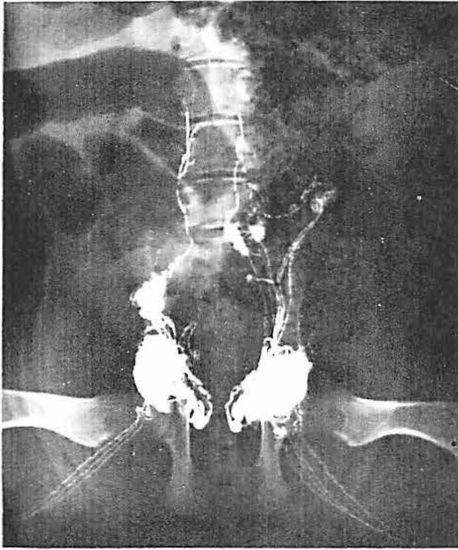

Fig. 1. Lymphangiogram before operation, showing normal anatomical arrangement of lymph vessels and nodes (animal No. 5)

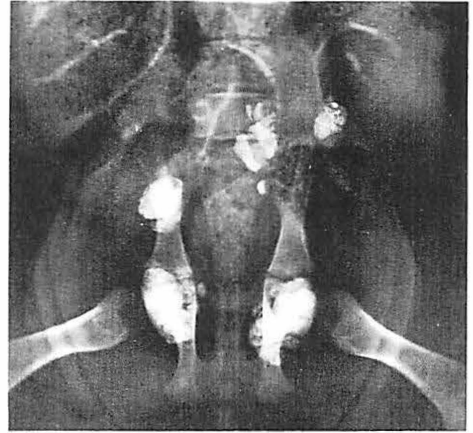


Fig. 3. Pre-operative lymphadenogram taken 3 days after the lymphangiogram shown in Fig. 1 (same animal), showing typical normal arrangement of inguinal and iliac lymph nodes.

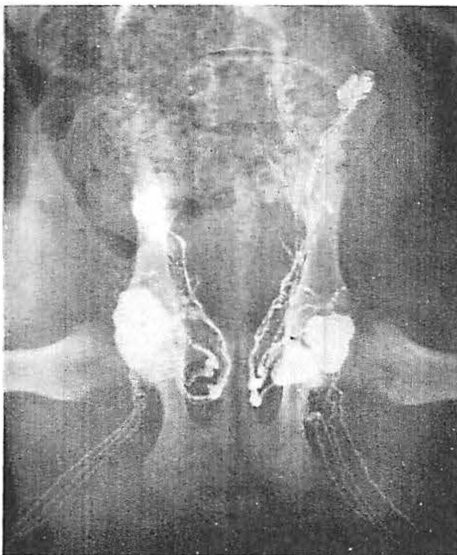


Fig. 2. Lymphangiogram of the same animal as Fig. 1, taken 9 weeks after formation of an iliac arterio-venous fistula on the left side. The Cushing's clip marks the site of the fistula. As can be seen, there is no significant difference between Figs. 1 and 2.

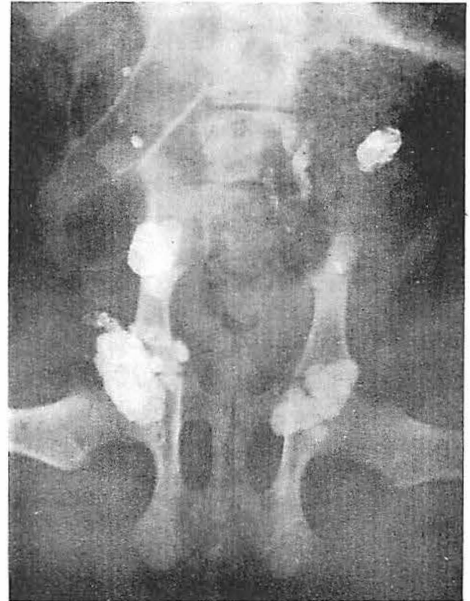

Fig. 4. Lymphadenogram taken 3 days after the lymphangiogram shown in Fig. 2, i.e. 9 weeks after formation of iliac arterio-venous fistula (same animal). Again, there is no significant difference between Figs. 3 and 4.

Operative technique

Initially a fistula was made between the femoral artery and vein as the surgical approach was convenient and because this was in the same anatomical area as the operation performed in the children. Patent blue violet was injected into the feet to demonstrate the lymphatic vessels so that they could be avoided. The blood vessels were mobilised and controlled, and soaked with Papaverine to counteract spasm (6) and then measured. Heparin 2,000 units was given and a side to side anastomosis performed using 8/0 monofilament nylon (Ethicon). The Heparin was reversed at the end of the operation. The vessels measured 3-5 mm in diameter and the stoma was about 5 mm long. On the other side a control operation was performed, when the blood vessels were mobilised in a similar fashion but no fistula was made.

Four femoral fistula operations were performed but in three the fistula closed spontaneously between 1-3 weeks after the operation, and at post-mortem the vein was found to be fibrosed.

In view of the high failure rate of fistulae in the femoral vessels, fistulae were made instead in the external iliac vessels. Again patent blue violet was injected into both legs to aid preserving the lymphatic vessels. The iliac artery and vein were approached extra-peritoneally via a paramedian incision. The vessels were 4-6 mm in diameter and a side-to-side anastomosis was performed with a stoma of 1 cm. A control operation was performed on the other side via the same incision. The external iliac vessels were exposed by carefully pushing away the peritoneum. They were mobilised as on the other side but no fistula was made.

The iliac operation upset the animals much more than the femoral operation and they usually took 2-3 days to recover, but all the fistulae remained patent for the duration of the experiments (2-5 months).

Patency of the Fistula

Patency of the fistula was confirmed by listening for the characteristic murmur with a stethoscope. Initially this was done daily and later once or twice a week. Further confirmation was obtained by performing a translumbar aortogram and finally at post-mortem examination.

Measurement of limb growth

Each time the monthly lymphogram was performed the limbs were measured for length and thickness. The anaesthetised animals were placed supine with the limbs extended and strapped to the table, great care being taken to get the limbs symmetrical. Lengths were measured from the tuber coxae (equivalent of the anterior superior iliac spine in man) to the medial malleolus, and from the tip of the hoof of the heel, knee and mid-groin. In addition, the girth of the pelvic limb was measured with a caliper at exactly equivalent sites at the level of the knee joint on each side.

At post-mortem the individual bones were measured, and in addition, corresponding bones, that is left and right femur and left and right tibia and fibula, were X-rayed side by side while placed in exactly the same manner, and these were measured on the X-ray plate.

Histological Study of the Lymph Nodes

At post-mortem the inguinal and iliac lymph nodes were removed for histology. Sections were studied by the authors and in addition by a pathologist who did not know on which side the fistula had been made.

Results

A total of 16 animals were studied. Some animals had as many as five general anaesthetics and operations when the lymphographies were included so that some sixty operations under general anaesthesia were necessary in total.

It was found that fistulae made between the femoral vessels had a high rate of spontaneous closure. Three of four made side to side closed in two weeks and all of five made end to end closed within three weeks. These findings have interesting haemodynamic and other aspects but are outside the scope of the present paper.

Only animals in which a stable fistula was achieved were retained for analysis in the table. In these, conditions had stabilized and no further changes were seen on repeated lymphographies. They were therefore sacrificed at periods of two to six months after the fistula had been made.

Repeated lymphographies under general anaesthesia result in deterioration of the animals so that longer periods of study, besides being unnecessary, were undesirable.

The table shows the site of the fistula in each animal and the duration of study following fistula formation. The difference in length of the limb on the operated side compared with that on the normal side is given. The length was the same in two animals, and the side with the arteriovenous fistula was 0.5-1.5 cm longer in the remaining four. The increase in length of the disarticulated femurs and tibias was less marked, but the bones on the operated side were consistently 2-3 mm longer than on the control side.

Table. Site and duration of fistula, and effect on limb growth and lymphatics

Animal in Series	Site of Fistula	Length of Follow-up	Effect on Growth of Operated Limb compared with Normal Limb Length		Effect on Lymphatics
				Girth at knee	
1	Right Femoral	6 months	=	+ 1 cm	No change
2	Right Iliac	5 months	+ 1.5 cm	+ 8 cm	No change
3	Left Iliac	11 weeks	+ 1 cm	+ 1 cm	No change
4	Right Iliac	8 weeks	=	+ 1 cm	No change
5	Left Iliac	9 weeks	+ 0.5 cm	+ 1.5 cm	No change
6	Left Iliac	9 weeks	+ 1 cm	+ 1 cm	No change

The Table also shows the girth, or transverse diameter at the knee, as measured with calipers, and in all cases there was an increase of 1 cm or more on the operated side. In one animal (No. 2) the increased thickness was very marked, and it was felt that this was because he was followed up for the longest of those with an iliac fistula (5 months). The increase in growth was less marked in the animal with a femoral fistula (No. 1), even though he was followed for six months.

All the animals developed visible dilated superficial veins on the limb on the operated side. Again this was very marked in animal No. 2 and only slight in the animal with the femoral fistula.

In all the animals repeated lymphangiograms failed to show any difference in the size or character of the lymphatic vessels, as illustrated by Figs. 1 and 2, which show lymphangiograms before operation and nine weeks after (animal No. 5). Similarly the lymphadenograms failed to show any obvious differences in size or character, and on measuring the total area of the lymph nodes on each side on the radiographs, those on the operated side were, if anything, marginally smaller than on the control side. Figs. 3 and 4 are lymphadenograms which correspond to the lymphangiograms shown in Figs. 1 and 2 and there is no evidence of any change in the nodes as a result of the arterio-

venous fistula. Even in the animals who were followed for 5 and 6 months after formation of a fistula there was no detectable change in the size or character of the lymphatic nodes or vessels. Nor was there any difference when inguinal nodes below and pelvic nodes above the fistula were compared separately with those of the opposite side.

Similarly, histological examination of the excised lymph nodes did not show any detectable differences between the side with the fistula and the control side in any of the animals.

Conclusion

The increase in limb size on the side of operation shows that the arterio-venous fistulae were exerting an effect on limb growth. However, there was no evidence of any increase in size or alteration in character of the lymph vessels or nodes on lymphography, nor was there any histological change in the nodes.

It is therefore concluded that the reported alterations in the lymph nodes of patients with short limbs who had arterio-venous fistulae created to stimulate the growth of the limb were due to the original abnormalities in the limbs, and not to the fistulae. The same is probably true of children with congenital arteriovenous fistulae and associated lymphatic changes.

Acknowledgements

We would like to thank the technical staff of the Surgical Unit for all their help in this study, and especially Miss Bronwen Humphreys who acted as assistant to the project, and Dr. B. Corrin who examined the histological specimens.

References

- 1 *Kinmonth, J.B., D. Negus: Arterio-venous Fistulae in the Management of Lower Limb Discrepancy. Awaiting publication. 1973*
- 2 *Kinmonth, J.B., D. Negus: Lymphography in Children with Arteriovenous Fistulae made for limb discrepancy. (1972) Unpublished data.*
- 3 *Rutt, D.L., M.H. Gough, J.B. Kinmonth: Disposable lymphangiography set. Lancet I (1964) 475*
- 4 *Guiney, E.J., M.H. Gough, J.B. Kinmonth: Lymphography with fat soluble contrast media. J.Cardiovascular Surgery (Torino) 5 (1964) 346*
- 5 *Clementz, S., T. Olin: Apparatus for controlled infusion of saline in angiography and contrast medium in lymphography. Acta Radiol. (Stockholm) 55 (1961) 109*
- 6 *Kinmonth, J.B.: Surgical Physiology of Large Arteries with particular reference to traumatic arterial spasm. Brit.Med.J. 1 (1952) 59*
- 7 *Kinmonth, J.B.: The Lymphatics: Diseases, lymphography and surgery. Arnold, London 1972*

K.G. Callum, M.B., FR CS, J.B. Kinmonth, M.S., FR CS., Department of Surgery, St. Thomas's Hospital Medical School, London S.E. 1/England