

**Pacinian Corpuscles\* and their Relationship to the Lymphatic System****G. Fabian**

Department of Anatomy, Ruhr-University, Bochum, Germany

**Summary**

By means of well-proven methods of investigation the Pacinian corpuscles in the meso-jejunum of the cat were injected with vital stains (patent blue violet and Japanese ink), and the transport of dyestuffs through the lymphatic system established.

Observations in the literature regarding the lymphatic pathways, which have close relationships with the sensory end-organs, have hitherto been very scanty. This was probably because they were never the main subject of any research project, or else no observers were prepared to commit themselves owing to the rather meagre possibilities of demonstration.

On the basis of these facts an effort has been made to establish something definite, by means of a new and already proven injection technique using intra-vital stains.

**Literature**

Our present day knowledge regarding the form and structure of the mechanoreceptors is to a great extent the outcome of classical methods of examination viz. light microscopy, and also, more recently electronmicroscopy. The problems which were presented in the assessment of the morphological and structural factors, by a classification of the receptors on the basis of numerous variations and transitional forms, were defined by *Stöhr* (37) and *Kantner* (16), amongst others. A classification of the mechano-receptors was also attempted by *Stach*, *Fanghänel* and *Schultz* (36), who found three types of sensory endings. Also, *Jabonero* and *Moya* (15) described three main types, among which in addition the Pacinian corpuscles were included.

More recently, *Halata* (12) in referring to this has undertaken a classification of the mechano-receptors in which he also makes a distinction into three types, on the basis of the endings, structure and localisation. However, the Pacinian corpuscles are not separated here, but they belong to Type III.

Further discussion of the Pacinian corpuscles emerges from this, in that it includes the large Pacinian corpuscles incorporated in the *Halata* (12) Type III, which were discovered in 1741 by *Vater* and again found by *Pacini* in 1835, but not the small, simple, encapsulated Pacinian corpuscles which are likewise associated with this group. As has been declared by *Watzka* (41), among the very polymorphous nerve end-organs the lamellated corpuscles, including again the Pacinian corpuscles, occur the most abundantly. They are the largest (40) and are found everywhere in the organism, among other sites being the mesentery in the neighbourhood of the pancreas or around the joints (31). Their existence has also been confirmed by other authors (3, 4, 6, 19, 25, 33, 39).

The Pacinian corpuscles are slightly flattened, oval structures, which can attain a length of 4 mm and a thickness of 2 mm (1). The nerves of supply lose their myelin sheath as they enter the corpuscles and run through the inner core as an unmyelinated strand (19). Their most striking structural feature are the concentric lamellae, up to sixty in number, which surround the inner core, and between which there is a protein-containing fluid (1, 2, 3, 30, 22). This also explains more definitely the well-known change in shape of the Pacinian corpuscles produced by swelling, as mentioned by *Schwarz* (34).

\* In Germany, and elsewhere on the continent these are often referred to as Vater-Pacinian corpuscles.

Each lamellated corpuscle is supplied by blood capillaries (1, 2, 3, 4, 19, 20, 22, 27, 35), in such a way however, that the inner core is always free of vessels (4, 30).

With regard to the lymphatic pathways of the nerve endings (corpuscles) there are contributions from, amongst others *Key* and *Retzius* (17) and *Rauber* and *Kopsch* (30), concerning Pacinian corpuscles in man. According to these the lymphatic pathways were represented by fine clefts between the perineural lamellae, but not throughout the capsular space.

In the neighbourhood of the Pacinian corpuscles *Loeschke* (22) found strikingly numerous and extensive lymphatic vessels, which often showed a particularly thick wall and sometimes clung closely to the corpuscles. In the cases where a strong protein precipitate was visible in the clefts there was often found in the surrounding lymph vessels a similarly stained, but seemingly homogeneous mass of protein.

The function of the Pacinian corpuscles is not yet definitely established (39). An opposite view expressed by *Krüger* (20) is that the corpuscles work as a "lymph-organ". The Pacinian corpuscles may record pressure stimuli (20, 41) and vibration stimuli (1, 4, 20, 24, 28, 29, 32), and thus possibly play a part in blood pressure regulation (4, 22). According to *Seiferle* (35) the Pacinian corpuscles of the mesentery function as mechanoreceptors for deep sensibility, which react to traction and pressure and regulate the normal blood circulation of the stomach and intestinal tract.

### Material and Methods

From an extensive material, we obtained Pacinian corpuscles from the abdominal cavity of a freshly killed female cat, about 1 1/2 years old. We made use of the previously used injection technique (8, 9, 10, 11) with a 2.5% patent blue violet solution\* and with an Japanese ink suspension. Immediately after opening the abdomen the injection was made with an extremely fine cannula under the stereo-microscope, into the Pacinian cor-

puscles present in the meso-jejunum, and indeed, occasionally injections were made into the different portions of it — proximal, intermediate and distal. After the injection of the dye, on the surface of the corpuscles and in their neighbourhood, very fine formations of varying sizes became apparent, looking like strings of pearls, while at the same time an outflow of the dye was observed.

### Results and Discussion

The Pacinian corpuscles present in the mesentery are generally quite numerous. They are increased however in the cranial portion of the meso-jejunum where they can be found on both sides in intimate relationship to the whole length of the jejunal arteries.

The Pacinian corpuscles, which were particularly large and very prominent in this animal had the shape of a rotation ellipsoid. The measurements of 4 mm long and 2 mm thick given in the literature as maximal (1) were exceeded here by several corpuscles. Some were found with a length of 6.8 mm, in which the quoted average width of two-thirds the length, varied widely. These large corpuscles stood out particularly strongly. They appeared bluish translucent with, in their long axis, the centrally lying white inner core with its surrounding lamellae (Fig. 1). The structure of all Pacinian corpuscles is basically the same, although according to *Krüger* (21) all the corpuscles seen in the cat differ from those of man in shape and structure, although this question will not be gone into here. According to *Krüger* (20), to the already-mentioned constituent parts, such as the nervous inner core with its surrounding lamellae, one must also add the blood supply, which however, is characterized and confirmed as being very scanty.

The peripheral boundary of the Pacinian corpuscle is the outermost lamella of the whole lamellar system and this is designated by *Krüger* (20) the capsular lamella. It is two to three times stronger than the remaining lamellae. As one moves further from the centre the lamellae are arranged in layers like an onion-skin. Each two lamellae form an encapsulated cavity filled with fluid. According to *Bargmann* (1) a lamella consists of

\* From the Byk-Gulden Co., Konstanz

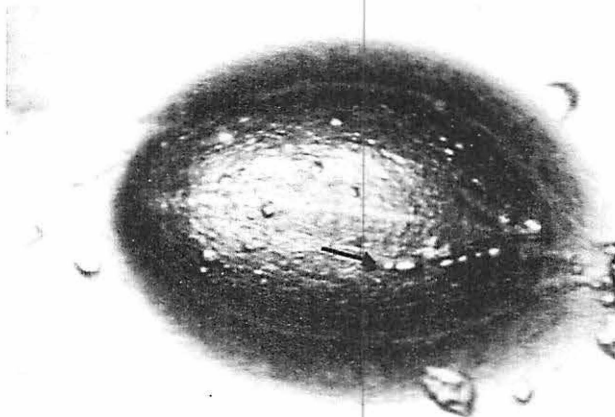


Fig. 1: Pacinian corpuscles from the meso-jejunum of a cat. N.B. the lymph capillaries coursing over the surface (arrow), the arrangement of lamellae and the central core.

the juxtaposition of the outer wall of the cavity with the inner wall of the next cavity. The cavity of the capsule holds fluid and can be emptied by puncture with a fine needle.

With very tightly filled Pacinian corpuscles, vessels appear on their surface and in the surroundings, which, at repeated short intervals show a spontaneous, rhythmic pattern of movement in the periphery, similar to the findings in lymph vessels, which have already been described by *Heller* (13), *Kinmonth* and *Taylor* (18), *Witte* and *Schricker* (42), *Horstmann* (14), *Mislin* (23) and *Fabian* (9). With the injections of patent blue violet into the outermost lamellar system there follows immediately a migration of dye in the proximal section, solely in the direction of the stalk. As a result of this immediate migration of dyestuff, vessels such as capillaries, which previously were not detectable at all, become visible. It is well-known that patent blue violet has an affinity for the lymphatic system. Therefore, without any doubt, it may be that this phenomenon involves transport by the lymphatic vessels. Also if an injection is given into the innermost lamellar layer in the vicinity of the inner core, in the proximal portion, there immediately follows a migration in the direction of the stalk. Injections into the outermost lamellar layer and the inner lamellar system near the central core allow one to detect a migration of dye over the anterior portion of the Pacinian corpuscle (Fig. 2) and likewise in the direction of the stalk. With injections into the distal part of

the corpuscle there follows a migration distally and also in a proximal direction over the stalk.

If one punctures a tightly filled corpuscle with a fine cannula, it can be emptied and made to collapse completely and in this way at the same time the fluid removed can be replaced by patent blue violet solution. With increasing pressure the dye distributes itself evenly throughout the entire corpuscle, regardless of whether the puncture was made more peripherally or more centrally. A blue colouration of the vessels and capillaries is seen immediately in the entire surroundings of the Pacinian corpuscle, and this in addition moves from the surface of the corpuscle into the periphery. Here also there has been, without doubt, a migration of the dyestuff in the lymphatic vessels.

Although *Loeschke* (22) was also able to inject the Pacinian corpuscles with Chinese ink, he was nevertheless unable to demonstrate any efferent drainage pathways. However, he stressed that lymph vessels, conspicuous both in number and extent existed in their neighbourhood. In contrast to these statements, injections of Japanese ink were also undertaken, in which the results were similar to those obtained with the patent blue violet injections, although here there was a slightly delayed migration of the material into the lymphatic system. In addition the migration of the dyestuff proceeded very irregularly and very diffusely through the more or less huge groups of the jejunal lymph nodes.

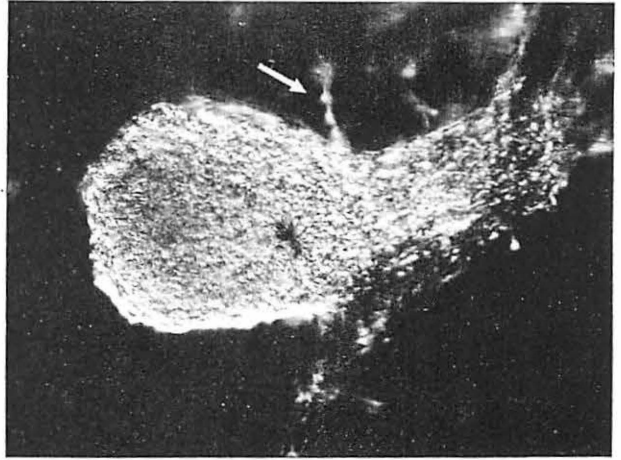


Fig. 2: Pacinian corpuscles after injection of Japanese ink, with efferent lymph capillaries, extending to the periphery. Here, the "string of pearls" appearance is already visible (arrow).

The very rapid, uniform migration of the dye within the Pacinian corpuscles was explained as follows. *Dogiel* (7) suggested that the lamellae of the corpuscles contain tiny openings, through which the fluids are able to pass, a view which once again has not remained unchallenged (6). An effort was likewise made to inject with Japanese ink the peripheral lymphatic vessels which had been delineated by the injection of patent blue violet into the Pacinian corpuscles, which repeatedly succeeded after breaking down the individual valves. In this way a filling of the corpuscle was achieved, with a simultaneous escape of the ink peripherally into the lymph capillaries and vessels previously outlined with blue.

In the light of the foregoing results one may express the following conclusions: The injections of Pacinian corpuscles in the meso-jejunum of the cat, with patent blue violet and Japanese ink enable one to recognize a relationship between the corpuscles and the lymphatic system of the surrounding area. The efferent lymph capillaries from the Pacinian corpuscles are present, even although they are hidden from sight, because when they are empty they are able to collapse completely. However, when they are full they are very distensible and can easily be recognized.

On the basis of electron-microscopical studies *Casley-Smith* (5) arrived at the theory which is accepted at the present time, according to which lymph originates from the tissue fluids. As the starting point of his demonstration he

regards as important the collapsed, closed-off lymph capillaries which end in the clefts in the tissues (intercellular space, interstitium). If particular processes then lead to increased circulation and raised permeability of the blood capillaries, there is a rise in the tissue fluid content. Other processes can also lead to an increase in water filtration in the tissues and thereby lead to them swelling.

From the morphological aspect the great enlargement of the Pacinian corpuscles in this instance, is comparable to their demonstration by injection. The reticular fibres, which are anchored to the lymph capillaries in the surrounding connective tissue, pull the endothelial cells apart and thus open up the lymph capillaries. Apart from this the capacity for permeability is greater in the lymph capillaries than in the blood capillaries, as in the former the basement membrane is either discontinuous or absent.

In summary, it can be explained as follows, viz. that a migration of fluid from the Pacinian corpuscles occurs into the lymph capillaries or vessels of the surroundings and, more distally, into the corresponding lymph nodes. *Loeschke* has confirmed the above findings by comparable observations.

#### References

- 1 *Bargmann, W.*: Histologie und mikroskopische Anatomie des Menschen. 6. Aufl. Georg Thieme Verlag, Stuttgart 1967
- 2 *Benninghoff, A.*: Lehrbuch der Anatomie des

- Menschen. 2. Band, 2. Teil. Urban & Schwarzenberg. Berlin-München-Wien 1946
- 3 *Boeke, J.*: In: *L. Bolk, E. Göppert, E. Kallius, W. Lubosch*: Handbuch der vergleichenden Anatomie der Wirbeltiere. 2. Band, 2. Hälfte. Urban & Schwarzenberg. Berlin-Wien 1934
  - 4 *Bucher, O.*: Histologie und mikroskopische Anatomie des Menschen. 4. Aufl. Medizinischer Verlag Hans Huber. Bern und Stuttgart 1965
  - 5 *Casley-Smith, J.R.*: The fine structure, properties and permeabilities of the lymphatic endothelium. *Experientia* (Basel), Suppl. 14 (1967) 19
  - 6 *Clara, M.*: Über den Bau des Schnabels der Waldschnecke (*Scolopax rusticola* L.). *Zschr. mikr.-anat. Forsch.* 3 (1925) 1
  - 7 *Dogiel, A.S.*: Zur Frage über den Bau der Kapseln der Vater-Pacinischen und Herbstschen Körperchen und über das Verhalten der Blutgefäße zu denselben. *Fol. neuro-biol.* 4 (1910) 218
  - 8 *Fabian, G.*: Zur Darstellung der Lymphkapillaren mittels Patentblau-Violett und Tusche. *Berl. Münch. Tierärztl. Wschr.* 82 (1969) 113
  - 9 *Fabian, G.*: Zur Aufnahme des Vitalfarbstoffes Patentblau-Violett und von japanischer Tusche in die Lymphkapillaren der Darmzotte. *Zbl. Vet. Med. A*, 19 (1972) 52
  - 10 *Fabian, G.*: Experimentelle Untersuchungen über die enterale Resorption des Vitalfarbstoffes Patentblau-Violett und von Japanischer Tusche. *Z. Angew. Zool.* 59 (1972) 17
  - 11 *Fabian, G.*: The Lymphatic Vessels of the Uterus during the Sexual Cycles of the Mice. *Lymphology* 9 (1976) 78
  - 12 *Halata, Z.*: The Mechanoreceptors of the Mammalian Skin. Ultrastructure and Morphological Classification. Ergebnisse der Anatomie und Entwicklungsgeschichte. Vol. 50. Fasc. 5. Springer-Verlag. Berlin-Heidelberg-New York 1975
  - 13 *Heller, A.*: Ueber selbständige rhythmische Contractionen der Lymphgefäße bei Säugethieren. *Z. med. Wiss.* 7 (1869) 545
  - 14 *Horstmann, E.*: Die Motorik der Lymphgefäße. *Europ. Konf. Mikrozirkulation.* Hamburg 1960. *Bibl. anat.* 1 (1961) 306
  - 15 *Jabonero, V., J. Moya*: Studien über die sensiblen Endausbreitungen. *Acta anat.* 78 (1971) 488
  - 16 *Kantner, M.*: Neue morphologische Ergebnisse über die peripherischen Nervenausbreitungen und ihre Deutung. *Acta anat.*, Basel 31 (1957) 397
  - 17 *Key, A., G. Retzius*: Studien in der Anatomie des Nervensystems und des Bindegewebes. Bd. 2. Stockholm: Samson and Wallin, 1876
  - 18 *Kinmonth, J.B., G.W. Taylor*: Spontaneous rhythmic contractility in human lymphatics. *J. Physiol. (London)* 133 (1956) 3 P
  - 19 *Krölling, O., H. Grau*: Lehrbuch der Histologie und vergleichenden mikroskopischer Anatomie der Haustiere. 10. Aufl. Paul Parey Verlag, Berlin und Hamburg 1960
  - 20 *Krüger, H.*: Über die Vater-Pacinischen Körperchen der Baucheingeweide der Katze. *Anat. Anz.* 109 (1961) 311
  - 21 *Krüger, H.*: Ein weiterer Beitrag zur Kenntnis der Vater-Pacinischen Körperchen (VPK) der Katze. *Anat. Anz.* 114 (1964) 408
  - 22 *Loeschke, H.H.*: Gefäßapparat und Lymphbahnen der Vater-Pacinischen Lamellenkörperchen des Menschen. *Z. mikrosk.-anat. Forsch.* 39 (1936) 315
  - 23 *Mislin, H.*: Experimenteller Nachweis der autochthonen Automatie der Lymphgefäße. *Experientia* 17 (1961) 29
  - 24 *Munger, B.L.*: Patterns of organisation of periphery sensory receptors. In: *Principles of Receptor Physiology*, p. 523-556. Ed. W. Loewenstein. Springer, Berlin-Heidelberg-New York 1971
  - 25 *Nickel, R., A. Schummer, E. Seiferle*: Lehrbuch der Anatomie der Haustiere. 4. Band. Verlag Paul Parey, Berlin und Hamburg 1975
  - 26 *Pacini, F.*: Sopra un particolare genere di piccoli Corpi globulosi scorpeti nel corpo umano da Filippo Pacini Aluno interna degli spedali riunti di Pistoia. - Letter to Accademia Medico-fisica di Firenze 1835
  - 27 *Pallie, W., K. Nishi, C. Oura*: The Pacinian corpuscle, its vascular supply and the inner core. *Acta anat.* 77 (1970) 508
  - 28 *Quilliam, T.R.*: Structure of receptor organs. Unit design and array patterns in receptor organs. In: *Touch, heat and pain.* Ciba Found. Symp., p. 86-116. I. & A. Churchill Ltd., London 1966
  - 29 *Quilliam, T.R., J. Armstrong*: Mechanoreceptoren. *Endeavour* 12 (1963) 55
  - 30 *Rauber, A., Fr., Kopsch*: Lehrbuch der Anatomie des Menschen. 8. Aufl., 6. Abtlg. Georg Thieme Verlag, Leipzig 1909
  - 31 *Reith, E., H. Ross*: Atlas der Histologie und mikroskopischen Anatomie. F.K. Schattauer Verlag, Stuttgart-New York 1974
  - 32 *Schmidt, R.F.*: Möglichkeiten und Grenzen der Hautsinne. *Klin. Wschr.* 49 (1971) 530
  - 33 *Schumacher, S. v.*: Beiträge zur Kenntnis des Baues und der Funktion der Lamellenkörperchen. *Arch. mikrosk. Anat.* 77 (1911) 157
  - 34 *Schwarz, W.*: Elektronenmikroskopische Untersuchungen am Außenkolben der Vater-Pacinischen Körperchen. *Z. f. Zellforschung u. mikrosk. Anat.* 36 (1951) 436
  - 35 *Seiferle, E.*: Nervensystem, Sinnesorgane, Endokrine Drüsen. In: *Nickel, R., A. Schummer, E. Seiferle*. Lehrbuch der Anatomie der Haustiere. 4. Band. Paul Parey Verlag, Berlin und Hamburg 1975
  - 36 *Stach, W., J. Fanghänel, E. Schultz*: Afferente Terminalorgane in der Wand der Harnblase verschiedener Laboratoriumstiere und ihre Topographie. *J. neurovisc. Relat.* 31 (1968) 26
  - 37 *Stöhr, Ph., jr.*: Mikroskopische Anatomie des vegetativen Nervensystems. In: *W. von Möllendorff und W. Bargmann*: Handb. d. mikr. Anat. d. Menschen. Vol. IV/V. Springer, Berlin-Göttingen-Heidelberg 1957
  - 38 *Vater, A.*: Dissertation de consensu partium corporis humani. Haller, Disputationum anatomicarum selectarum, vol. II, Gottingae 1741
  - 39 *Voss, H., G. Geyer*: Grundriß der normalen Histologie und mikroskopischen Anatomie. 13. Aufl. VEB Georg Thieme, Leipzig 1968
  - 40 *Waldeyer, A.*: Anatomie des Menschen, 1. Teil, 2. Aufl., Walter de Gruyter & Co., Berlin 1953
  - 41 *Watzka, M.*: Kurzlehrbuch der Histologie und mikroskopischen Anatomie des Menschen. 5. Aufl. F.K. Schattauer Verlag. Stuttgart-New York 1974
  - 42 *Witte, S., K.Th. Schricker*: Mikroskopische Lebensbeobachtungen an Lymphgefäßen. *Verh. dtsh. Ges. inn. Med.* 66 (1960) 572

Priv.-Doz. Dr. Gerda Fabian, Department of Anatomy, Ruhr-University, D-4630 Bochum, Germany