

The Value of Lymphangiography in Chyluria: A Report of three Cases.

B. Morag, M. Hertz, Z.J. Rubinstein

Department of Diagnostic Radiology, Chaim Sheba Medical Centre, Tel Hashomer, Israel.
 Affiliated to the Tel-Aviv University Sackler School of Medicine

Summary

The lymphographic findings in three patients suffering from idiopathic chyluria are described. These findings included lymphangiectases and retrograde filling of kidney lymphatics; bilaterally in two and unilaterally in one patient. In the latter patient, the contrast was also seen entering the renal calyces and pelvis before passing to the bladder. The thoracic duct was patent in all three cases. The value of lymphangiography in patients with chyluria is emphasized.

Introduction

Chyluria is characterized by the appearance of lymphatic fluid in the urine with abnormal communication between the lymphatic vessels and the urinary tract (1, 2). Most cases result from parasitic infestation, but in many instances the cause cannot be demonstrated (1).

Lymphangiography (LAG) is a valuable examination for determining (a) whether the lymph nodes are normal, (b) patency or otherwise of the lymphatic ducts and (c) to localize the site of the fistula (1).

This report describes the lymphographic findings in three patients with chyluria in whom no etiology could be determined.

Method of Examination

Using a standard technique, 8-10 cc of contrast material was injected into the lymph vessels of each foot. In these cases of chyluria films of the abdomen were obtained on completion of the injection, every two hours for ten hours following the injection, and again on the day after the examination.

The early exposures were made to demonstrate the lymph vessels to the kidney and the possible passage of the contrast media into

the collecting system. Those made on the following day were for the demonstration of the lymph glands.

Case Reports

(1) A 35 year old woman from India who had emigrated to Israel when she was approximately 20 years of age. She had noted "milky" urine for four years before admission which was shown to be chyluria. The chyluria was of an intermittent nature and was accompanied by backache. These attacks lasted for a period of a few weeks, subsiding spontaneously. The last of her four pregnancies, two years prior to

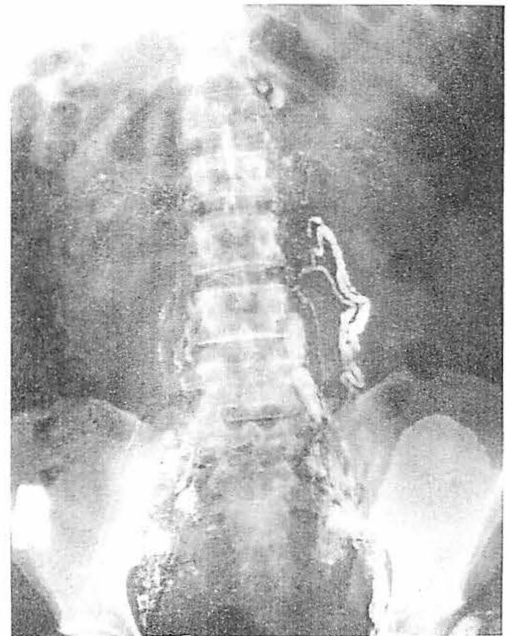
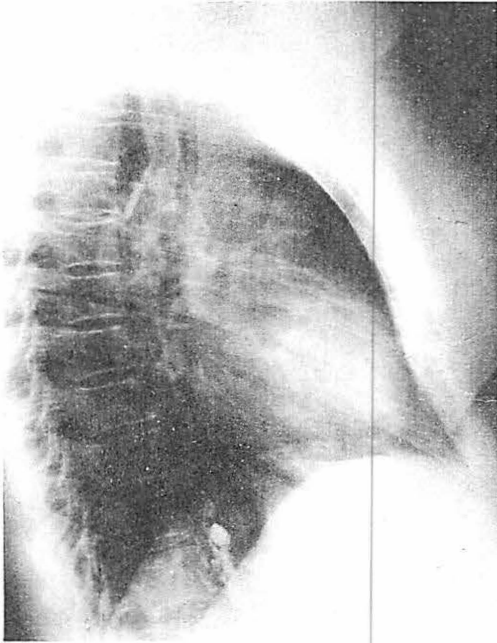
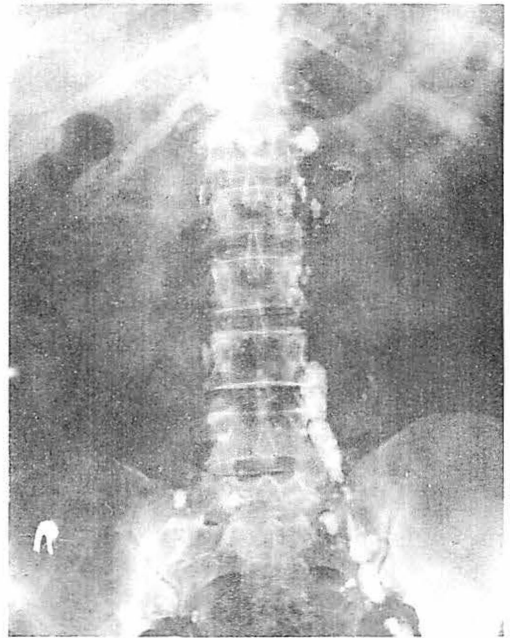


Fig. 1: Case 1.
 a. Early phase showing lymphangiectasis and filling of lymphatics to both kidneys.



b. Lateral chest film demonstrating patent and dilated thoracic duct.



c. On 24-hour film — note paucity of lymph glands especially on the right side.

admission, had been associated with diabetes which spontaneously disappeared after delivery.

Excretory urography was normal and was followed by lymphography. The initial films taken on completion of the injection showed dilated tortuous lymphatic vessels and small cysts in several areas (Fig. 1a). This lymph-angiectasis was present in the pelvis as well as in the abdominal lymphatics. Lymph vessels were also demonstrated in both kidneys in a delicate reticular pattern. The thoracic duct was patent over its entire length, dilated and tortuous (Fig. 1b). On the films taken one day after the injection, only a few para-aortic lymph nodes were visualized, especially marked on the right side (Fig. 1c). Small lymph vessels in the kidney were still opacified after 24 hours, but no contrast material in the collecting system could be demonstrated. No obstructive or space-occupying lesion was detected in the lymphatic system.

(2) A 47 year old male of Moroccan origin. This patient's only complaint was of the passing of "milky" urine for 5 months, which proved to be chyluria.

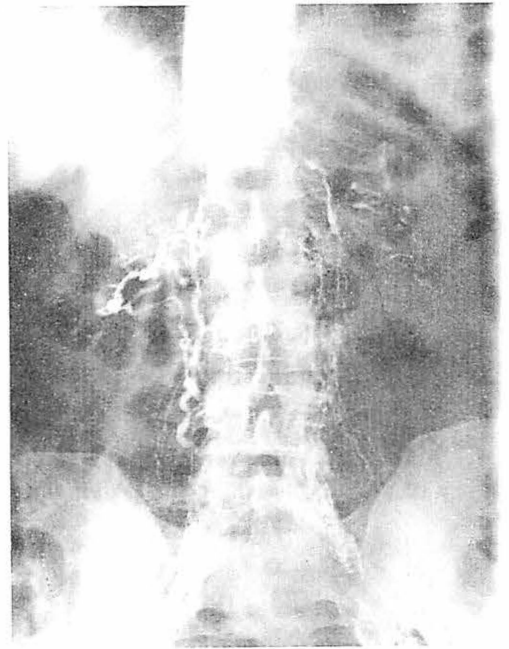
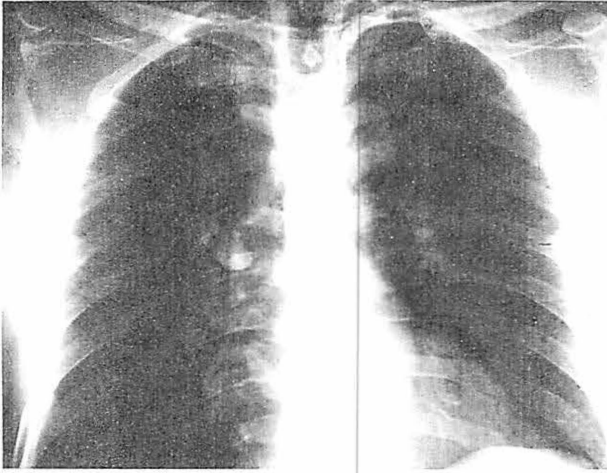


Fig. 2: Case 2.
a. Lymphangiectasis and filling of renal lymphatic vessels.

Permission granted for single print for individual use.

Reproduction not permitted without permission of Journal LYMPHOLOGY.



b. Patent and dilated duct. Thoracic duct seen on penetrated P-A chest film.

Clinical examination and excretory urography were normal.

The lymphangiogram showed lymphangiectasia, most marked in the right pelvis and right para-aortic gutter, with tortuous lymphatics entering both kidneys (Fig. 2a). The thoracic duct was patent and slightly dilated (Fig. 2b). On the 24 hour film, only a few normal glands were demonstrated in the pelvis and para-aortic nodes. The lymphatics in the kidney were still opacified (4) but no contrast material was seen in the collecting system (Fig. 2c). No obstructive lesions were demonstrated.

(3) A 46 year old female, born in Egypt. For 11 years she had experienced intermittent attacks of colicky left-sided abdominal pain. A short while prior to hospitalization she began passing a "milky" urine. On radiological investigation, a staghorn calculus was found in the left kidney, which was surgically removed.

Laboratory studies proved the chyluria which persisted after surgery although a post-operative urogram was normal. On the LAG no filling of lymph channels was obtained on the right side, whereas ectatic tortuous channels were seen in the left pelvic and para-aortic region. Lymph

c. 24-hour film (tomogram) showing residual contrast in the renal lymphatics especially in left kidney.

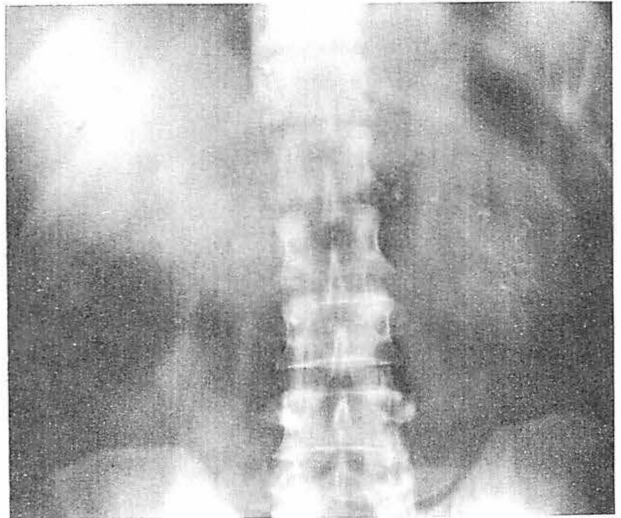

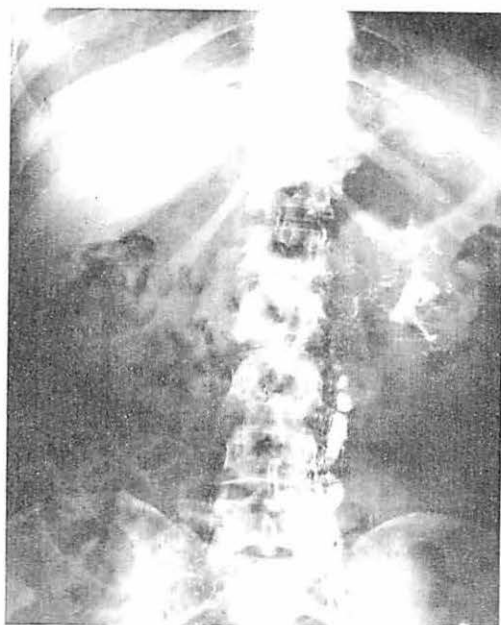
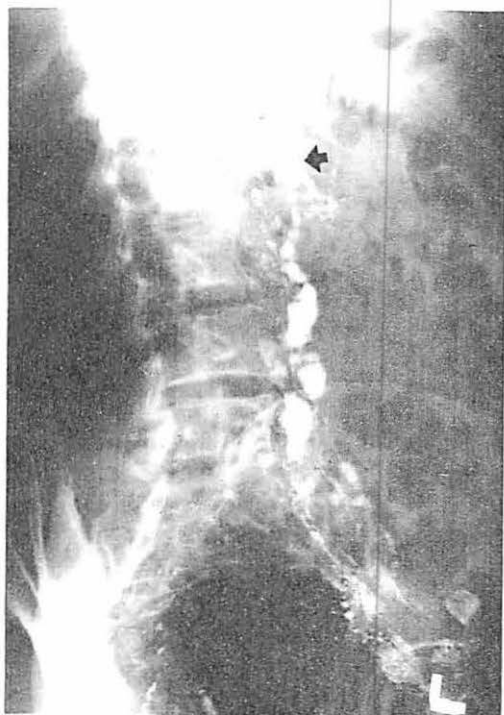

Fig. 3: Case 3.

a. Oblique projection showing lymphangiectasis and intra-renal lymph vessel opacification and contrast in the renal pelvis and calyces (arrow).

vessels were also outlined in the left kidney with early filling of the renal pelvis and passage down to the bladder (Fig. 3a). The thoracic duct was normal and on the delayed films normal lymph nodes were demonstrated on the left side with no visualization of the right-sided ones. The lymph channels remained opacified in the left kidney (Fig. 3b).

Comment

In this patient the lack of contrast on the right side could have resulted from the injection of an inadequate quantity of contrast material. The relationship of the staghorn calculus to the chyluria remained unclear.

Discussion

Chyluria, the appearance of lymph in the urine, results from abnormal communications between lymphatic ducts and the kidneys (1).

b. Late phase showing normal-sized left-sided glands and the renal collecting system still opacified.

Etiologically, chyluria can be divided into the parasitic and the non-parasitic forms. The former is by far the commonest, being endemic in many regions of the world. It results from the obstruction to the lymphatic system by the parasites of the filaria and cysticerci groups (2, 3). On the other hand, non-parasitic chyluria is uncommon (2). Earlier reports suggested thoracic duct obstruction as a major factor in the production of the chyluria, but more recently it has become recognized that the thoracic duct is usually patent and sometimes even dilated (4). This was the case in all three of our patients, and lymphangiography demonstrated this patency.

Non-parasitic chyluria has been reported in association with pregnancy, digestive tract tumours, retroperitoneal pathology, diabetes, tuberculosis and in postoperative conditions (2, 5). Fibrotic, inflammatory and tumorous involvement of the glands may cause a flow disturbance of varying magnitude (4), from complete obstruction to minimal disturbance.

The diagnosis of chyluria is a clinical and laboratory one and rests on the identification of lymph in the urine.

Radiological examinations for chyluria include Excretory Urography (EU), Retrograde Pyelography (RP) and Lymphangiography (LAG) (4, 5).

EU may be completely normal, as was the case in two of our three patients. The third had a large staghorn calculus which was surgically removed. Chyluria was present before and after the operation, and its relationship to the calculus, if any, is unclear. RP may demonstrate filling of lymph vessels from the pelvicalyceal system (5). This examination was not performed in our patients.

LAG is useful in determining certain etiologies such as lymphoma, metastatic disease of the lymph glands and thoracic duct abnormalities.

When performing lymphangiography in patients suffering from chyluria, special attention should be paid to the early phase of the examination. This entails obtaining abdominal films every two hours during the first day. The purpose is to demonstrate the lymphatic vessels and their communication with the urinary tract. Lymphangiectasis and lymphatic cysts can be found, as well as filling of the intra-renal lymphatics as demonstrated in all three patients. Actual passage of the contrast into the

calyces and renal pelvis can also be seen (Fig. 3a) (1, 4).

Penetrated P-A and lateral chest films will usually suffice to show the thoracic duct. As in all lymphangiographies, 24-hour films are obtained to study glandular detail.

In two of our three patients, we noticed a paucity of abdominal para-aortic glands, but those identified appeared normal (Fig. 1c). This paucity of glands raises the possibility that fibrosis in the non-opacified ones may have caused the increase in pressure with the subsequent development of collateral vessels, some entering the kidney where their rupture could cause the lymphatico-renal shunt necessary for the appearance of the chyluria (4).

References

- 1 Craig, O., F.J. Woodroffe: Chyluria and lymphatic renal fistula. *Clin. Radiol.* 20 (1969) 465-472
- 2 Choi, J.K., H.S. Wiedemer: Chyluria: Lymphangiographic study and review of literature. *J. Urol.* 92:6 (1964) 723-727
- 3 Kishimoto, T., T. Higuchi, M. Endo, Y. Kai: Lymphangiography in a patient with unilateral chyluria. *J. Urol.* 92:5 (1964) 574-578
- 4 Koehler, P.R., T.C. Chaing, C.T. Lin, K.C. Chen, K.Y. Chen: Lymphography in Chyluria. *Amer. J. Roentgenol.* 102 (1968) 455-465
- 5 Stams, U.K., E.O. Gursel, R.J. Veenema: An unusual radiologic finding in a patient with chyluria. *J. Urol.* 112 (1974) 128-132

B. Morag, M.D., Institute of Diagnostic Radiology, Chaim Sheba Medical Center, Tel Hashomer, Israel.