

Radiological Evidence of Lymphatic Drainage of Bone Marrow Cavity in Long Bones

W.L. Olszewski, Z. Sawicki

Dept. of Surgical Research and Transplantation, Experimental and Clinical Medical Research Center, Polish Academy of Sciences, Warsaw, Poland

Summary

Injection of *Lipiodol UF* into the distal epiphyses of tibia and femur in the dog was followed within several minutes by visualization of lymphatics draining the bone. Some of the radioopaque material was retained in the bone marrow cavity and tiny lymph vessels originating in that area could be seen. Contrast medium filled also the popliteal lymph node. The problem of migration of bone marrow lymphocytes through the lymphatics to the regional lymph nodes is discussed.

In an attempt to visualize radiologically lymphatics draining tissues of the limb, from the site of their origin up to the thoracic duct, and to study their topography we injected *Lipiodol Ultrafluid* as a brand product and in the emulsified form (10) into tissues like skin, subcutis and muscles, then under the periosteum and into the bone marrow cavity of the hind limb of dogs. Following the injection of oily radioopaque material into skin and subcutaneous tissue fragments of afferent lymphatics and of popliteal lymph nodes could be demonstrated after 24-72 hours. No pictures of that type could be obtained after injection of *Lipiodol UF* into the muscle tissue. The results have been published previously (10).

The present paper has been devoted to studies of pathways of lymphatic drainage of long bones by injection of *Lipiodol UF* under the periosteum and into the bone marrow cavity. The lymphangiograms revealed the existence of lymphatic drainage of bone marrow cavity of long bones and connections with the extraosseous lymphatic system.

Material and methods

Studies were carried out on 16 mongrel dogs divided into 2 groups. In group 1 a burr-hole

was made in the medial aspect of left distal epiphysis of the tibia. A cannula of the size of the hole was introduced into the bone marrow cavity and the space between the wall of cannula and the edges of the burr-hole sealed off with wax.

5 ml of *Lipiodol UF* were injected within 3 minutes into the bone marrow cavity. At the same time the femoral vein was pressed against the femoral bone, then slowly released, to avoid rapid evacuation of oily contrast medium into the vena cava.

On the right side the same volume of *Lipiodol UF* was slowly injected under the periosteum of the tibia. The x-ray pictures of both limbs were taken immediately following the injection, and 30 minutes, 24 hours, and 7 days thereafter.

In group 2 the same type of experiment was performed on the femur with contrast medium injected into its distal epiphysis.

Results

Injection of *Lipiodol UF* into the bone marrow cavity of distal epiphysis of dog's tibia and femur was followed by visualization of lymphatics draining the bone marrow cavity. Immediately after injection contrast medium was evacuated through the veins, but some of it entered lymphatics of the calf and some filled the bone marrow cavity of proximal tibia, to visualize tiny lymph vessel at the knee joint level (Fig. 1, 2).

Thirty minutes after injection less contrast medium was seen in bone marrow cavity, but the popliteal lymph node was partly opacified.

After 24 hours no contrast medium was found in the lymphatics. Some of it could still be

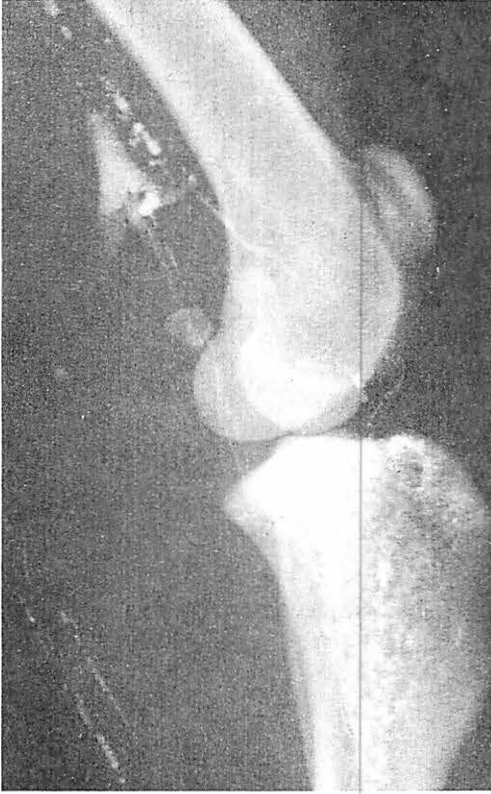

Fig. 1: Lymphangiogram of vessels draining the proximal epiphysis of the tibia of the dog taken 5 minutes after injection of 5 ml of Lipiodol UF into the distal epiphysis. Oily contrast medium in the trabecular matrix of the bone. Note lymphatics leaving the bone at the level of knee joint, probably running in the joint capsule, then joining larger thigh lymphatics. In the upper part some of the contrast medium in the vein outlining its valve.

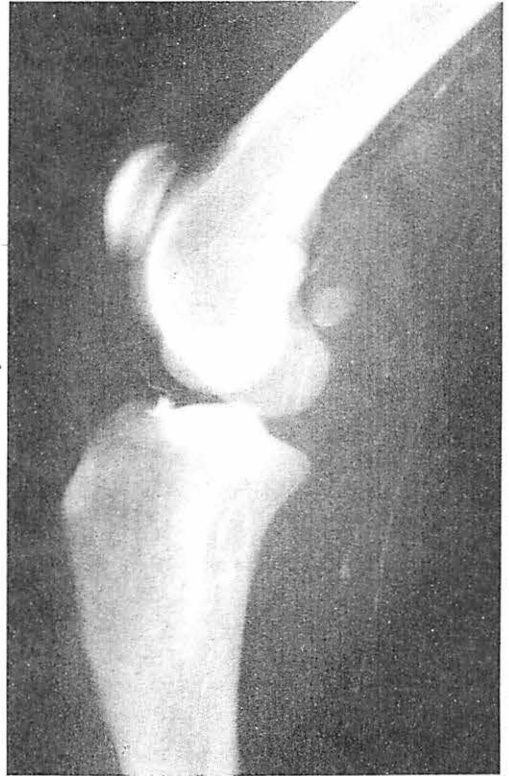


Fig. 2: Similar lymphangiogram as on Fig. 1 taken 30 minutes after injection of Lipiodol UF. Note single, thin vessel leaving the upper pole of the tibia, joining deep lymphatics in the lower part of the thigh. To the right opacified lymphatics running in the posterior part of the popliteal region, bypassing the popliteal lymph node.

found in the bone. The popliteal lymph node was opacified (Fig. 3).

No contrast medium could be seen in leg lymphatics after its injection under the periosteum of tibia. Twenty-four hours later it remained under the periosteum and only traces could be found in the popliteal lymph node.

Following injection into the distal epiphysis of femur lymphatics draining that part of the bone were outlined in the first 5 minutes (Fig. 4).

Discussion

The presence or absence of lymphatics in long bones has been the subject of controversial opinions. Even more controversial has been the problem of lymphatic drainage of the bone marrow cavity. Most authors (1, 7, 8, 11) have not been able to demonstrate lymph vessels in bone. Hudson and Yoffey (5) studied the ultrastructure of the reticulo-endothelial elements in guinea-pigs bone marrow but did not find any elements of the wall of initial lymphatics.

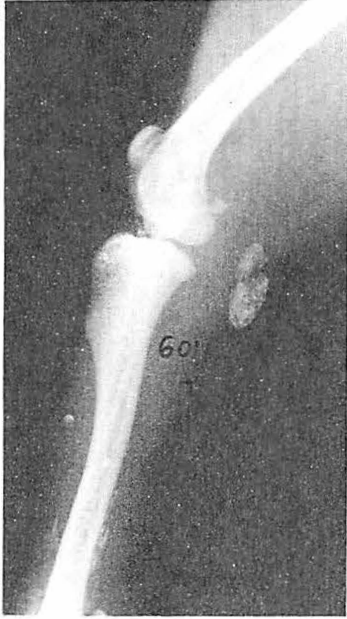

Fig. 3: Lymphadenogram of the popliteal lymph node taken 24 hours after injection of *Lipiodol UF* into the bone marrow cavity of the tibia.

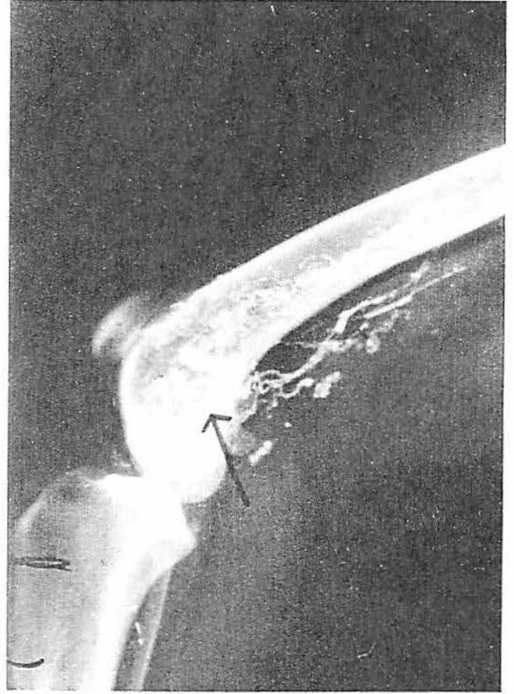


Fig. 4: Lymphangiogram of vessels draining the distal part of femur taken 30 minutes after injection of contrast medium into the distal epiphysis (arrow). Note radioopaque material retained in the bone marrow cavity. Multiple lymphatics at the posterior aspect of the bone. Some oily droplets in the veins.

On the other hand *Deysine* (4) observed after injection of radioopaque material into the bone marrow cavity its very rapid passage (1-3 minutes) into the periosteal lymphatics and localization in the regional lymph nodes. He postulated that lacunae and canaliculi in the cortical bone correspond to the lymphatic system and that they are physiologically and anatomically in communication with the extrasosseous lymphatic system.

In clinical cases incidental visualization of calf lymphatics was described during arthrography of the ankle joint (6), and also during transosseous venography of the lower leg (9).

The most interesting observations throwing light on the pathways of lymphatic drainage of the bone marrow cavity and the role played by them, are those described by *Brahim and Osmond* (2, 3). These authors demonstrated that selective tibial bone marrow labeling with ^3H -thymidine in normal guinea-pigs was followed by an export of DNA radioactivity from the bone marrow to the popliteal lymph node. This was reflected in autoradiographs of the popliteal lymph node on the in-

jection side by accumulation of labeled marrow-derived cells. The results indicate that the newly formed small lymphocytes are released from the marrow and migrate continuously via lymphatics into peripheral lymph nodes where they become widely distributed throughout the cortex and medulla.

Our studies deliver a radiological proof for the existence of direct communication between the marrow cavity of long bones and the extrasosseous lymphatic system. They show the pathways the bone marrow lymphocytes are transported to regional lymph nodes, the phenomenon described by *Brahim and Osgod*. Most convincing are our pictures revealing lymphatics originating in the upper part of tibia. In the distal part of that bone some large lymphatics could also be seen, but there might have been some extravasation of the

contrast medium into the subcutaneous tissue after removal of the cannula, what could contribute to the opacification of the popliteal lymph node. However injection of contrast medium under the periosteum was not followed by filling of the node with radio-opaque material.

Both studies, of *Brahim and Osmond* and ours, indicate that lymphocyte population in the afferent lymphatics of the limb may consist not only of cells migrating from the blood through the tissues but also of cells derived from the bone marrow.

References

- 1 *Baum, H.*: Lymphgefäßsystem des Hundes. August Hirschwald Verlag, Berlin 1918
- 2 *Brahim, F., D.G. Osmond*: The migration of lymphocytes from bone marrow to popliteal lymph nodes demonstrated by selective bone marrow labeling with ³H-thymidine in vivo. *Anat. Rec.* 175 (1973) 737-746
- 3 *Brahim, F., D.G. Osmond*: Migration of newly formed small lymphocytes from bone marrow to lymph nodes during primary immune responses. *Clin. exp. Immunol.* 24 (1976) 575-586
- 4 *Deysine, M.*: Lymphatic space in cortical bone, anatomy and physiology. Abstracts 4th Congress of International Lymphological Society. Tucson, Arizona. March 6-10, 1973
- 5 *Hudson, G., J.M. Yoffey*: Ultrastructure of reticuloendothelial elements in guinea-pigs bone marrow. *J. Anat.* 103 (1968) 515-525
- 6 *Lüning, M., P.A. Romaniuk*: Spontane Lymphgefäßdarstellung nach Arthrographie des oberen Sprunggelenkes. *Fortschr. Roentgenstr.* 108 (1968) 400-405
- 7 *Orts-Lorca, F., F. Verge-Brian*: Lymphgefäße des Periosteums der Ossa Longa. *C.R. Ass. Anat.* 436 (1932)
- 8 *Oschkaderow, W.T.*: Lymphgefäße der distalen Gelenke der Extremitäten. *Anat. Anz.* 66 (1929) 377-403
- 9 *Prager, W.*: Kontrastmittelfüllung eines Lymphgefäßes am Unterschenkel als Nebenbefund einer transossalen Venographie. *Fortschr. Roentgenstr.* 110 (1969) 276-282
- 10 *Sawicki, Z., Z. Machowski, W. Olszewski*: Próby zastosowania emulgowanego Lipiodolu Ultrafluide do limfografii pośredniej. *Pol. Przegl. Rad. Med. Nukl.* 4 (1973) 533-540
- 11 *Vizkelety, von T., L. Kery*: Über den perivaskulären Lymphkreislauf des Knochens. *Anat. Anz.* 124 (1969) 37-48

W.L. Olszewski, Dept. of Surgical Research and Transplantation Experimental and Clinical Medical Research Center, Polish Academy of Sciences, 5 Chalubinskiego, 02-004 Warsaw/Poland