

## The Influence of the Spleen on Thoracic Duct Lymph in Schistosomal Hepatic Fibrosis

A. Aboul-Enein, A. Ismail

Department of Surgery, Faculty of Medicine, Alexandria University,  
Alexandria, Egypt

### Summary

1. Splenectomy was found to cause a marked decrease in the thoracic duct lymph flow and pressure in patients with schistosomal fibrosis.
2. There was no direct correlation between the drop in thoracic duct lymph flow and the drop in portal pressure produced by removal of the spleen.
3. The splenic lymphatics were found to be increased in number and distended.
4. In some patients, the splenic lymphatics contained intact red blood cells.
5. Removal of the spleen caused immediate disappearance of red blood cells from thoracic duct lymph.

The pathogenesis of ascites in schistosomal hepatic fibrosis remains unclear. In a previous communication from our center, we reported increased flow and pressure in the thoracic duct of patients with schistosomal hepatic fibrosis where portal hypertension is characterized by presinusoidal obstruction (7).

In Laennec's cirrhosis, excess thoracic duct lymph originates from both the liver and extrahepatic portal bed (3, 8, 9). These authors also suggest that, in "early" cases, the liver is the major source of increased thoracic duct lymph, whereas in "late cases excess extrahepatic portal lymph combines with hepatic lymph to overload the thoracic duct. On the other hand, in schistosomal hepatic fibrosis with presinusoidal block, the extrahepatic portal bed is probably the sole source of excess thoracic duct lymph.

The observation by *Dumont* et al. (4) that in patients with hepatic cirrhosis or congestive heart failure the splenic pedicle contains a number of dilated lymphatics, is similar to that previously described by *Baggenstoss and Cain* (1) and *Baggenstoss* (2), at the hilus of the liver. This finding suggests that part of the excess extrahepatic lymph originates from the spleen. To evaluate this possibility, the present study was undertaken to determine the role played by the spleen in excess lymph production in patients with schistosomal hepatic fibrosis, a disorder characterized by presinusoidal portal block.

### Material and Methods

Ten cases of schistosomal hepatic fibrosis and portal hypertension with presinusoidal obstruction as judged by intrasplenic pressure, wedged hepatic vein pressure and liver biopsy, were subjected to splenectomy. Prior to removal of the spleen the thoracic duct was exposed in the neck and cannulated. Lymph flow and pressure were measured before and after removal of the spleen. In four cases, the umbilical vein was cannulated and portal pressure was also monitored.

Before removal of the spleen, the splenic pedicle was clamped. With the clamp still in place, the resected specimen was fixed in formalin. Representative sections embedded in paraffin were stained with haematoxylin and Cosin and Van Giesson stains.

### Results

Tables I and II summarize the data obtained in ten cases before and after splenectomy. After removal of the spleen, lymph flow from the thoracic duct was uniformly decreased averaging only 32.4 per cent of its pre-splenectomy value. Portal pressure similarly decreased after splenectomy but only to 64.6 per cent of its pre-splenectomy value. There was no direct correlation between the drop in the thoracic duct lymph flow rate and the drop in portal pressure ( $r = 0.18$ ).

In all cases with hemorrhagic thoracic duct lymph, there was an immediate disappearance of bloody appearance of the lymph following removal of the spleen.

On histologic sections, the intrasplenic and hilar splenic lymphatics were uniformly dilated and increased in number (Fig. 1 and 2). Moreover, the splenic lymphatics in those patients having hemorrhagic thoracic duct lymph contained intact red blood cells (Fig. 3).

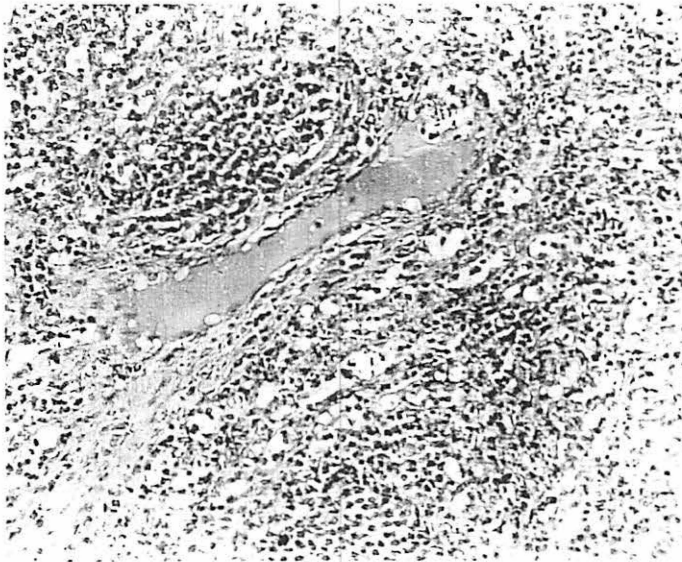


Fig. 1. Shows a distended intra-splenic lymphatic.

### Discussion

Presinusoidal obstruction leads to an increased formation of lymph in the extrahepatic portal bed. Accordingly, the sites of origin of the excess lymph to the thoracic duct are the gastrointestinal tract and the spleen. The fact that splenectomy in patients with schistosomal fibrosis decreases thoracic duct lymph flow and pressure invites speculation as to the mechanism involved. While removal of the spleen eliminates any splenic component of thoracic duct lymph, splenectomy also lowers portal pressure, which may reduce the contribution of gastrointestinal or mesenteric lymph to the thoracic duct. However, the finding that splenic lymphatics are dilated and increase in number indicates some contributory effect from the "congestive spleen" to the excess lymph production. Moreover, the fact that 2 patients (Case 3 and 4) demonstrate com-

Table I

Case No.	Protein Content				Before Splenectomy				After Splenectomy			
	Wt. of spleen (kg)	Plasma	Lymph cm saline	Pressure cc/min	Thoracic Duct Pressure cc/min	Lymph appearance	Flow cc/min	Umbilical vein press. mm saline	Thoracic Duct Pressure mm saline	Lymph appearance	Flow cc/min	Umbilical vein press. mm saline
1	2.7	-	-	38	-	Bloody	4.5	-	11.0	1.5	1.5	-
2	2.5	5.7	1.4	20	-	Clear	4.0	280	5.0	2.0	2.0	130
3	2.0	8.3	4.7	21	-	Clear	6.5	360	6.5	2.1	2.1	190
4	1.0	10.4	4.8	65	-	Clear	12.0	370	10.0	2.5	2.5	290
5	1.5	6.2	1.1	45	-	Clear	14.0	370	28.0	8.0	8.0	-
6	1.3	-	-	10	-	Bloody	8.0	-	10.0	1.2	1.2	-
7	2.8	-	-	80	-	Bloody	11.0	-	30.0	4.0	4.0	-
8	1.5	-	-	75	-	Bloody	17.0	-	52.0	5.0	5.0	-
9	1.0	-	-	34	-	Bloody	15.0	-	23.5	4.0	4.0	-
10	1.2	-	-	46	-	Bloody	11.5	-	27.0	3.5	3.5	-
Mean	1.8	7.7	3.0	43	-	10.3	10.3	345	20.3	3.4	3.4	203
S.D.	0.7	2.2	2.0	34	-	4.5	4.5	44	14.7	2.0	2.0	81
S.E.	0.2	1.1	1.0	8	-	1.4	1.4	22	4.6	0.6	0.6	47

Permission granted for single print for individual use.

Reproduction not permitted without permission of Journal LYMPHOLOGY.

Table II

	Percentage decrease in presplenectomy value	P
Drop of thoracic duct flow rate	67.4	< 0.001
Drop of thoracic duct pressure	54.0	< 0.02
Drop of portal pressure	35.4	< 0.05

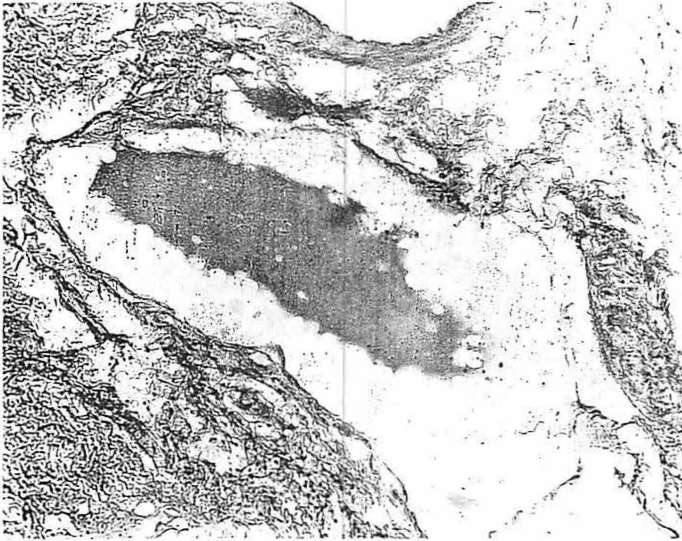


Fig. 2. Shows a dilated hilar lymphatic.

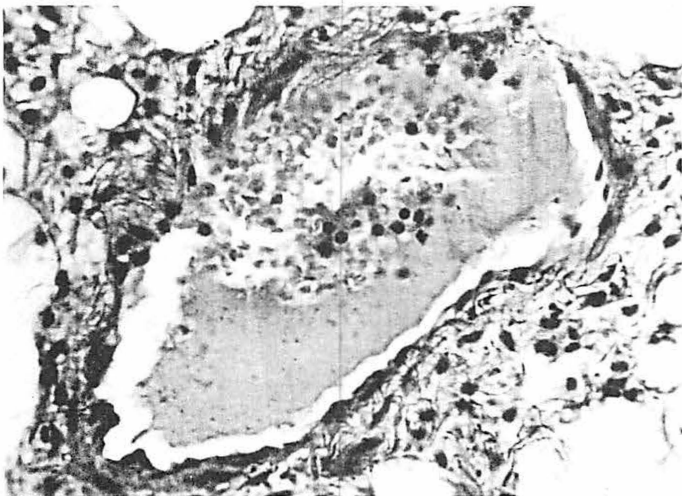


Fig. 3. Splenic lymphatic. Notice the presence of red blood cells.

paritively high protein thoracic duct lymph suggests a major lymph component arising from the sinusoidal splenic circulation.

A high incidence of hemorrhagic thoracic duct lymph characterizes patients with schistosomal hepatic fibrosis as it does Laennec's cirrhosis. *Dumont et al.* (5), studying cases with Laennec's cirrhosis suggests that red blood cells "enter the thoracic duct from outside the liver and extrahepatic areas" due to retrograde flow of blood through lymphatic-venous communications.

There are two possibilities by which splenectomy in our series cleared red cells in the thoracic duct lymph. Local circulatory congestion of the spleen has been shown to induce hemorrhagic splenic lymph (*Rusznayak, Foldi and Szabo* (6)) and was seen in our patients with schistosomal fibrosis. On the other hand, it is also possible that splenectomy by lowering portal pressure and decreasing tension in lymphatic-venous communications reduces retrograde blood flow into lymph and thereby clears red blood cells from the thoracic duct. Whether the clearing of red cells by splenectomy in thoracic duct is exerted by removal of the site of their entry from the spleen or indirectly by its action on the portal vascular bed and hence lowering of tension in lymphatic-venous shunts or both together is not certain from these observations.

#### References

- 1 *Baggenstoss, A.H., J.C. Cain*: Hepatic hilar lymphatics of man. Their relation to ascites. *New Engl.J.Med.* 256 (1957) 531-535
- 2 *Baggenstoss, A.H.*: Further studies on the lymphatic vessels at the hilus of liver of man. Their relation to ascites. *Proc.Staff May.Clin.* 32 (1957) 615-627
- 3 *Dumont, A.E., M.H. Witte*: Contrasting patterns of thoracic duct lymph formation in hepatic cirrhosis. *Surg.Gyn.Obst.* 122 (1966) 524-528
- 4 *Dumont, A.E., C.L. Witte, M.H. Witte, W.H. Cole*: Origin of red blood cells in thoracic duct lymph in hepatic cirrhosis. *Ann.Surg.* 171 (1970) 1-8
- 5 *Dumont, A.E., T. Pughem, J. Grosfeld, F. Gorstein*: Alterations in splenic hilar lymphatics in patients with congestion of the spleen. *Proc.Soc.Exper.Biol.Med.* 135 (1970) 642-647
- 6 *Rusznayak, I., M. Foldi, G. Szabo*: Lymphatics and lymph circulation. Pergamon Press, Oxford, London, New York, Paris 1960, p.113
- 7 *Sadek, A.M., A. About-Enein, E. Hassanein, A. Ismail*: Thoracic duct changes in schistosomal hepatic fibrosis. *Gut* 11 (1970) 74-78
- 8 *Witte, M.H., A.E. Dumont, W.H. Cole, C.L. Witte, K. Kintner*: Lymph circulation in hepatic cirrhosis: Effect of portacaval shunt. *Ann.Int.Med.* 70 (1969) 303-310
- 9 *Witte, C.L., M.H. Witte, W.R. Cole, Y.C. Chung, V.R. Bleisch, A.E. Dumont*: Dual origin of ascites in hepatic cirrhosis. *Surg.Gyn.Obstet.* 129 (1969) 1027-1033

*A. About-Enein, M.S., A. Ismail, M.S., Department of Surgery, Faculty of Medicine, Alexandria University, Alexandria/Egypt*