

The Microcirculation of the Mammalian Lymph Node

B.B. Hobbs, J.W. Davidson

Radiological Research Laboratories University of Toronto, Toronto, Ontario, Canada

Summary

Flow alterations to give complete filling of the lymphatic sinusoidal system and saccular lymph spaces around the germinal centers were demonstrated during a primary immune reaction. By contrast, in delayed hypersensitivity, saccules were not seen although there was marked enlargement of individual follicular units.

The vascular and lymphatic microcirculations of the popliteal lymph node of normal adult New Zealand white rabbits were studied following injections of microfil* into afferent arteries and lymphatics. Vessels and lymphatic spaces within the lymph nodes of normal antigenically experienced animals were compared with those regional to an injection of the antigen Keyhole Limpet Hemocyanin** 2 mgs. In a third group of animals previously sensitized to killed tubercle bacilli, a challenging dose of purified protein derivative of old tuberculin was given, and both microcirculations studied after an interval of 48 hours.

In normal animals, afferent lymph vessels lead to a dome shaped network of sinusoids around individual follicles. These continue directly into a dense medullary sinusoidal network leading in turn to small efferent canaliculi and large calibre efferent trunks. Flow of the casting medium from afferent to efferent lymphatics frequently occurred only through a segment of the lymph node with non filling of many adjacent areas. Within individual cleared sub marginal follicles, a few small circumscribed saccular collections were demonstrated (Fig. 1).




Fig. 1 Radiograph x 20 of Microfil within a normal popliteal node following intralymphatic injection. Note saccular aggregates (arrowed) deep to the marginal sinus within the clear areas of follicles.

* Canton Biomedical Products Ltd., Boulder, Colorado, U.S.A.

** Biomarine Laboratories, Venice, California.

Presented at the IV th Congress of the International Society of Lymphology, Tucson/Arizona, 1973.

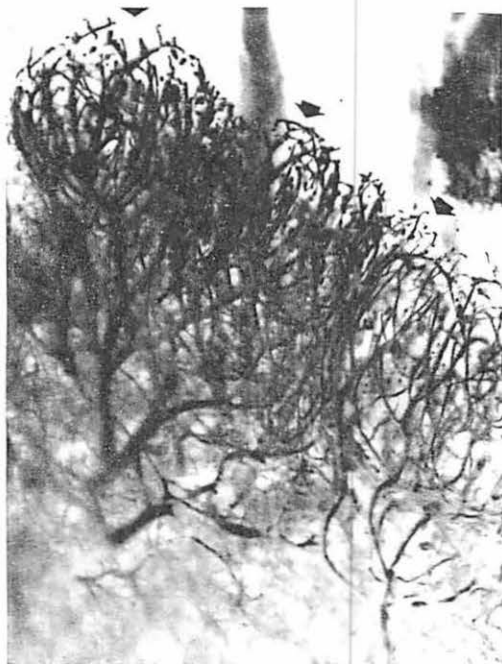


Fig. 2a Microfil cast x 20 of popliteal lymph node following intra-arterial injection.

Note: Individual follicular units in submarginal cortex.

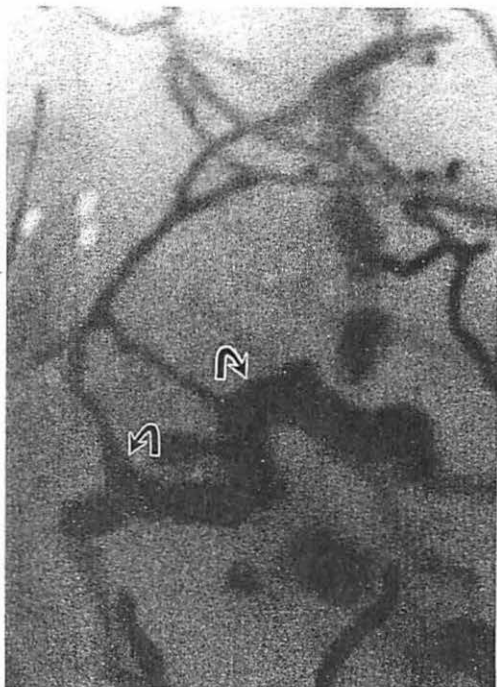


Fig. 2b At 55 x magnification, the capillary, post-capillary venular junction is demonstrated.

Arteries, capillaries, post capillary venules and veins showed a constant arrangement within and around the cleared areas of sub cortical follicles (Fig. 2). These together with a lymph sinusoidal dome may be regarded as a microcirculatory unit (1).

Regional to an injection of KLH the size and number of lymphatic sinusoidal domes increased

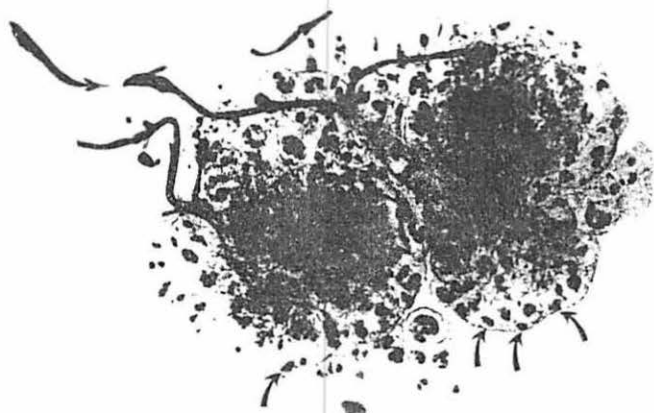

Fig. 3 Radiograph x 20 of Microfil cast of lymph node section 5 days after injection of K.L.H. 2 mg. into the foot.

Note: Numerous sub marginal sinusoidal domes within which are many saccular aggregates.

markedly. The lymphatic sinusoidal network filled throughout the entire node. Within the follicles, numerous saccules were evident by five days (Fig. 3). These appearances returned to normal by approximately 15 days. In the same time period, the number of blood vessels first increased and then decreased with preservation of the individual vascular units.

In the lymph nodes of animals sensitized to TB, 48 hours after a challenge injection of P.P.D. of old tuberculin into the foot, the microcirculatory units to individual follicles enlarged markedly (Fig. 4). On sectioning, these were seen to extend deeply within the cortex. No definite changes occurred in medullary structures.

This experiment shows complete filling of the lymphatic sinusoidal system of the popliteal lymph node and numerous saccules within individual follicles extending into the area of the germinal center during a primary immune reaction. The appearances are consistent with storage or mixing saccules (2) in which antigen containing lymph may be retained in contact with receptor areas. By contrast during a delayed hypersensitivity response, the saccules were not present although marked enlargement of individual follicular units occurred.

References

- 1 Davidson J.W., B.B. Hobbs, A. Fletch: The microcirculatory unit of the mammalian lymph node. VII Conference on Microcirculation Paper (1972) 191
- 2 Dunn R.F., R.W. Strahan: Studies on the lymph node-venous communication. *Lymphology* 5 (1972) 161-169

Dr. J.W. Davidson, Dept. of Radiology, Cedoke Hospitals, P.O. Box 590, Hamilton/Ontario, Canada



Fig. 4 Radiograph x 20 of microfil cast of lymph node section 48 hours regional to P.P.D. challenge in sensitized animal.

Note: Large follicular units within the cortex.