

Waldenstrom's Macroglobulinaemia with Amyloidosis — Lymphographic Findings

D.B. Stevens, G.H. Whitehouse

Department of Radiodiagnosis, University of Liverpool, England

Summary

This communication describes the fourteenth reported case of Waldenstrom's macroglobulinaemia associated with amyloidosis, and the second describing the lymphographic findings with this combination. The appearances on lymphography are indistinguishable from lymphoma.

In Waldenstrom's macroglobulinaemia there is an abnormal lymphocytic proliferation within bone marrow and other parts of the reticulo-endothelial system (Waldenstrom, 1944). These lymphoid cells are responsible for the production of the excessive amounts of the macroglobulin IgM fraction which is found in this disease.

'Atypical amyloidosis', which occurs in 15% of cases of myeloma (Bayrd and Bennett, 1950), is occasionally associated with Waldenstrom's macroglobulinaemia, (Forget et coll. 1966). This form of amyloidosis has features in common with both the rare primary amyloidosis, and with the amyloidosis which occurs secondary to chronic inflammation (Pear, 1968), although its staining properties and distribution tend more to resemble the primary type (Wang and Robbins, 1956).

This case is the second recorded example of lymphography in Waldenstrom's macroglobulinaemia associated with amyloid disease involving the lymph nodes.

Case Report

The patient, a fifty nine year old male, initially presented to hospital with a five month history of syncopal attacks, urinary incontinence, impotence, tiredness, weakness in the legs, and a weight loss of 16 Kg. On examination he was found to have postural hypotension, weakness in dorsi-flexion of the feet and in knee flexion, and loss of pain sensation in the hands and feet. The plantar responses and all tendon reflexes were normal. The main peripheral nerves in the extremities were readily palpable. There was right cervical, and bilateral axillary and inguinal lymphadenopathy. Investigations included: Haemoglobin 10 gm/100 ml; leucocyte count 6,500 per cu.mm. with normal distribution of cells, E.S.R. 137 mm in 1st hour, total plasma proteins 77 g/l (albumin 34 g/l; plasma immunoglobulin estimation IgG 6 g/l and IgM 60 g/l).

The serum viscosity relative to water at 37°C was 2.23 (normal 1.4-1.8). A monoclonal IgM line, demonstrated by immunophoresis, was isolated and found to contain Kappa light chains. It was concluded that the patient had a monoclonal gammopathy. A bone marrow biopsy revealed a hyper-cellular marrow with lymphoid cells accounting for 56% of the total cell count, while many of the mononuclear cells had pyroninophilic cytoplasm and some of the lymphoid cells had plasmacytoid features, the appearances being consistent with Waldenstrom's macroglobulinaemia. A rectal biopsy showed a material which stained positively with Congo Red within the walls of small blood vessels of the muscularis mucosae, consistent with amyloid. Histology of two biopsied axillary lymph nodes showed the presence of amyloid. No evidence of malignant lymphoma was seen, but lymph within the node showed deep eosinophilic staining, a feature of Waldenstrom's macroglobulinaemia.

A chest radiograph showed some pulmonary vein engorgement, and a skeletal survey was normal. An isotope liver scan (Tc 99 m sulphur colloid) showed the liver to be enlarged, with patchy diminution of uptake of isotope within the right lobe.

Lymphography, with 8 ml of Lipiodol Ultra-fluide being injected into lymphatic vessels on the dorsum of each foot, revealed enlargement of the inguinal and iliac lymph nodes, with a coarse reticular pattern and filling defects within these nodes. The para-aortic lymph nodes contained multiple filling defects and a very irregular pattern of opacification (Fig. 1).

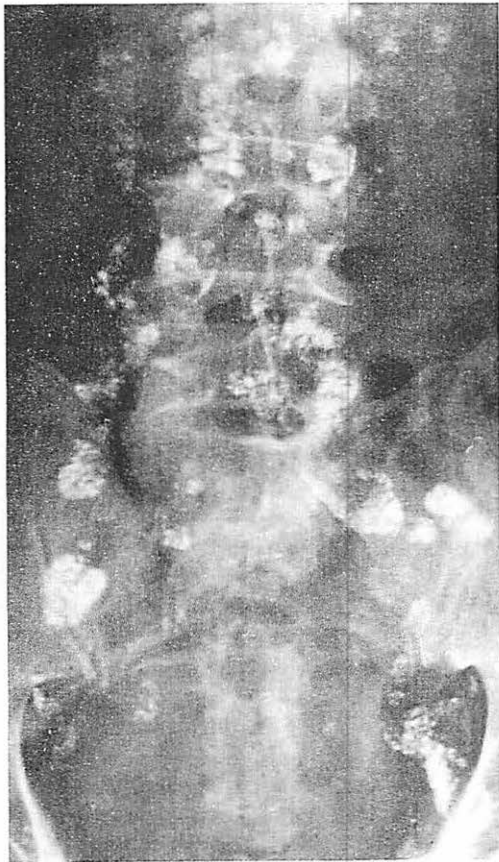


Fig. 1 Lymphography: Large inguinal and iliac lymph nodes with coarse reticular pattern combined with filling defects. Para-aortic lymph nodes are irregularly delineated and multiple filling defects are present.

The patient was initially treated with prednisolone and blood transfusions, and more recently by Melphalan and cyclophosphamid. Although the patient's plasma viscosity has returned to almost normal levels, his presenting symptoms have increased in severity. It is considered that he has a neuropathy due to amyloid infiltration, although no histology of nerve tissue is available. A radiograph of the abdomen five months after the lymphogram showed no change in the appearance of the abdominal and pelvic lymph nodes during this time.

A further isotope scan of the liver, two months after the first, showed no change. No liver biopsy has been taken, but it is likely that the abnormal appearances are due either to amyloid or lymphocytic infiltration.

Discussion

Osserman (1959) considered multiple myeloma, Waldenstrom's macroglobulinaemia, amyloidosis and lymphoma to all be manifestations of reticulo-endothelial proliferative disorders, and that a proliferative disorder of plasma cells with an associated derangement of immunoglobulin amyloid is related to globulin and is formed from the globulin produced by plasma cells.

Lymph node enlargement is fairly common in Waldenstrom's macroglobulinaemia. Primary amyloid disease, to which 'atypical' amyloidosis generally shows some resemblance, is associated with lymphadenopathy in 20% of cases (*Rukavina et coll.* 1956). Amyloid tissue was present in the present patient, who in all probability also has nerve involvement by amyloid which may also occur in the primary disease.

Lymphography has been described in five patients with uncomplicated Waldenstrom's macroglobulinaemia (*Doehler and Salmon* 1966; *Khilnari et coll.* 1969; *Whitehouse et coll.* 1974), and in all these cases it was commented that the lymphographic appearances would be entirely consistent with lymphoma.

Twelve cases of amyloid associated with Waldenstrom's macroglobulinaemia have been found by *Forget et coll.* (1966), and a further one by *Bottomley et coll.* (1974). This last case, in which there was calcification within subcutaneous amyloid deposits, was the first recorded example of lymphography in the presence of proven lymph node involvement by amyloidosis. Gross enlargement of the pelvic and para-aortic lymph nodes was present with multiple filling defects within the nodes being combined with a pattern of coarse reticulation. The appearances were very similar to the present example, although lymph node enlargement was more marked. The appearances were indistinguishable from lymphoma in both cases, and it appears likely that amyloid deposits within para-aortic and pelvic nodes contributes to the lymphographic appearances although no biopsy from these sites was available to confirm a similar histological picture to the axillary biopsied nodes.

References

- Bayrd, E.D., W.A. Bennet*: Amyloidosis complicating myeloma. *Med. Clin. N. Amer.* 34 (1950) 1151
- Bottomley, J.P., J. Bradley, G.H. Whitehouse*: Waldenstrom's macroglobulinaemia and amyloidosis with subcutaneous calcification and lymphographic appearances. *Brit. J. Radiol.* 47 (1974) 232
- Forget, B.G., J.W. Squires, H. Sheldon*: Waldenstrom's macroglobulinaemia with generalised amyloidosis. *Arch. Int. Med.* 118 (1966) 363
- Khilnari, M.T., R.J. Keller, J. Cuttner*: Macroglobulinaemia and steatorrhoea; Radiological and pathological findings in the gastro-intestinal tract. *Radiol. Clin. N. Amer.* 7 (1969) 43
- Kohler, P.R., R.B. Salmon*: Lymphographic patterns in lymphomas. *Radiology* 87 (1966) 623
- Osserman, E.F.*: Plasma cell myeloma II Clinical aspects. *New Engl. J. Med.* 261 (1959) 1006
- Pear, B.L.*: The plasma cell in radiology. *Amer. J. Roentgenol.* 102 (1968) 908
- Rukavina, J.G., W.D. Block, C.E. Jackson, H.F. Falls, J.H. Carey, A.C. Curtis*: Primary systemic amyloidosis. *Medicine* 35 (1956) 239
- Waldenstrom, J.*: Incipient myelomatosis and "essential" hyperglobulinaemia with fibrinogenopenia: a new syndrome. *Acta. med. Scandinav.* 117 (1944) 216
- Wang, C.C., L.L. Robbins*: Amyloid disease. Its radiological manifestations. *Radiology* 66 (1956) 489
- Whitehouse, G.H., J.P. Bottomley, J. Brandley*: Lymphographic appearances in Waldenstrom's macroglobulinaemia. *Brit. J. Radiol.* 47 (1974) 226

Dr. D.B. Stevens, Dept. of Radiodiagnosis, Univ. of Liverpool, Liverpool, England