

## Analysis of the Radiographically Visualized Deep Hepatic Lymph Drainage in the Dog

Francis A. Burgener, James T. Adams

Department of Radiology (F.A.B., Associate Professor) and Department of Surgery (J.T.A., Associate Professor), University of Rochester School of Medicine and Dentistry, Rochester, New York

### *Summary*

The deep hepatic lymph drainage of 9 cholecystectomized dogs was analyzed after radiographic visualization with retrograde biliary infusion of Ethiodol. No drainage from the deep to the superficial lymph system of the liver was found with the described method. Primary stations of the deep hepatic lymph drainage are the hepatic, left gastric and splenic lymph nodes although the latter two were not always opacified. On the average 9 (6-11) hepatic lymph nodes were opacified which is a significantly higher number than previously reported. Retrograde contrast material filling of splenic, mesenteric, aortic, iliac and some intrathoracic lymph nodes occurred with various frequencies but the opacification of these nodes was usually incomplete.

Radiographic visualization of the lymph system with diagnostic quality could only be achieved until now by direct lymphography which is performed by injecting contrast material directly into the lymph vessels, lymph nodes or occasionally lymph cysts. Radiological investigation of the lymph drainage of internal organs has remained outside the range of diagnostic possibilities because indirect lymphography, that is the injection of the contrast agent into an organ outside the lymphatic system could not provide diagnostic radiographic results (4).

Anatomic and physiologic characteristics of the liver made this organ suited for indirect lymphography. Backflow of bile to the lymph occurs and the rate of backflow is approximately proportional to the intraductal pressure (2). The maximum bile secretion pressure amounts to about 35 cm of water in the dog (3). To force a retrograde into the biliary system infused agent out of the small bile ducts, the maximum bile secretion pressure has to be overcome, or stated differently, the agent has to be infused at a hydrostatic pressure exceeding 35 cm of water (4). If Ethiodol (Savage Laboratories, Inc., Missouri City, Texas), an iodized poppy seed oil used for lymphography, is infused slowly into the biliary system of a dog with a hydrostatic pressure slightly exceeding the biliary excretion pressure, excellent visualization of the deep hepatic lymph drainage was obtained without any complications except for a transient increase of bilirubin and liver enzymes in the serum (5). The purpose of this report is to analyze the deep hepatic lymph drainage of the dog by this new method.

### *Material and Methods*

The investigation was conducted on nine male mongrel dogs weighing 20-44 kg. They were prepared by cholecystectomy and implantation of a modified Thomas cannula (12) in the second portion of the duodenum which allows cannulation of the common bile duct under direct visualization.

---

The paper was presented in part at the 5th International Congress of Lymphology, March 23-29, 1975 in Buenos Aires (Argentina) and Rio de Janeiro (Brasil).

This work was supported in part by American Cancer Society Grant ACS IN-18-P # 183

Acknowledgements: The authors wish to thank Phillip Harnish, B.A., Chief Radiology Laboratory Technologist, for his excellent cooperation in the experimental part of the investigation.

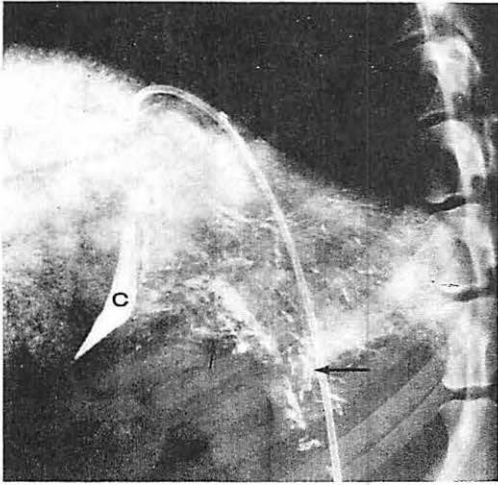


Fig. 1 Dog. No. 4. Lymphangiographic phase. Lateral view. Catheter in inferior vena and hepatic vein. Contrast material left in common bile duct (c). Lymph vessels in porta hepatis (vertical arrow) and along hepatic vein (horizontal arrow).

selective celiac and superior mesenteric angiograms were performed in two projections in all animals for accurate anatomical localization of the opacified lymph nodes.

### Results

At the end of the retrograde contrast material infusion into the biliary system the lymph vessels of the deep hepatic lymph system were already visible. One hour later the cisterna chyli and the thoracic duct were opacified. At the same time beginning contrast material filling of the lymph nodes occurred. Lymph vessels and thoracic duct remained visualized for several hours but were no longer filled with contrast material on the following day. The lymph nodes were at that time well visualized but the opacification still improved slightly over the next few weeks. This was due to the slow release of contrast material stored in the liver parenchyma which caused a dense hepatogram lasting for several weeks. The contrast material density in the lymph nodes began to fade out slowly after about 3 months but all lymph nodes could still be seen adequately one year later.

*Lymphangiographic phase (first day):* In all nine animals numerous lymph vessels were found emerging from the porta hepatis and passing through the hepatic lymph nodes situated along the course of the hepatic artery (Fig. 1). The efferent vessels of the hepatic lymph nodes terminated in the cisterna chyli. Lymph drainage along the hepatic veins was sometimes difficult to identify radiographically because of the dense hepatogram and the superimposition of small bile ducts still containing contrast material. Direct lymph drainage from the liver to a gastric lymph node was observed whenever this node became opacified (Fig. 2). Direct filling of splenic lymph nodes occurred in some instances when these nodes were visualized (Fig. 2). In other cases, however, splenic lymph nodes were opacified by contrast material refluxing to these nodes from the hepatic lymph nodes. Only retrograde contrast material filling occurred in the mesenteric, aortic and iliac nodes. Lymph vessels running over the liver convexity or beneath the diaphragm were never observed. The lymph nodes opacified in the chest were all filled with contrast material from the thoracic duct either via collaterals or in retrograde fashion. Direct retrosternal lymph drainage from the liver to the sternal lymph nodes did not occur.

The procedure was performed under general anesthesia with 25 mg/kg sodium pentobarbital with additional supplements when needed. A Foley catheter French size 8 was introduced via the Thomas cannula in the common bile duct. The balloon of the catheter was inflated to a degree that prevented leakage of bile and contrast material. After aspiration of the bile, the biliary system was filled to capacity with Ethiodol and then an additional 10 ml or slightly more of the contrast agent was infused with a hydrostatic pressure of 50 to 100 cm of water. The contrast material infusion time amounted usually to about 30 minutes.

Anteroposterior and lateral radiographs of the abdomen and chest were routinely taken with standardized technique (focus - film distance 40 inches) before and at regular intervals after completion of the procedure. Additional oblique views were only taken when necessary for better identification of lymph nodes or vessels. About a month later an aortogram and

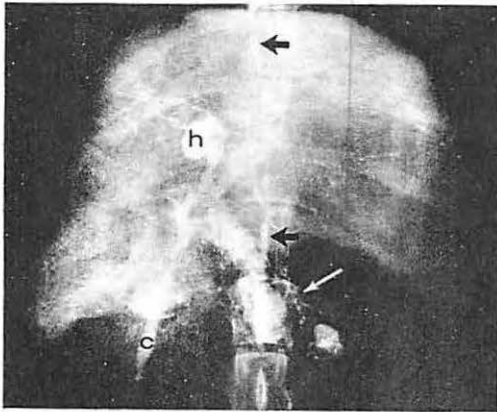


Fig. 2 Dog No. 7. Lymphangiographic phase.  
2a Anteroposterior view. Lymph vessels draining direct to splenic lymph node (with arrow). Thoracic duct (black arrows), common bile duct (c), hepatic ducts (h).

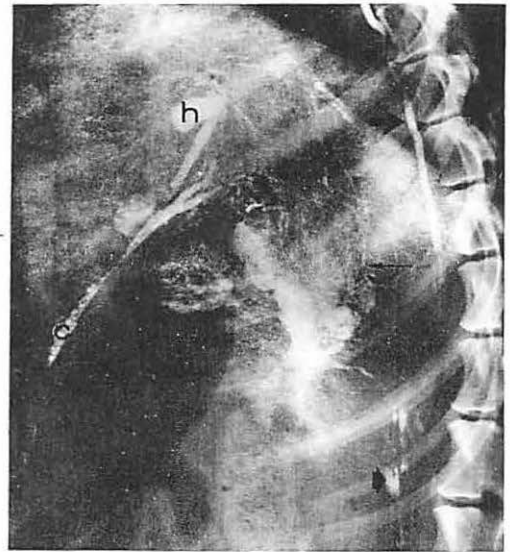


Fig. 2b Lateral view. Lymph vessels draining direct to gastric lymph node (thin arrow). Thoracic duct (large thick arrow), cisterna chyli (small thick arrow), common bile duct (c), hepatic duct (h).

Table 1 Opacified Lymph Nodes After Retrograde Infusion of Ethiodol into the Biliary System.

Dog #	hepatic*	splenic	gastric	mesenteric	Lymph nodes aortic	iliac	tracheo- bronchial	subclavian	sternal
1	9	3	—	—	5	—	1	2	—
2	11	—	—	—	4	—	—	—	1
3	10	1	—	6	2	—	—	—	—
4	9	—	1	12	13	—	4	2	3
5	8	4	—	—	—	—	—	—	—
6	9	5	1	2	11	4	3	1	—
7	6	4	1	2	8	—	—	—	—
8	7	—	—	—	—	—	—	—	—
9	8	1	—	—	2	—	—	—	—

\* The gastroduodenal lymph nodes are included in the hepatic lymph nodes.

*Lymphadenographic phase* (second day and later): The number of opacified lymph nodes in each animal are summarized in Table 1. Between 6 and 11 almost always completely opacified lymph nodes (average 9) were found in the porta hepatis (Fig. 3 and 4). These nodes were arranged in one or two chains along the course of the gastroduodenal and common hepatic artery. They were termed "hepatic lymph nodes" although more correctly they should have been subdivided into gastroduodenal and hepatic nodes. This was however not done because the gastroduodenal artery is the direct continuation of the common hepatic artery after giving off the last proper hepatic artery as a side branch. The hepatic lymph nodes varied in size and shape considerably: Anything between round lymph nodes of a few millimeters in diameter to long and flattened nodes up to 4 cm in length was found.

Between 1 and 5 splenic lymph nodes were opacified in 6 animals (Fig. 4). The degree of opacification varied from only fragmentary to almost complete contrast material filling. These nodes usual-

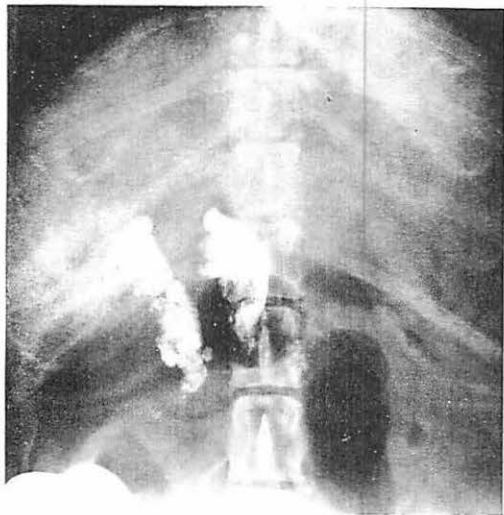


Fig. 3 Dog No. 3. Lymphadenographic phase. Anteroposterior view. Hepatic lymph nodes in two chains.

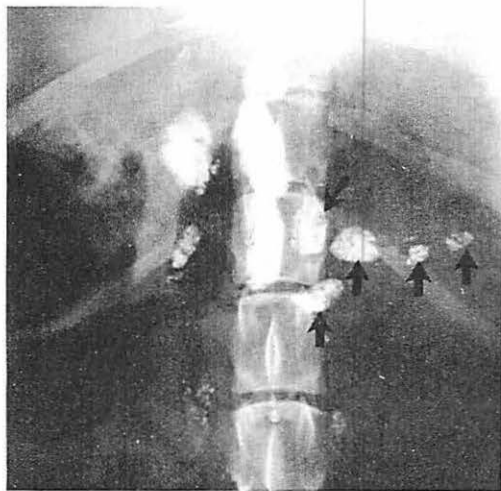

Fig. 4 Dog No. 7. Lymphadenographic phase. 4a Anteroposterior view. Right hepatic lymph node chain incomplete. Left gastric lymph node (oblique arrow). Splenic lymph nodes (vertical arrows).

ly had an ovoid shape and measured up to 1.5 cm in their longest diameter. In each of 3 animals a single gastric lymph node of elliptical shape measuring around 2 cm in its longest diameter was completely opacified (Fig. 4).

Opacification of mesenteric lymph nodes which were situated along the superior mesenteric artery and vein and their branches occurred in 4 animals. These nodes were only fragmentarily opacified and varied greatly in number and size (Fig. 5).

In 7 animals between 2 and 13 very small aortic (lumbar) lymph nodes were incompletely opacified. Included in this group were also lymph nodes located around the take-off of the very short celiac axis. In one animal even iliac lymph nodes were opacified. Tracheobronchial, subclavian and/or sternal lymph nodes were incompletely opacified in 4 animals (Fig. 6).

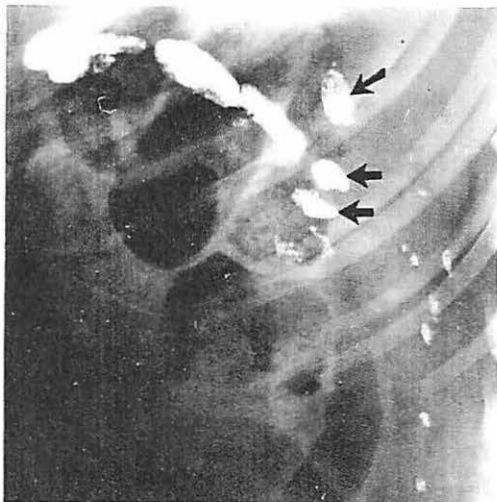

Fig. 4b Lateral view. Left gastric lymph node (oblique arrow). Splenic lymph nodes partially superimposed on each other (horizontal arrows). Multiple small aortic lymph nodes posteriorly.

### Discussion

The hepatic lymph drainage was previously investigated by antegrade or retrograde injection of a dye into a lymph vessel on the liver surface or localized intraparenchymatous dye injections (1, 8, 11). This type of investigation was hampered by the fact that only part of the hepatic lymph drainage was visualized at one time. Intravenous injection of tantalum dust resulted primarily in a hepatosplenogram (9) followed by a slow opacification of hepatic lymph nodes

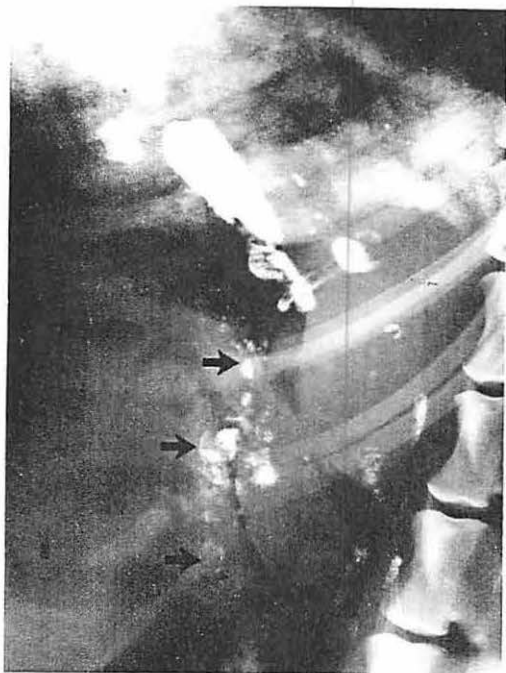


Fig. 5 Dog No. 4. Lymphadenographic phase. Numerous partially filled mesenteric lymph nodes (arrows).

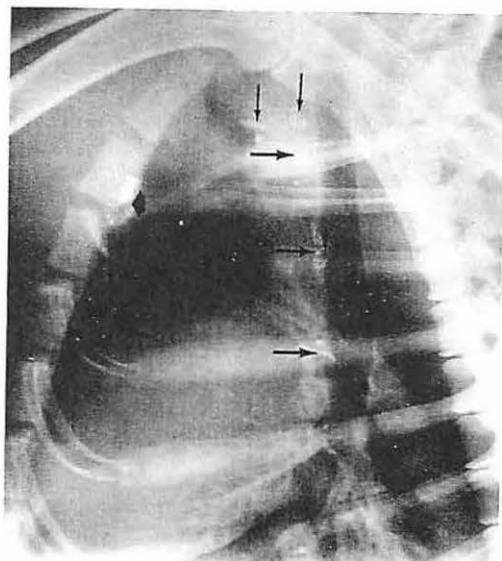


Fig. 6 Dog No. 4. Lymphadenographic phase. Lateral view of the chest. Incomplete opacification of tracheobronchial lymph nodes (thin horizontal arrows), subclavian lymph nodes (thin vertical arrows) and sternal lymph nodes (thick arrow).

within the next 5–14 days (7) or 18–21 days (6), respectively. A rapid radiographic opacification of the entire deep lymph drainage was however possible with our method, since an even intrahepatic distribution of the contrast agent was instantly obtained by its retrograde biliary infusion. It is therefore not surprising that our results differ to some degree from previous reports.

The lymph drainage of the liver is divided into a superficial and deep system. The superficial lymph vessels run in the subserous areolar tissue over the whole surface of the organ (13). The lymph vessels of liver convexity of the dog reach the inferior surface of the diaphragm via the coronary, triangular and falciform ligaments and run beneath the diaphragm to the upper aortic lymph nodes or join the deep lymph vessels of the liver when they emerge on the liver surface with the hepatic veins (1). In man however the lymph vessels draining the anterior part of the liver convexity penetrate the diaphragm between its sternocostal insertions and drain along the course of the internal mammary arteries to the sternal lymph nodes (11). The superficial lymph vessels of the visceral hepatic surface drain to the porta hepatis in both man and dog (1, 8).

The deep lymph vessels form ascending and descending trunks. The ascending trunks accompany the hepatic veins and the descending trunks emerge from the porta hepatis and end in the hepatic lymph nodes (13). The efferents pass in man through the celiac lymph nodes and in the dog directly to the cisterna chyli (1, 13).

Anastomoses between the superficial and deep hepatic lymph system are scarce in man (8) and selective contrast material injection into superficial lymph vessels never resulted in visualization of the deep system (11). A large portion of the superficial lymphatics of the canine liver penetrates into the liver parenchyma and drain the lymph into the deep system (1). Lymph flow in the opposite direction, that is from the deep to the superficial system did however not occur in our experiment.

Eighty percent of the hepatic lymph in the dog drains to the porta hepatis and the remaining 20% travels by the hepatic venous lymph route (10). Accordingly the best and most constant opacification occurred in our experiment in the hepatic lymph nodes. The number of opacified hepatic lymph nodes (portal lymph nodes of *Baum*) varied in our experiment between 6 and 11 (average 9) and was significantly greater than what was found in previous anatomical studies in the dog. *Baum* (1) reported two hepatic lymph node groups situated on each side of the portal vein and its tributaries. The right group consisted of 1 to 5 lymph nodes and the left usually of 1 and rarely of 2 or 3 nodes (1). *Ritchie* and coworkers (10) subdivided the hepatic lymph drainage to the porta hepatis into a main hilar and an accessory hilar lymph system. Lymph from the right liver lobes drains according to these authors in 92% to a single hepatic lymph node, in the remaining cases to 2 or 3 hepatic lymph nodes. The accessory hilar lymph system drains the remaining lymphatics of the liver in the porta and consists in 88% of 2 nodes, in the remaining cases between 1 and 4. The reason why more hepatic lymph nodes are found radiographically is probably due to the fact that small nodes embedded in fat can easily escape anatomical detection.

Lymph vessels accompanying the hepatic veins ascend in man through the diaphragmatic hiatus for the vena cava and enter the thoracic duct directly or after passing through lymph nodes at the termination of the inferior vena cava (13). The difference from our experiment in the dog is that those lymph vessels always terminate in the thoracic duct below the diaphragm or in the cisterna chyli, respectively. In one third of the animals direct opacification of a gastric lymph node in the lesser curvature occurs, presumably via the cardia and the lesser omentum. This lymph node is according to *Baum* (1) not constantly present in the dog. The splenic lymph nodes are more often visualized. Their opacification occurs by two entirely different routes: 1) in direct (antegrade) fashion from the hepatic venous lymphatic system similar to the left gastric lymph node and 2) from the porta hepatis via hepatic lymph nodes by contrast material reflux. Despite the fact that the lymph vessels possess valves to direct the flow, retrograde contrast material filling of the aortic and mesenteric nodes is found frequently too but these nodes are usually incompletely opacified. Occasionally the contrast material can even reflux back to the iliac lymph nodes. Retrograde lymph flow might be an important route in the lymphangitic spread of hepatic infections and tumors.

### *Conclusion*

1. Excellent experimental opacification of the deep hepatic lymph system can be obtained by retrograde infusion of Ethiodol into the biliary tree with a hydrostatic pressure exceeding the biliary excretion pressure slightly.
2. Primary lymph stations of the deep hepatic system of the dog are the hepatic, gastric and splenic lymph nodes. The latter two are however not constantly opacified.
3. The number of hepatic lymph nodes varies in the dog between six and eleven (average 9) and is significantly higher than previously reported in anatomical investigations.
4. Retrograde filling of splenic, mesenteric, aortic and iliac lymph nodes occurs in a significant number of dogs with retrograde biliary Ethiodol infusion.
5. No lymph drainage through anastomoses from the deep to the superficial hepatic lymph system is found with the described method in the healthy dog.



## References

- 1 *Baum, H.*: Lymphgefäßsystem des Hundes. August Hirschwald Verlag, Berlin 1918
- 2 *Brauer, R.W., G.F. Leong, R.J. Holloway*: Mechanics of bile secretion. Effect of perfusion pressure and temperature on bile flow and bile secretion pressure. *Am. J. Physiol.* 177 (1954) 103-112
- 3 *Burgener, F.A., H.W. Fischer, J.T. Adams*: Intravenous cholangiography in different degrees of common bile duct obstruction. *Invest. Radiol.* 10 (1975) 342-350
- 4 *Burgener, F.A., H.W. Fischer*: Retrograde hepatography and indirect lymphography of the liver. *Radiology* 116 (1975) 441-444
- 5 *Burgener, F.A., S.I. Schabel*: Indirect liver lymphography. Letter to the Editor. *Lancet* (Aug. 9 (1975) 281-282
- 6 *Davaris, P., F. Huth*: Die röntgenologische Darstellung der Leber und der Milz im Experiment mit Tantalpulver. *Fortschr. Röntgenstr.* 114 (1971) 119-126
- 7 *Dumont, A.E., A. Martelli*: X-ray opacification of hepatic lymph nodes following intravenous injection of Tantalum dust. *Lymphology* 2 (1969) 91-95
- 8 *Hass, H.*: Die Architektur der Lymphgefäße der Leberkapsel in ihren Beziehungen zur Bindegewebsstruktur und Flüssigkeitsströmung. *Virchow's Arch. Pathol. Anat.* 297 (1936) 384-403
- 9 *Huth, F., A. Wilde, H.J. Schulten, et al.*: X-ray, light and electron microscopic observations in experimental lymphostasis of the liver. *Angiologica* 9 (1972) 40-52
- 10 *Ritchie, H.D., J.H. Grindlay, J.L. Bollman*: Flow of lymph from the canine liver. *Am. J. Physiol.* 196 (1959) 105-109
- 11 *Taenzer, V., J. Meyer-Burg*: Die retrosternale Lymphographie. *Fortschr. Röntgenstr.* 120 (1974) 389-395
- 12 *Thomas, J.E.*: An improved cannula for gastric and intestinal fistulas. *Proc. Soc. Exp. Biol. Med.* 46 (1941) 260-261
- 13 *Warwick, R., P.L. Williams*: *Gray's Anatomy*. Saunders, Philadelphia, 35th British ed., 1975

*F.A. Burgener, Radiology Department, Strong Memorial Hospital, Rochester, New York 14642*