

Role of Lymphography in Management of Filarial Chyluria

G.M. Gandhi

Reader in Surgery, M.R. Medical College, Gulbarga (Karnataka) India

Summary

1. One hundred patients with chyluria were studied with lymphography and 80 cases were followed up for a period varying between six months to two and one half years.
2. There was preponderance of left sided lesions. The site of fistulations were mostly in the region of pelvis and calyces of the kidney.
3. It was observed that lymphography was very useful in treatment of chyluria. Thirty-eight patients (48%) with chyluria were completely free from symptoms and after lymphography, 23 (28%) of them had relief and 19 (24%) of the patients did not have any beneficial effect after lymphography. This procedure was of great help in demonstrating the site of fistulations which could be surgically corrected, in certain situations.
4. Lymphographic appearances of thoracic duct was helpful in deciding the operation of thoracic duct jugular vein anastomosis in some cases.
5. Lymphatico venous anastomosis was done in 3 patients at the root of the scrotum in whom retrograde flow of contrast material occurred into the testicular lymphatics on lymphography.

The main value of lymphography in chyluria according to *Karanjawala* (3) is in the demonstration of lymphatico urinary tract fistulations whereas *Akisada* and *Tani* (2) believe that lymphography in chyluria has certain therapeutic effects. The present report is in continuation of our earlier observations on lymphography in chyluria.

Materials and Methods

One hundred and thirty cases of chyluria were investigated and of these in only 100 cases complete investigations could be done and the remaining 30 are not included in the present study. Our of 100 cases, 85 were males and 15 females (Table 1). The criteria for selection were persistent chyluria with weight loss and recurrent urinary infection in spite of diethylcarbamazine and urinary anti-septics. Chyluria was intermittent and periods of remission varied between one month to three months. Seventyeight patients had haemochyluria and the rest had chyluria alone. Associated lesions like chylous hydroceles, filarial scrotum with lymphatic vesicles and chylous reflux were noted (Table 2). In one patient who presented with acute chylous peritonitis histopathological examination of retroperitoneal lymph nodes revealed the presence of adult worms. *Microfilaria* were demonstrated

in blood in 60 cases but they could be seen in urine in 8 cases only. Estimation of proteins in the urine varied between 37 G/Lit to 12 G/Lit. Majority of the patients were cystoscopically examined before submitting them to lymphography. The lymphography was performed by modified Kinmonth's technique under local anaesthesia with 10 ml. of lipiodol ultra fluid for

Table 1

Materials and Methods Lymphograms Performed	
Bipedal	83
Unilateral	17
Total	100
Males	85
Females	15

Table 2

Mode of Presentation	
Haemodhyluria	78
Chyluria	22
Total	100
Chylous Hydroceles	26
Filarial Scrotum with Lymphatic Vesicles and Chylous Reflux	10
Acute Chylous Peritonitis	2
Total	38

Table 3 Observations (Retroperitoneal lymphatics).

	Right side	Left side	Bilateral
Lymphatico pelvic and lymphaticorenal fistulations	6	30	27
Lymphatico ureteric fistulations	0	3	0
Lymphatico vesical fistulations	0	2	0
Retrograde flow of contrast into the testicular lymphatics	0	4	6

each limb. Bilateral foot lymphography was done in 83 cases and unilateral in 17 cases. Serial radiographs of pelvis, abdomen, and chest were taken at the end of the injection. Repeat X-rays were taken 12 hours, 24 hours, and 48 hours after the injection. All the patients complained of presence of patent blue in stool and urine for 4 to 5 days. Eighty patients were followed up for a period varying between six months to two and one half years. The rest of the cases were not taken for follow up because lymphography was done very recently or the patients were lost to follow up.

Observations

Retroperitoneal lymphatics (Table 3). There was marked tendency for the dye to cross over to the opposite side opacifying the contralateral side in 12 cases where unilateral foot lymphogram was done. In ten cases intrarenal lymphatics of both the kidneys could be demonstrated by unilateral injection. In 30 cases the lymphaticorenal, lymphaticopelvic fistulations were noted on the right side alone. The reflux towards both the kidneys was noted in 27 cases with the contrast material outlining the base of papillocaalyceal grooves in circles, semicircles, and coral forms (Fig. 1a and b). In two patients, abnormal lymphatics were seen coursing down the ureter and

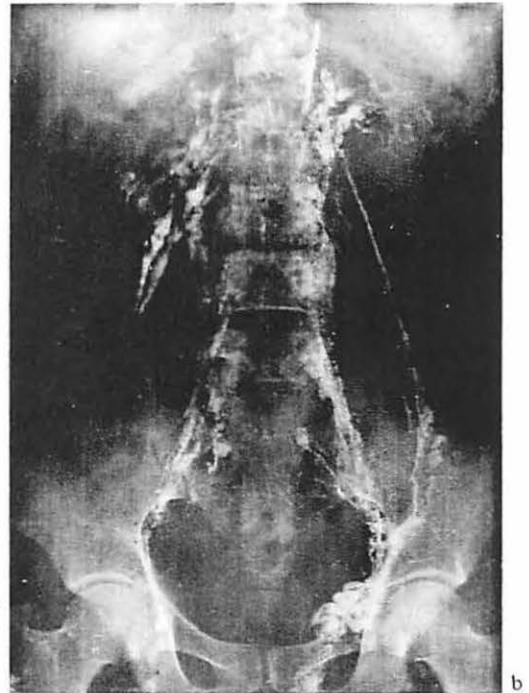
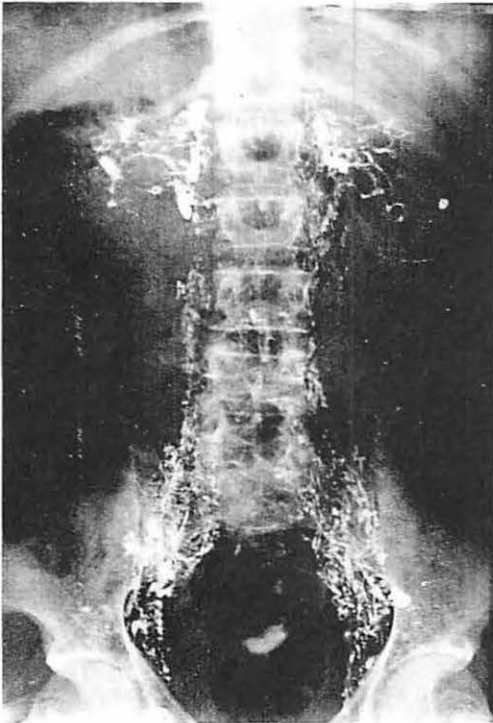


Fig. 1 (a) Lymphogram showing reflux of contrast toward both the kidneys with lipiodol cystogram.
(b) Lymphogram showing lymphatico-renal fistulations with retrograde flow of contrast into the testicular lymphatics.

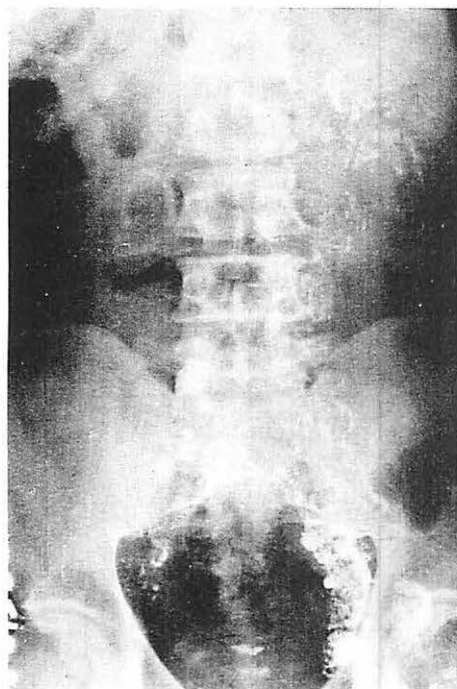


Fig. 2 Abnormal lymphatics coursing down the ureter, on the left side with renolymphatic communications.

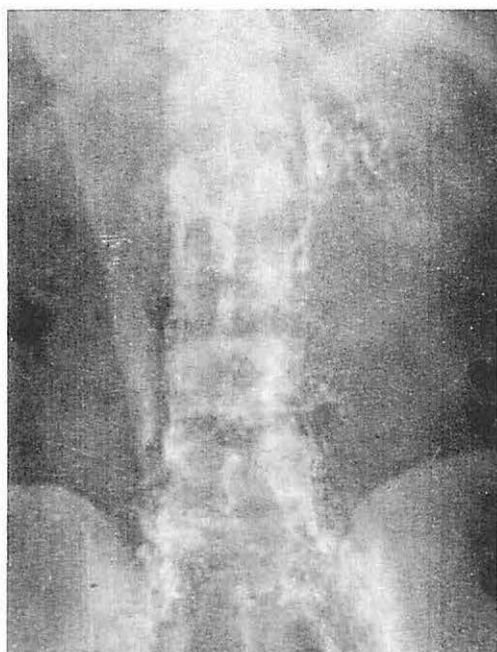

Fig. 3 Lymphogram showing the lymphatics entering the middle of the ureter on the left side and lymphatico pelvic fistulations.

in one patient lymphatics entering the ureter at its middle could be detected both on the left side only. (Fig. 2 and 3). Lymphatico vesical fistulae were noted in two patients that too on the left side (Fig. 4). In eight cases with the lymphatico pelvic fistulations, lipiodol cystogram could be detected (Fig. 1).

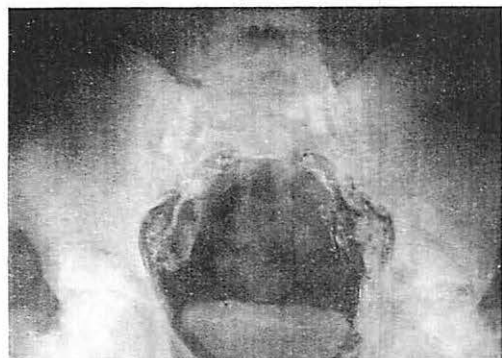


Fig. 4 Lymphatico vesical fistulae on left side with cystogram.

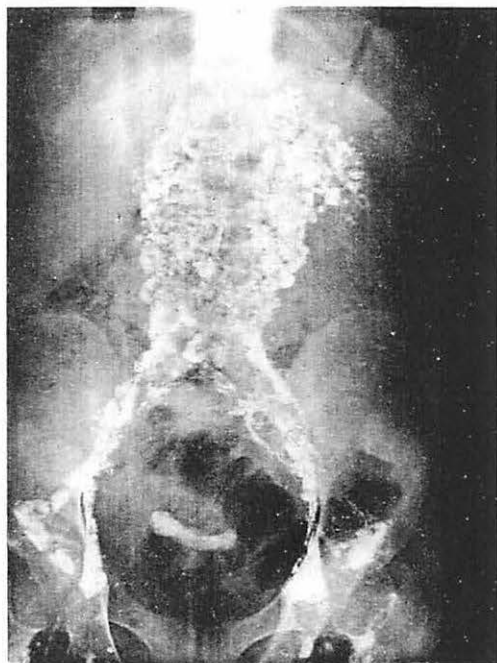


Fig 5 Dilated lymphatics in the retroperitoneal area looking like veins with reflux of dye towards left kidney and lipiodol cystogram.

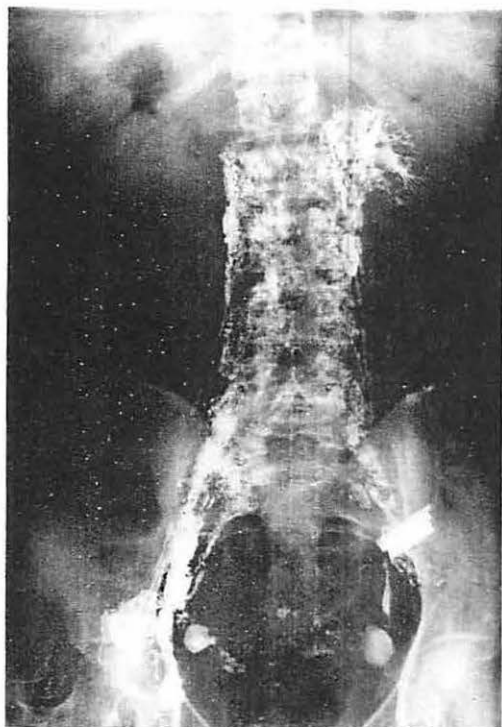


Fig. 6 Lymphogram showing lymphaticorenal fistulations in the form of circles and semi-circles.

Table 4

Observations on thoracic duct

Width of thoracic duct

at the commencement - 6 to 11 mm. (average 8 1/2 mm)

at the termination 5 to 9 mm. (average 7 mm)

Appearances of the thoracic duct

1. Accordian like appearances due to segmental dilatation and abrupt narrowing at the last two inches of the duct.
2. Laceration of thoracic duct at the termination with retrograde flow into subclavian lymph trunk and jugular lymph trunk.
3. Beaded appearance with abrupt dilatation at the termination.
4. Cavernoma like appearance at the termination
5. Y shaped bifurcation at mid thoracic level.

Thoracic duct: (Table 4) in the majority of cases thoracic duct was markedly dilated in the terminal four to five inches with abrupt narrowing at its junction with the subclavian vein (Fig. 8a and b). In two cases there was retrograde flow of contrast material of one into the upper

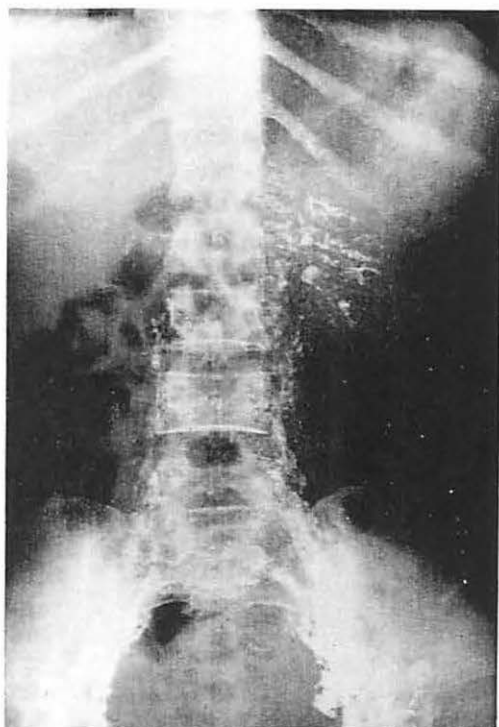


Fig. 7 Repeat X-ray of Fig. 6 taken seven days after lymphography showing the contrast clearing from lymph nodes and retroperitoneal lymphatics but the contrast remained within the fistulous communications.

In the majority of cases the retroperitoneal lymphatics were greatly dilated and looked like veins (Fig. 5). In the rest of the cases the contrast did not ascend beyond the common iliac lymph nodes, but the inguinal lymphatics were markedly dilated and became tortuous. Retrograde flow of contrast material into the left side testicular lymphatics was present in 4 cases and the contrast material flowed into both sides in six patients. Lymphatics crossing over to the opposite side in the supra pubic region was also noted. Repeat X-rays taken 7 days after lymphography showed the contrast clearing from lymph nodes and retroperitoneal lymphatics but the contrast remained within the fistulous communications (Fig. 6 and 7).

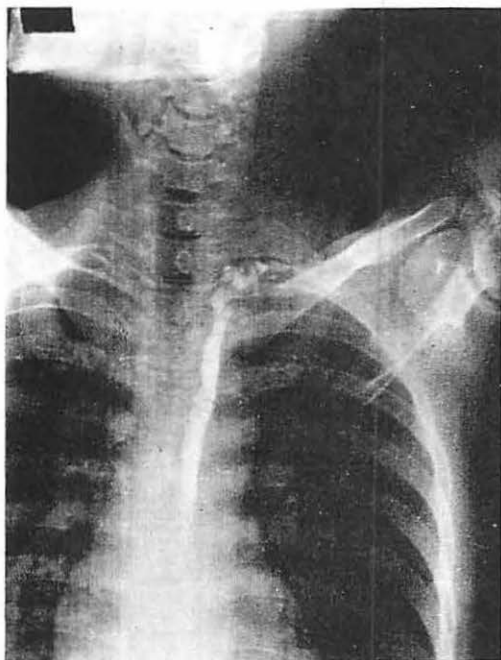
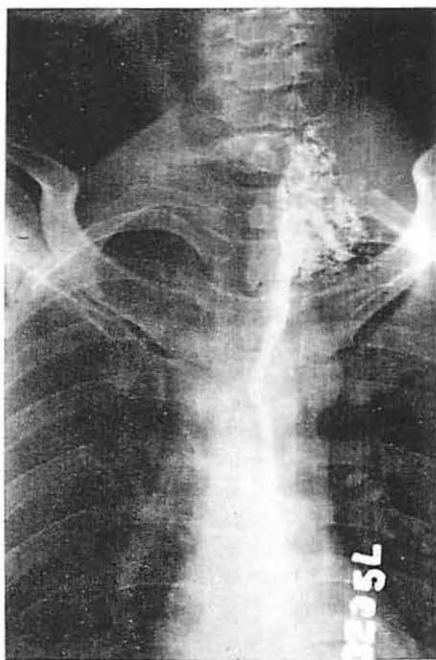
Fig. 8 (a) Lymphogram showing thoracic duct greatly dilated in the last six inches.



(b) Greatly dilated thoracic duct with funnel shaped termination.

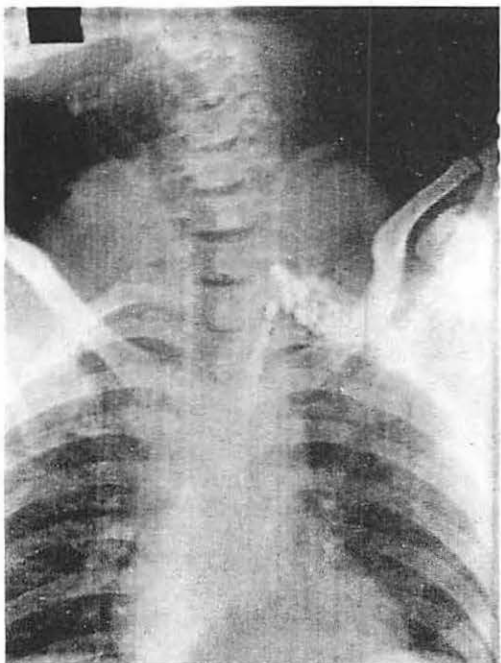
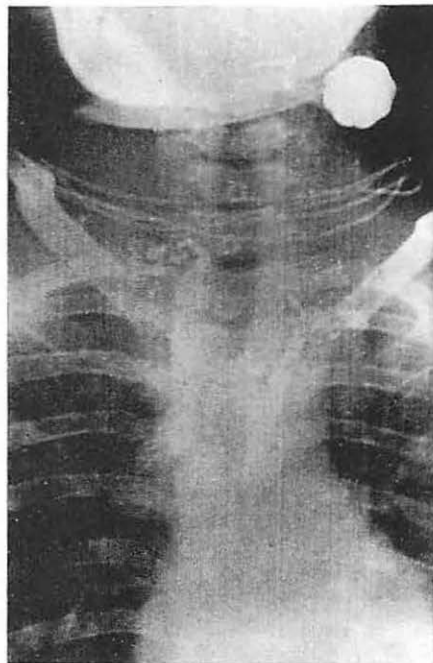
Fig. 9 (a) Cavernomatous formation of thoracic duct at the termination.



b) Y shaped bifurcation of thoracic duct at mid thorax with the branches entering jugular veins separately.

Table 5 Follow up of 80 patients

Follow up of 80 patients	Symptom free	Partial relief	No relief
6 months	8	5	6
12-18 months	10	8	10
24 months and above	20	10	3
Total	38 (48%)	23 (28%)	19 (24%)

limb lymphatics and in another case the retrograde flow was into the jugular trunk. In seven cases the terminal portion gave a cavernoma like picture (Fig. 9a). In four cases the duct was split up like Y at mid thorax and entered the jugular veins separately (Fig. 9b).

Follow up

Thirty eight (48%) patients were totally free from chyluria for a period varying between six months and two and one half years after lymphography alone (Table 5). Out of these 38 patients 26 had unilateral lesions and 12 had bilateral lesions. In 23 patients (28%) the chyluria and chylohaematuria was less in frequency, remissions were of longer duration and they had gained weight. These patients with partial relief felt very much better symptomatically after lymphography. In the remaining 19 (24%) patients there was no significant beneficial effect and they were lost for follow up after six months.

Unilateral disconnection and stripping of the lymphatics entering the kidney and the pelvis was done in seven patients who had no relief from chyluria after lymphography. Four of these patients are free from chyluria for the last one year, and the other three returned with recurrence of chyluria after 4 to 5 months of remission. Lymphography performed in these patients who had disconnection of renolymphatic fistulations showed dilated lymphatics in the region of pelvis of both the kidneys without evidences of actual fistulous communications (Fig. 10). Thoracic duct jugular vein anastomosis was performed in three patients who had no relief with lymphography and disconnection of renolymphatic communications. These three patients have been free from chyluria for the last five months. In patients where reflux of contrast material occurred into the testicular lymphatics on lymphography and who were not free from chyluria anastomosis between dilated testicular lymphatics and pampiniform plexuses of veins were performed in three cases, at the root of the scrotum.

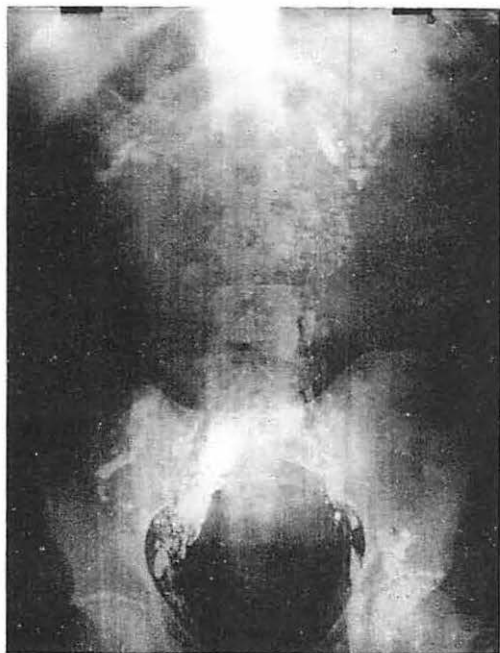


Fig. 10 Lymphogram performed after renolymphatic communications disconnected showing dilated lymphatics in the region of pelvis of both the kidneys without evidence of actual fistulous communications.

Discussion

Garter in 1862 and a year later Ackerman (1) independently suggested that chyluria is caused by lymphatic obstruction above the level of intestinal chyle entry with subsequent fistulous communications between the lymphatic system and the urinary tract. This hypothesis was

later substantiated by pathological studies by *Manson* (6). According to *Karanjawala* (3) the chyluria is due to lymphatic obstruction which is wide spread throughout the retroperitoneal nodes and tissues, which leads to lymphatic hypertension with consequent development of abnormal and dilated collateral channels. The chyle then flows towards the kidney in retrograde manner causing chyluria. In the present series also most of the patients complained of the presence of patent blue in the stools and urine for two to three days after lymphography substantiating the view of the existence of free communication between lymphatics of retroperitoneal area, lymphatics of intestinal tract and the urinary tract. In our cases where we noticed demonstrable fistulations very few retroperitoneal lymph nodes are demonstrated on lymphography. In cases where the thoracic duct abnormalities are noted a large number of retroperitoneal lymph nodes are outlined along with the fistulous communications.

Kitagawa and *Ohmori* (4) 1935 reporting chyluria from southern Japan as quoted by *Kao* and *Van Langenberg* (5) could demonstrate microfilariae in urine in only 39% of cases and 21% in the blood. Whereas *Karanjawala* (3) reported that microfilaria in the blood were detected in most of the cases and in the urine they were detected in 30% of the cases.

In the present series microfilaria in blood were found in 70% of the cases but they could be detected in urine in eight patients only.

The classical lymphographic picture is the demonstration of lymphatic urinary fistulations at the level of kidney, ureter, or bladder. However, the majority of the authors observed the fistulations at the level of pelvis of the kidney. *Koo* and *Van Langenberg* (5) noted lymphatic urinary fistulations more on the right side. In the present series left side lesions were predominant. No specific reasons for this preponderance can be attributed.

In normal subjects the width of the thoracic duct at the commencement is five mm but it diminishes considerably in calibre in the middle of the thorax and in about half the cases it is again slightly dilated just before its termination. *Karanjawala* (3) noted that in most of the cases the thoracic duct was markedly dilated in terminal four inches with abrupt narrowing at the junction with the subclavian vein and retrograde flow into the supraclavicular nodes, whereas *Koo* and *Van Langenberg* (5) noted the thoracic duct to be normal in their cases. In the present series the average diameter of the thoracic duct at the commencement was 8½ mm and at the termination was 7 mm. Thoracic duct was not visualized in those cases where the dye did not ascend beyond the common iliac group of lymph nodes. Various types of thoracic duct abnormalities were noted at the termination as shown in the table.

The importance of lymphography in chyluria is the demonstration of the site of the pathological anatomy since this locates the scientific basis for surgical stripping of renal pedicle as the treatment for chyluria (*Koo* and *Van Langenberg* [5]). *Karanjawala* (3) is of the opinion that this resection of the renolymphatic communications is a good procedure and a few of his cases had prolonged relief although it did not do away with the basic pathology. However, when the lesions are bilateral he advocates thoracic duct jugular vein anastomosis.

In the present series resection of the lymphatic communications were performed in 7 patients who had no beneficial effect on lymphography. Out of these 7 patients 3 patients had recurrence of chyluria after 4 months. In these 3 patients lymphography was repeated and it showed dilated lymphatics in the region of both the kidneys without actual demonstration of lymphatic renal fistulous communications. Later on these patients were subjected to thoracic duct jugular vein anastomosis as a last resort and they are free from chyluria for the last 4 months. In three other patients with retrograde flow of contrast material into the testicular lymphatics on lymphography, anastomosis between the dilated testicular lymphatics and the pampiniform plexus of veins were performed unilaterally. These patients are free from chyluria for the last 6 months.

With these observations it is felt that thoracic duct jugular vein anastomosis is a more difficult

and dangerous procedure and it may be used as a last method of choice, only when all the other available methods are met with failure. Whereas lymphaticovenous anastomosis at the root of the scrotum may be performed easily without any serious complications. The disadvantage of this procedure is that it cannot be used in those cases in which there is no retrograde flow of contrast material on lymphography. When there is no appreciable lymphatic hypertension in the testicular lymphatics the lymph does not flow into the veins freely, where this procedure is likely to be a failure.

Akisada and *Tani* (2) reported that lymphography has certain therapeutic effects. Thirty cases were studied by them and 18 were followed up, out of which 67% had cessation or marked decrease in symptoms after lymphography in filarial chyluria patients and the rest had no beneficial effect. In the present series 38 (48%) patients got complete relief of symptoms for a period varying between six months to two and one half years after lymphography. In another (28%) 23 cases there was marked improvement in the intensity of the symptoms. All these patients gained weight. In (24%) 19 patients having bilateral extensive lesions no relief was noted. The intensity of chyluria decreased by 48 to 72 hours after lymphography and it completely disappeared after 20 to 30 days. It is observed, by the histopathological examination of lymphatic communications two months after lymphography showed that, cessation of chyluria by lymphography may be brought about by three mechanisms. 1. Coagulation of proteins of chyle within the renolymphatic communications produced by the iodine content of the lipiodol ultra fluid. 2. Fibrosis within the renolymphatic communications due to irritation (aseptic inflammation) produced by the iodine content of the lipiodol ultra fluid which remains in the fistulous communications even after 7 days of lymphography. 3. Infection introduced accidentally during the injection of the contrast over a period of 2 to 3 hours leading to lymphangitis and fibrosis of the lymphatic urinary fistulations. Due to this reasons majority of the patients complained of fever and chills for 4 to 5 days after lymphography and histopathological examination of the resected lymphatic communications showed fibrosis in the walls of lymphatics.

References

- 1 *Ackerman, T.*: Ein Fall von Galakturie (Urina chylosa). Deutsche Klinik, 15 (1863) 233 (Quoted by No. 3 *Karanjavala*)
- 2 *Masayoshi, A., S. Tani*: Filarial Chyluria in Japan. Radiology 90 (1968) 311
- 3 *Karanjavala, D.K.*: Lymphangiography in the management of filarial chyluria. Ann. Roy. Coll. Surg. 46 (1970) 267
- 4 *Kitagawa, M., S. Ohmori*: Jap. J. Urol. 24 (1935) 90 (Quoted by No. 5 *Koo and Van Langenberg*).
- 5 *Koo, C.G., A. Van Langenberg*: Chyluria a clinical study. J. Roy. Coll. Surg. (Edinburgh) 14 (1969) 31
- 6 *Manson-Bahr*: "Tropical Diseases" – Filariasis, pp. 667-691. London Balliere, Tindall and Cassell, 1966

Dr. G.M. Gandhi, M.D., Clinical Associate in the Dept. of Surgery, Division of Surgical Oncology at University, Illinois Medical Center. Chicago, Illinois 60616, U.S.A.