

Contribution to the Solution of the Question of Lympho-venous Anastomoses in Heart of Dog

O. Eliška, M. Elišková

Anatomical Institute, Charles University, U nemocnice 3, Prague 2, Czechoslovakia
Head: Prof. R. Čihák, DrSc.

Summary

The efferent lymphatic vessels of the heart were ligated in 35 dogs and afterwards the systems of lymphatic and blood vessels were filled with various media by injection. Twelve of these dogs were sacrificed 30 min. after ligation and the remaining 23 dogs were left to survive for two to 132 days.

After acute ligation of lymph routes, no lymphatic anastomoses could be found. In the protracted experiment, lympho-lymphatic anastomoses had developed between the interrupted trunks and very thin ones at the sites of adhesions between the epicardium and pericardium by the seventh to 14th day. In five out of 23 dogs, lymphovenous anastomoses of a calibre of 40-60 μm . were found between the seventh and 28th day after ligation. After one month, these LVA could no longer be found. Both forms of anastomoses, i.e. lympho-lymphatic and lymphovenous, may be present at the same time. The mutual relationship between these forms was discussed in the paper.

Most papers on lymphatic vessels of the heart deal with the occurrence of lymphatic vessels in the heart of man and various mammals and the relations between the lymphatic networks of the myocardium, the endocardium and the subepicardial networks (1, 4, 6, 8, 9, 10, 14, 17). The lymphatic vessels of the cardiac valves are subject of number of papers (2, 3, 13, 17). Another group of authors have dealt with the changes in lymphatic vessels under pathological conditions in man and in experiments on animals (4, 5, 10, 13-15, 18-21, 24, 27).

In the last decade attention has been concentrated on the evidence of lymphovenous anastomoses (LVA) in the heart. The opinions as to their existence differ: Some authors deny the presence of LVA under normal conditions (*Johnson et Blake*, in man, 1968). Another group of authors confirm their presence. Among them are *Vajda et al.* (1972) who described numerous LVA in the epicardium of man and hog; in hog, *Johnson et Blake* (1968) also described LVA. A third group of authors found LVA in the heart under altered circulatory conditions: *Zerbino et Gavriš* (1970) showed that LVA usually existed in obstruction of lymph in the canine heart. Because of the contradictions in these opinions, the authors of this communication have asked themselves the question, as to whether or not and under what conditions do LVA develop in the heart of dog.

Material and Method

In 35 dogs patent blue was injected after thoracotomy carried out under general anaesthesia in order to demonstrate the course of the lymphatic vessels of the heart. Then the main lymphatic trunks in the cardiac atria, the aorta and the truncus pulmonalis (Fig 1) were ligated and severed. The dogs were divided into two groups: one of the acute and the other of the chronic experiment. The animals of the acute group (dogs 1-12) were sacrificed 30 min. after ligation of the lymphatic vessels. Immediately after death, a mixture of India ink and 4% gelatine was injected into the lymphatic vessels demonstrated by patent blue. The lymphatic vessels were filled with a pressure of 30-100 mm H₂O; when pressure rose to more than 200 mm H₂O, damage to lymph vessels and extravasation occurred. Approximately in one half of the heart specimens, this injection was supplemented by an intravenous injection of 6% gelatine containing a pigment dye. In the chronic experiment (dogs 13-35) the animals were left to survive ligation of lymphatic trunks for 2 to 132 days. After certain intervals some of the animals were

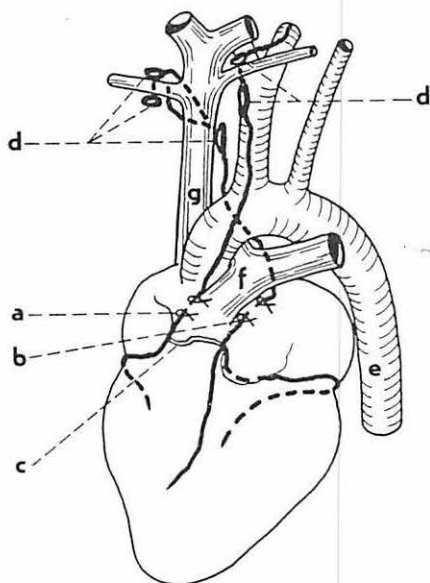


Fig. 1 Course and site of ligature of cardiac lymphatic trunks

- a) site of truncus lymphaticus cordis dexter ligature
- b) site of truncus lymphaticus cordis sinister ligature
- c) shunt between right and left truncus lymphaticus cordis
- d) anterior lymph nodes of the mediastinum
- e) aorta
- f) truncus pulmonalis
- g) superior vena cava

sacrificed and the cardiac lymphatic vessels, demonstrated by patent blue, were injected India ink plus 4% gelatine (13 specimens) or a mixture of UF lipiodol plus Gerot's mass (10 specimens). Out of a total of 23 heart specimens, in nine even the arteries and veins were injected gelatine plus pigment dye or a mixture of filtrated barium plus minium in gelatine. The method of injecting lymphatic vessels with Gerot's mass into the interstice was used in four heart specimens and was abandoned as unsuitable for the given investigation (see discussion). After injection the specimens of heart of both groups were fixed in formol and clarified according to Spalteholz. The specimens with lymphatic vessels injected with UF lipiodol were X-rayed prior to fixation.

Observations

In the group of acute experiments (12 dogs)

penetration of gelatine plus India ink into the venous bed was never observed after direct injection of the mixture into the subepicardial lymphatic vessels. Neither did it happen in the reversed procedure, i.e. after injection of coronary arteries and veins; the mixture did not penetrate into the lymphatic vessels, although the capillary network was well filled. From these findings, the following conclusion may be drawn: In normal heart no lympho-venous anastomoses are present. In direct injection of lymphatic vessels, the injected substance spreads from the apex towards the base of the heart; in retrograde injection, the lymphatic vessels are not filled at all because of the well functioning valves, and if the pressure increases, the wall bursts and extravasation takes place.

In the second group of 23 dogs surviving ligation of the cardiac lymphatic trunks for 2-132 days, the following changes were observed: The subepicardial lymphatic vessels were dilated, varicose and tortuous. By the second or third day even some of the side branches of main trunks were partly filled after retrograde injection. This collateral filling of the lymphatic network was the rule in all cases observed. The shunts between lymphatic trunks and their branches were made visible (between the anterior and posterior left and those of the right truncus). The collateral between the right and left truncus lymphaticus, running across the origin of the truncus pulmonalis (Fig. 1) was obviously thickened. Between the

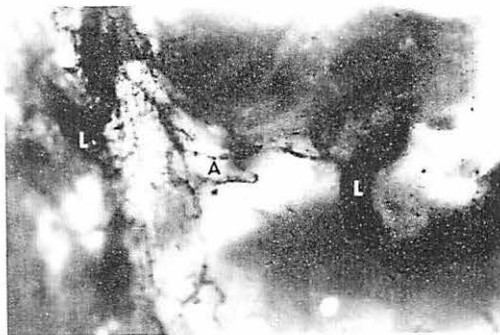
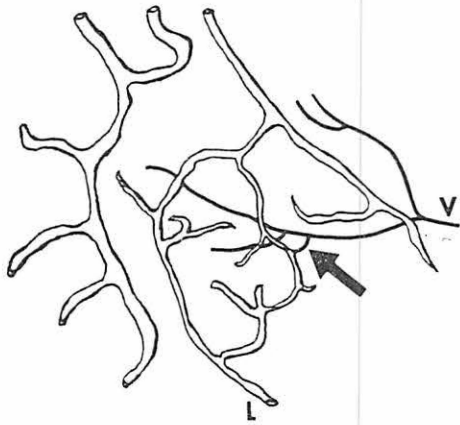
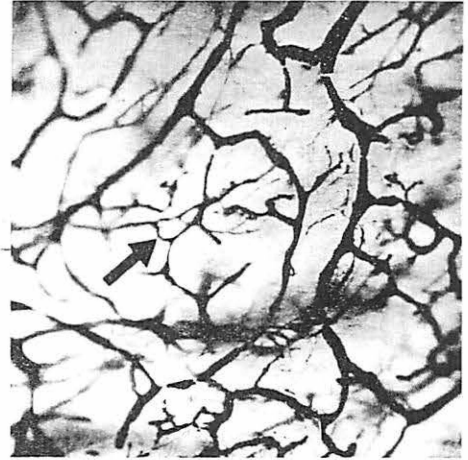

Fig. 2 Newly developed lympho-lymphatic anastomoses between the stumps of the truncus lymphaticus cordis sinister, of 100 μm . calibre. Clarified specimen 14 days after ligation.



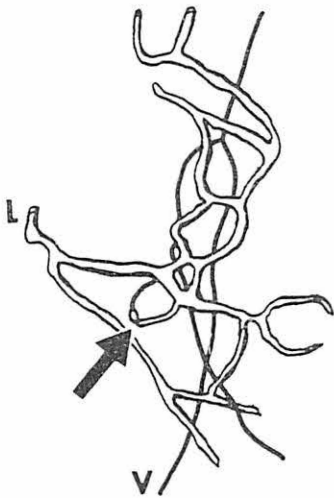
a



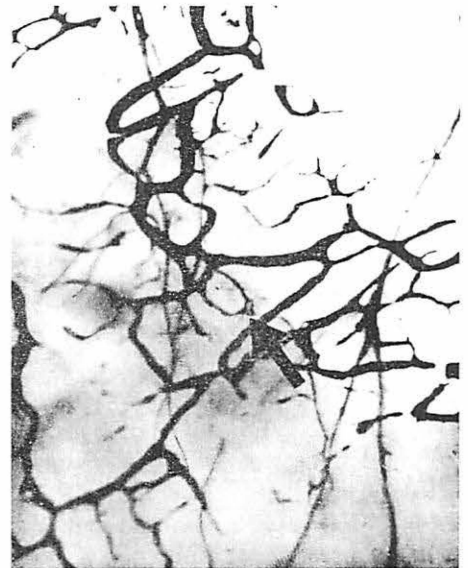b

Fig. 3 Lympho-venous anastomosis, 50 μm . in calibre, in a clarified specimen on seventh day after ligation of lymphatic trunks.

seventh and 14th day lympho-lymphatic anastomoses started to develop between the regions below and above the ligation, first as a network of thin, later of thick vessels (Between the aorta and the truncus pulmonalis (Fig. 2). Slight diffuse permeation of patent blue was also observed from the seventh day after operation in the disrupted adhesions of the pericardium with the epicardium. This also suggested that new lymphatic shunts had developed. Lympho-lymphatic anastomoses linked up with lymphatic vessels running towards the anterior mediastinal and tracheobronchial nodes. In five heart specimens (7, 7, 12, 14, 28 days after ligation) shunts between lymphatic vessels and a vein were observed. Their presence was already signified



a



b

Fig. 4 Lympho-venous anastomosis in the shape of a loop, of 30 μm . calibre, clarified specimen on 14th day after ligation of lymphatic trunks.

in direct injection of lymphatic vessels by the permeation of the injected mass into the vein. In clarified specimens direct anastomoses between lymphatic vessels and veins were found, branching off the lymphatic vessels as an arch opening into a vein running deeper (Figs. 3 and 4). Some of the arched anastomoses split up into smaller branches, approximately 20 μm . in calibre, most of them running straight for a distance of 40 to 60 μm . LVA were most frequently found on the anterior aspects of ventricles. Lymphovenous anastomoses appeared in the heart specimens seven to 14 days after ligation of lymphatic trunks, in one case they persisted up to 28 days. In cases, lasting more than one month, lymphovenous anastomoses were no longer found; the number of anastomoses was limited in each specimen (see discussion). At the same time, in three out of the five specimens referred to above, lympho-lymphatic anastomoses were found on the seventh, 14th and 28th day after ligation of lymphatic trunks. Appraisal of all chronic experiments revealed that lympho-lymphatic anastomoses had not developed but in two heart specimens (7th and 12th day) and were only found in cases in which lymphovenous anastomoses had developed.

Discussion

As has been shown by the papers of *Johnson et Blake* (68) and *Vajda et al* (72), LVA are found in the normal heart of hog. The opinions of these authors differ in the question as to whether or not LVA exist in man, the former denied their existence, while *Vajda et al.* described them as frequent structures, 100-500 and even 700 μm . thick. When comparing the findings in the two papers with those of the present investigation in acutely stenosed lymphatic vessels of the canine heart, it may be said that in the normal heart of dog there are no LVA. *Zerbino et Gavriš* (70) reported that they always found lymphovenous anastomoses in the canine heart after ligation of lymphatic vessels. Evidence of this is also furnished by the retrograde permeation of the injected substance from the veins into the lymphatic bed. Data referring to the duration of development and persistence of LVA have not been reported on, nor has there been made any mention in the paper of the development of lympho-lymphatic anastomoses. It emerges from the experiments of the present investigation that LVA were found in five out of 23 dogs (21,7%) in chronic occlusion of lymph routes. They were found from the seventh day after ligation together with developing lympho lymphatic anastomoses. No LVA were found by retrograde injection of the lymphatic network from the venous bed. Because of the calibres of LVA it must be assumed that the technical conditions did not permit to determine their exact number. In clarified specimens, approximately six anastomoses were found in the subepicardial network of the ventricles. The authors do not agree with the opinions of *Zerbino et Gavriš* who described LVA in the canine heart as multiple and common structures. Both *Zerbino et Gavriš* and *Vajda et al.* never reported on the number of anastomoses. When observing the injected specimens, the error arising from the close neighbourhood of lymphatic vessels and veins, crossing each other frequently, should be avoided, and only by meticulous appraisal after dissection from all sides can it be ascertained whether or not these are LVA.

In agreement with other authors (*Patek*, 1939; *Bradham*, 1970 and *Suschko*, 1950) the authors of this communication do not consider evidence of LVA furnished by injection into the interstice as convincing, because puncture and pressure during injection lead to damage to the walls of blood vessels and permit the substance to escape into the veins.

It should be assumed that development of LVA is indirectly dependent on the development of lympho-lymphatic anastomoses. If lympho-lymphatic anastomoses have developed by the seventh day, a substituting drainage of lymph and the interstitial fluid via the LVA is not required and LVA do not develop. If, however, the drainage of lymph via the lympho-lymphatic anastomoses is insufficient, both forms of lymph drainage may exist simultaneously. This is borne out by the cases of the three out of five heart specimens with LVA referred to above. *Rusznjak et al.* (1957) produced the clinical picture of myocardial infarction in dog by ligation of the cardiac

lymphatic trunks; within five days the pathological signs receded in the ECG. This recession is, according to these authors, due to the development of lympho-lymphatic anastomoses. *Vajda* et al., on the other hand, explained the normalization of the ECG by the presence of permanent LVA. According to the opinion of the authors of this communication, the picture of myocardial infarction should never develop in the presence of permanent and thick LVA (as described by *Vajda* et al.) after occlusion of the lymphatic trunks. It may be assumed that development of lympho-lymphatic anastomoses only takes place under possible simultaneous development of lymphovenous anastomoses during the week in which the ECG changes recede.

The authors thank Mrs. A. Holubona and Mrs. B. Jirova for the technical assistance.

References

- 1 *Bock H.*: Die Lymphgefäße des Herzens. *Anat. Anz.* 27 (1905) 33-41
- 2 *Bradham E.R., E.F. Parker, B.A. Barrington, Ch. M. Webb, J.M. Stallworth*: The cardiac lymphatics. *Annals of Surgery*, 171 (1970) 899-902
- 3 *Bradham R.R., E.F. Parker, W.B. Greene*: Lymphatics of the atrioventricular valves. *Arch. Surg.* 106 (1973) 210-213
- 4 *Ditkovsky A.P.*: Lymphatic vessels in ischaemic foci in the myocardium. (Russ) Thesis, 1968, Kiev, 1-21
- 5 *Dobrovolskaya-Zaytseva J.*: Morphology of the lymphatic vessels and capillaries in the human heart under normal and pathologic conditions. *Folia morphol. (Warszawa)*, 29 (1970) 25-32
- 6 *Drinker C.K., J.M. Yoffey*: Lymphatics, lymph, and lymphoid tissue. Cambridge, Mass. Harvard univ. Press, 1941
- 7 *Eberth C.J., A. Belajeff*: Über die Lymphgefäße des Herzens. *Virchows Arch. Path. Anat. Physiol. (u klin. Med.)* 37 (1896) 124-130
- 8 *Elišková M., O. Eliška*: Lymphatic vessels of the dogs heart. *Cor-Vasa*, 16 (1974) 301-310
- 9 *Fedyai V.V.*: The structure and histotopography of lymphatic vessels in the wall of human heart. Thesis, IX. international congress of anatomists, Leningrad, 1970
- 10 *Johnson R.A., T.M. Blake*: Lymphatics of the heart. *Circulation* 33 (1966) 137-142
- 11 *Johnson R.A., T.M. Blake*: Vasa vasorum of the heart. *Amer. Heart J.* 76 (1968) 79-89
- 12 *Jossifow G.M.*: Das Lymphgefäßsystem des Menschen. Jena, G. Fischer, 1930
- 13 *Miller A.J., R. Pick, L.N. Katz*: Ventricular endomyocardial changes after impairment of cardiac lymph flow in dogs. *Brit. Heart J.* 25 (1963) 182-190
- 14 *Miller A.J.*: The lymphatics of the heart. *Arch. of Inter Med.* 112 (1963) 501-511
- 15 *Nagy Z., H. Jellinek, B. Veress, A. Kocze, A. Bálint, F. Solti*: Effect of experimental lymph congestion on coronary artery permeability in the dog. *Acta Morph. Acad. Sci. Hung.* 17 (1969) 167-170
- 16 *Nyström G.*: Über die Lymphbahnen des Herzens. *Arch. Anat. Entwicklg.* (1897) 361-378
- 17 *Patek P.R.*: The morphology of the lymphatics of the mammalian heart. *Amer. J. Anat.* 64 (1939) 203-250
- 18 *Rényi-Vamos F.*: Das Lymphgefäßsystem der Organe. *Akademiai Kiado, Budapest*, 1960
- 19 *Rusznák I., M. Földi, G. Szabó*: Physiologie und Pathologie des Lymphkreislaufes. *Akademiai Kiado, Budapest*, 1957
- 20 *Servelle M., J. Andrieux, C. Cornu, A. Deloche, O. Nussame*: Les Lymphatiques du coeur (injections peroperatoires). *Arch. des Maladies du Coeur*, 1 (1967) 89-106
- 21 *Solti F., M. Iskm, J. Nagy, A. Hartai, B. Veress, I. Hüttner, T. Kerényi*: The effect of mechanical lymph flow insufficiency on cardiac muscle necrosis as a result of coronary ligation. *Cor. et Vasa* 10 (1968) 68-72
- 22 *Suschko A.A.*: 1950, Cit. after *Rusznák I., M. Földi, G. Szabó*: Physiologie und Pathologie des Lymphkreislaufes. *Akademiai Kiado, Budapest*, 1957
- 23 *Symbas P.N., T. Cooper, G.E. Gantner Jr., V.L. Willman*: Lymphatics of the heart. *Arch. Path.* 81 (1966) 573-575
- 24 *Symbas P.N., R.C. Schlant, M.B. Gravanis, R.L. Shephert*: Pathologic and functional effects on the heart following interruption of the cardiac lymph drainage. *J. Thorac. Cardiovasc. Surg.* 57 (1969) 577-584
- 25 *Vajda J., M. Tomcsik, W.J. van Doorenmaalen*: Connections between the venous system of the heart and the epicardiac lymphatic network. *Acta Anat.*, 83 (1972) 262-274
- 26 *Zerbino D.D., A.S. Gavrish*: Lympho-venous shunts in lymph outflow from obstruction the heart. (Experimental morphological research). (Russ). *Bjulleten Experimentalnoj Biologii i Med.* 8 (1970) 106-109
- 27 *Zerbino D.D.*: Carcinosis of the heart lymphatics (Russ) *Kardiologia*, 12 (1970) 113-115