

### References

- 1 *Starling, E. H.*: Physiological factors involved in the causation of dropsy. *Lancet* 1896/I, 1267-1270
- 2 *Dumont, A. E., J. H. Mulholland*: Flow rate and composition of thoracic duct lymph in patients with cirrhosis. *New Engl. J. Med.* 263 (1960), 471-474
- 3 *Witte, M. H., A. E. Dumont, W. R. Cole, C. L. Witte, K. Kintner*: Lymph circulation in hepatic cirrhosis: effect of portacaval shunt. *Ann. Int. Med.* 70 (1969), 303-310
- 4 *Witte, C. L., M. H. Witte, A. E. Dumont, W. R. Cole*: Effective plasma oncotic pressure in hepatic cirrhosis and experimental ascites. *Surg. Forum* (in press), 1969
- 5 *Witte, C. L., M. H. Witte, A. E. Dumont, J. Frist, W. R. Cole*: Lymph protein in hepatic cirrhosis and experimental hepatic and portal venous hypertension. *Ann. Surg.* 168 (1968), 567-577
- 6 *Witte, M. H., A. E. Dumont, W. R. Cole, N. Levine, U. Aker, R. H. Clauss, G. Kaley*: The lymphatic circulation in disorders of salt and water balance resulting from hepatic venous block. *Proceedings of the Second International Congress on Lymphology, 1968.* Thieme, Stuttgart, publ., M. Viamonte, ed. in press)
- 7 *Witte, C. L., M. H. Witte, W. R. Cole, Y. C. Chung, V. R. Bleisch, A. E. Dumont*: Dual origin of ascites in hepatic cirrhosis. *Surg. Gyn. & Obst.* (in press)
- 8 *Witte, M. H., W. R. Cole*: Failure of lymph flow in man and experimental animals: reversal by surgically constructed lymphatic-venous shunts. *Progress in Lymphology.* Thieme, Stuttgart, publ., A. Ruttimann, ed., (1967), 376-379

*Dr. M. H. Witte, Tuscon Veterans Administration Hospital, South 6th Avenue, Tuscon, Arizona 85713, USA*

## X-Ray Opacification of Hepatic Lymph Nodes Following Intravenous Injection of Tantalum Dust\*

**A. E. Dumont, A. Martelli**

Department of Surgery New York University School of Medicine, New York

Available methods for x-ray opacification of lymph nodes rely upon either an intraperitoneal or an intralymphatic injection of contrast material. Intraperitoneal injection leads to opacification of intrathoracic, internal mammary nodes while injection into a peripheral lymphatic results in opacification of regional nodes. A successful attempt to obtain x-ray visualization of hepatic lymph nodes following intravenous administration of contrast material forms the basis for this preliminary report. The method depends upon the uptake of radiopaque powdered tantalum by the liver and subsequent transport of tantalum in hepatic lymph.

### Method

Fresh suspensions of tantalum powder\* (particle size averaging 2.5 microns) were prepared as follows: 200cc of 10% sorbitol were added to 50 grams of tantalum powder, stirred for 1 hour in a Vertis homogenizer and immediately injected intravenously in

\* This investigation was supported in part by the James Picker Foundation on recommendation of the Committee on Radiology, National Academy of Sciences-National Research Council and by the Hartford Foundation.

\* The tantalum used in this study was obtained from the Fansteel 1 Tantalum Place, Chicago, Illinois.

experimental animals. In experiments in 70 rats and 20 dogs amounts ranging from 0.5 to 1 gram/kilo were injected in most instances but at times half of these amounts were utilized with delayed visualization.

Anteroposterior and lateral x-rays were taken at intervals which ranged from 3 hours to 6 months after injection. In some experiments animals were sacrificed at various

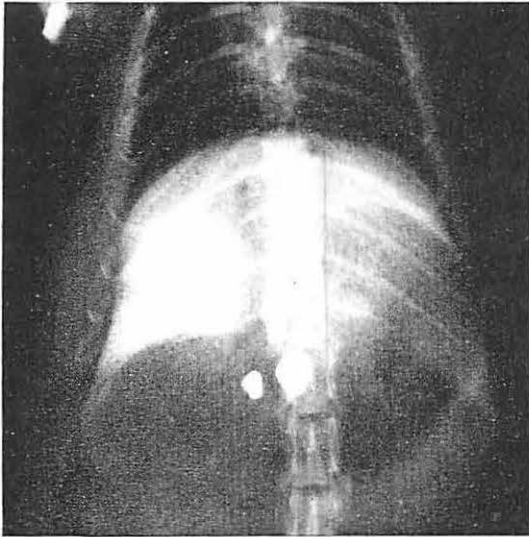
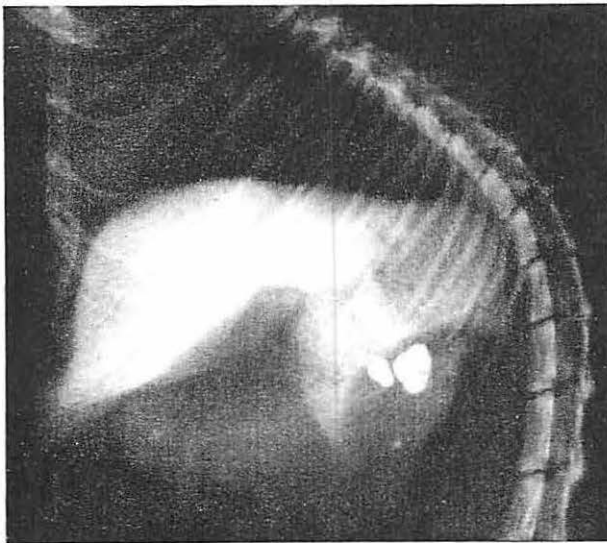


Fig. 1 Anteroposterior (A) and lateral



(B) views of hepatic hilar nodes in a rat 2 weeks after intravenous injection of tantalum dust.

intervals and sections of hepatic hilar lymph nodes, liver, spleen, lung, heart and kidney were taken for histologic studies. Chemical tests of liver function (bilirubin, total, protein, bromsulfalein retention, SGOT and SGPT) were performed in several dogs at 1 and 4 weeks after injection of tantalum. In other animals complete blood counts and hematocrits were determined 1 week and 2, 4 and 5 months after injection of tantalum.

### Results

Within 5-14 days after intravenous administration of powdered tantalum, lymph nodes at the hilus of the liver became radiopaque in every animal. Three distinct nodes at the hilus of the liver were regularly visualized in the rat and 3 or more in the dog (Fig. 1 and 2). These nodes remained radiopaque for 2 to 3 months or longer, then gradually became less opaque. Three to 4 days prior to x-ray visualization of these lymph nodes a high degree of radiopacity developed in the liver and spleen which persisted for 4 to 6 weeks (Fig. 3).

When examined at laparotomy or at autopsy the hepatic nodes were distinctly gray-black in color and clearly identifiable. They appeared normal in size and distribution and there was no inflammatory reaction in or around them. Microscopic sections disclosed deposits of tantalum throughout the node but predominantly in the cortical region. No evidence of necrosis, inflammation or any other pathological alterations was noted (Fig. 4).

Except when administered in amounts far in excess of those required for opacification pulmonary embolism did not occur. No signs of acute toxicity, hematological or pathological alterations have been observed for up to 10 months the longest period of obser-

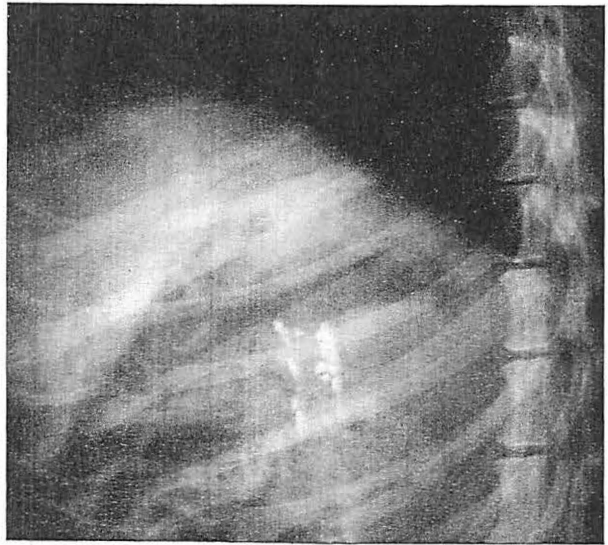


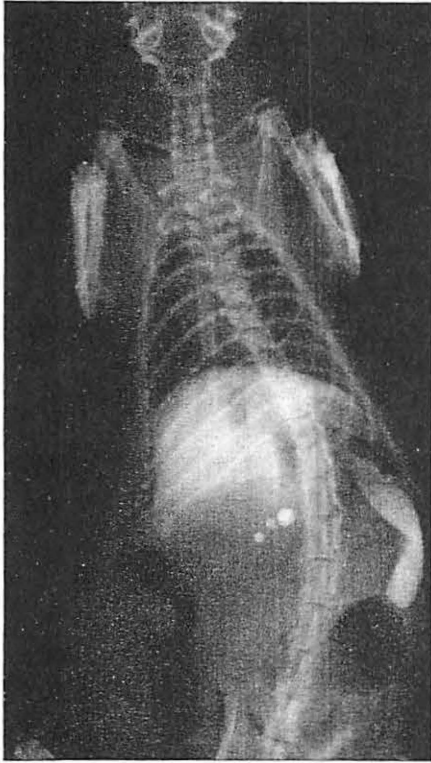
Fig. 2 Lateral view of hepatic hilar lymphatics in a dog 5 months after intravenous injection of tantalum dust.

vation to date. Although splenectomy carried out in 6 rats and 4 dogs prior to injection of tantalum did not alter the deposition of the metal in hepatic lymph nodes, it usually resulted in deposition of tantalum in the lung. A detailed account of the deposition of tantalum in the liver and spleen and the effect of various surgical maneuvers on its distribution will be reported separately.

### Discussion

Use of intravenous tantalum dust for x-ray opacification of hepatic lymph nodes depends primarily upon uptake of small particles by hepatic reticuloendothelial or Kupffer cells. Subsequently, a portion of the injected dose is apparently transported in hepatic capillary filtrate from the perisinusoidal spaces of Disse to lymphatics and nodes at the hilus of the liver.

Selective deposition of particulate matter in hepatic nodes following hepatic uptake from blood was observed by *Huggins* and *Froehlich* (3). In a report published recently they described the distribution of 0.2–0.4 micron particles of non-radiopaque titanium



dioxide in the liver and spleen and then in hepatic hilar nodes, designated by them as "celiac nodes".

Tantalum is classified as a transitional metal with an atomic weight of 73 and 180.88. It is inert physiologically as well as chemically (1). A long history of successful permanent surgical implantation as a sheet, mesh or plate in man is based on these chemical and physiological properties (2, 4). Although the tantalum used in this study is in the form of a powder, and was injected intravenously, it is likely that similar considerations apply.

Although an interval of several days to a week is required for the hepatic nodes to become radiopaque, histological studies show that the material begins to accumulate in these nodes within 24 hours of injection. Retention of tantalum for many months has

Fig. 3 Appearance of the liver, spleen and hepatic lymph nodes in a rat 6 days after a single intravenous injection of tantalum dust.

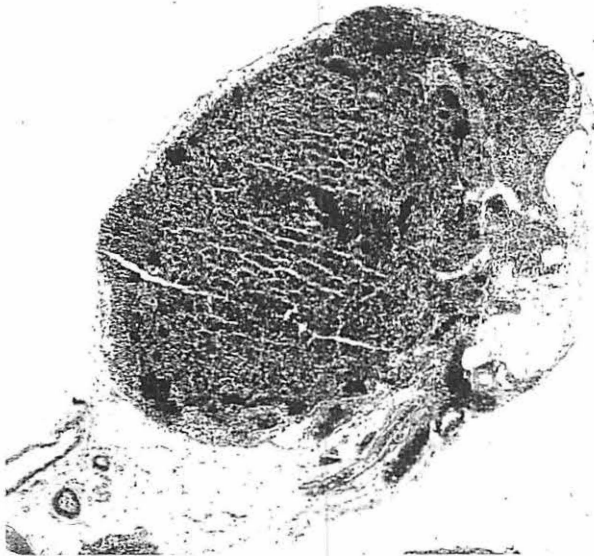

Fig 4 Microphotography of a radiopaque hepatic hilar node in a rat 2 months after intravenous injection of tantalum dust. Apart from heavy deposit of tantalum, no pathological alterations are evident. 100x.

not resulted in any microscopic pathological alteration. These characteristics combined with the ease of preparation and administration suggest that the technique may be useful for acute as well as long term studies in experimental animals and possibly in man.

### Summary

This report describes a method for obtaining x-ray visualization of hepatic lymph nodes following intravenous injection of contrast material. The method depends upon the uptake of particles of tantalum by the liver and subsequent transport of tantalum in hepatic lymph. Three to four days prior to x-ray visualization of these nodes, the liver and spleen developed a high degree of radiopacity. Because tantalum is chemically and physiologically inert, the technic may be useful in experiments in animals and possibly in man.

### References

- 1 Cochran, K. W., S. B. Doull, M. Mazur, K. P. DuBois: Acute Toxicity of Zirconium, Columbium, Strontium, Lanthanum, Cesium, Tantalum and Yttrium. *Arch. industr. Hyg.* 1 (1950), 637-650
- 2 Echols, D. A., J. A. Colclough: Cranioplasty with Tantalum Plate. *Surgery* 1 (1945), 304-314
- 3 Huggins, C. B., J. Froelich: High Concentration of Injected Titanium Dioxide in Abdominal Lymph Nodes. *J. exp. Med.* 124 (1966), 1099-1106
- 4 Vieth, Roger, G., G. T. Tindate, G. L. Odom: The Use of Tantalum Dust as an Adjunct in the Post-operative Management of Subdural Hematomas. *J. Neurosurg.* 24 (1966), 514-519

*Prof. E. Dumont, Department of Surgery, New York University School of Medicine,  
550 First Ave., New York, N.Y. 10016 USA*

## The Lymphatic System of the Heart\*

R. A. Johnson

Department of Medicine, Veterans Administration Hospital and University Medical Center, Jackson, Mississippi

In recent years lymphatics of the heart have been studied with renewed interest. There have been investigations of the drainage and composition of cardiac lymph (1, 2, 3, 4, 5) as well as studies on the effects of impeding the flow of lymph from the heart through major drainage channels (6, 7). However, many facets of the anatomical details of the intrinsic lymphatic vasculature of the heart itself are still lacking. The more recent anatomical studies (8, 9, 10, 11) have been with injection techniques to acquire information concerning lymphatics in the mammalian heart. In addition, investigations have added further to the knowledge of the relationship of lymphatics to the valves of the heart (9, 12) and have implied also a pathogenic relationship of impaired myocardial lymph drainage to endocardial fibroelastosis (13). We have observed in our laboratory that masses injected into either the coronary artery or vein in pig and dog

\* Supported in part by the Mississippi Heart Association, and Grants HE-07159 and 2-F2-HE-19, 626-02 from the National Heart Institute, U. S. Public Health Service.