

Dysplasia of the Lymphatics with Lymphoedema, Generalized Lymphangiectasis, Chylothorax and "Pseudo-Storage-Disease"

H. Heimpel*, J.R. Bierich**, J.M. Herrmann*, H. Meister** and J. Vollmar****

*Abteilung für Innere Medizin und Hämatologie, Zentrum für Innere Medizin, Kinderheilkunde und Dermatologie der Universität Ulm

**Universitätskinderklinik, Tübingen

***Abteilung für Pathologie der Universität Ulm

****Abteilung für Gefäß- und Thoraxchirurgie, Zentrum f. operative Medizin, Universität Ulm

Summary

A patient showing an unusual association of various abnormalities of the lymphatic vascular system is reported. These abnormalities became first evident in early childhood and consisted of lymphoedema of the left leg, lymphangiectasis in various organs and occlusion of the thoracic duct at its entrance into the venous angle. Chylous effusions and subcutaneous chyloedema appeared in adolescence. Diagnostic biopsies of spleen, liver and bone-marrow revealed the presence of multiple foamcells, suggesting the diagnoses of lipid storage disease. The patient died from severe honey-comb-lungs at the age of 20. This case cannot be attributed to one of the wellknown disease entities of the lymphatic system. The "pseudo"-storage disease is regarded as secondary to the backflow of chylus into the tissues.

Dysplasias of the lymphatic system may result in various clinical syndromes, depending on the nature, site and extension of the primary lesions. Out of these, rather well defined groups are a) local or generalized lymphangiomas, b) lymphangio-myomatosis occurring only in females, c) congenital pulmonary lymphangiectasis and d) congenital lymphoedemas of the lower limbs. In many of these patients, the disease becomes manifest during childhood or adolescence. In addition, cases of lymphatic dysplasia are observed with nontraumatic chylothorax as the main clinical feature, which cannot be definitely attributed to any of the disorders already mentioned (2, 5, 10).

This report describes a patient with occlusion of large lymphatic vessels at two different sites, generalised lymphangiectasis, chylous effusions, severe fibrotic lung disease and the presence of many lipid storage cells in different organs of the body including the bone marrow. The latter changes are regarded as secondary to the malformation of the lymphatic vascular system.

Case report

The patient C.L. is the first son of healthy, unrelated parents. No hereditary disorders or malformations are known in the family, one younger sister is absolutely normal. He was born by normal vaginal delivery.

The physical development was normal up to the age of 2 1/2 years, when oedematous swelling of the penis and scrotum and enlargement of the liver were noticed. At the age of 4, during a severe febrile episode, the spleen was also found to be enlarged. On the basis of these findings and that of "atypical lymphoid cells" in the bone marrow aspirate, the diagnosis of acute leukemia was made. The child was treated with small doses of 6-Mercaptopurine and Prednisone for 2 years.

At the age of 6 years, the left leg became progressively oedematous. Oozing of opaque, yellowish secretion was observed from the oedematous regions, especially from between the first and second left toe and the scrotum. Surgical disocclusion of the left iliac vein did not improve the oedema. Physical development and weight gain were retarded. At the age of 10 years, there was roentgenological evidence of interstitial fibrosis of the lungs, predominantly in the lower and middle lobes; similar changes could be detected retrospectively on the chest X-rays taken at the age of 3 years. The diagnosis of acute leukemia was discarded at this stage; moderate pancytopenia was regarded as a consequence of hypersplenism. The liver and spleen were still palpable 8 cm and 5 cm below the costal margin respectively. Liver biopsy showed moderate lipomatosis of the hepatocytes and distinct "histiocytic" infiltration with the presence of foam cells.

An abdominal lymph node specimen, though not well preserved, showed also some histiocytosis. Differential diagnosis included reticulosis, histiocytosis-X, lipid-storage disease, Banti-syndrome, Budd-Chiari-syndrome or thrombosis of the portal vein. However, none of these diagnoses could be established, even though the patient was repeatedly examined by different specialists in many clinical institutions. Bone marrow aspiration one year later showed an increase of the "lymphoid histiocytic" cells and foam cells, supporting the diagnosis of lipid storage disease. However, another lymph node biopsy from the right groin revealed only nonspecific inflammatory changes.

During adolescence, physical development was retarded, but mental and intellectual development were completely normal. No neurological abnormalities were present. The boy went to high school with the permanent disabilities of low body weight, decreased muscular strength, recurrent infections, increasing swelling of the leg and persistent secretion from the lower limb and scrotum. At the age of 16 years, he was examined for the first time in the Department of Pediatrics, University of Tübingen. The main clinical features at this time were retardation of growth and sexual development; anomalies of pigmentation consisting of irregular brownish and white, vitiligo-like areas; massive lymphoedema of penis, scrotum and left leg with lymphatic secretions and papillomatous changes between the left first and second toe and the scrotum; and hepatosplenomegaly. Laboratory parameters were normal except for moderate pancytopenia. Chest X-rays showed once again prominent interstitial fibrosis. Bone marrow biopsies from the anterior superior iliac crest* showed severe hyperplasia of large foam cells; containing birefringent needles (Fig. 8). Radioactive colloidal gold, injected subcutaneously at the insteps, was not transported through the lymphatics to the groins. Lymphangiography of the left leg using aqueous contrast dye showed dilatation and varicosity of the lymphatic vessels and retrograde filling of the smaller lymphatic vessels (Fig. 1). No filling could be achieved above the knee.

In the following years, the patient noticed recurrent subcutaneous swellings mainly confined to the trunk, which were slightly reddish, warm and painful, sometimes up to 10 cm in diameter, and which disappeared after a few days. Transient enlargement of axillary lymph nodes was also observed. These subcutaneous and lymph node swellings were accompanied by temperatures up to 40 °C. At the age of 19 years, for the first time a left sided chylothorax developed, which required repeated pleural drainages. A special diet rich in proteins and medium chain triglycerides did not prevent recurrence of the chylothorax.

At the age of 20 years, the patient was first seen at the Department of Surgery and Medicine, University of Ulm for surgical repair of the assumed lesion of the thoracic duct. The provisional diagnosis was: "Lymphatic vascular malformation along with a storage disease of indefinite classification. Clinical and laboratory findings (Tab. 1) were essentially unaltered, except for fibrotic changes of the left pleural cavity and a severe restrictive pattern of pulmonary function defect. Laparotomy with splenectomy and direct visualization of the thoracic duct was planned, but could not be carried out because of the severe impairment of ventilation. Instead, a decortication of the left lung was performed, which failed to result in persisting improvement of pulmonary function. One year later, chylothorax appeared also on the right side (the chylous origin of the effusion was proved by the presence of many chylomicrons and high content of triglycerides (1,7 g/100 ml in the fluid). The patient thereafter had recurrent episodes of septicemia and died from progressive pulmonary failure at the age of 22.

Autopsy

Autopsy was performed immediately after death. The left leg was heavily swollen. Ulcerations of the skin were noted on the toes of the left side. A milky fluid was seen oozing out from atrophic subcutaneous and muscular tissues, predominantly on the left side of lateral wall of the chest and abdomen. Milky chylous fluid was also obtained from pericardium (400 ml) and peritoneum (600 ml). Both pleural cavities were obliterated by fibrotic tissue with spongy

*Courtesy of Prof. Burkhardt, Institut of Haematology, München

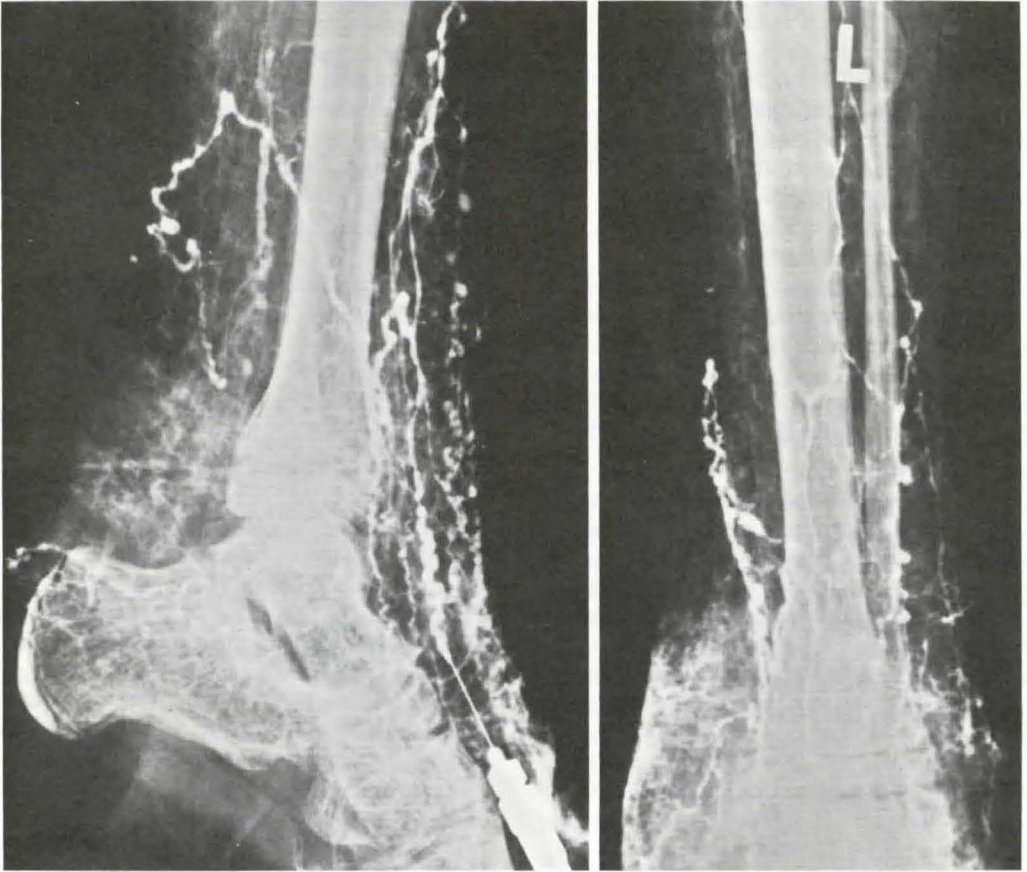


Fig. 1 Lymphangiogram of the left leg. Aqueous dye.

Table 1 Main laboratory data of patient C.L. at the age of 20. Pathological values in italics

		Patients values 1974	Range of control values
Haematokrit	%	34 - 41	42 - 52
Leukocytes	μl^{-1}	4400 - 8500	4000 - 10000
Lymphocytes	μl^{-1}	600 - 1200	500 - 1500
Monocytes	μl^{-1}	150 - 300	100 - 400
Platelets	μl^{-1}	170 000 - 230 000	150 000 - 450 000
Serumprotein	g/L	69 - 86	61 - 82
Serumalbumin	g/L	27 - 50	35 - 55
Serum γ -globulin	g/L	10 - 18	5 - 17
alkal. Phosphatase	U/L	90 - 130	60 - 200
Urin acid	$\mu\text{Mol/L}$	170 - 620	0 - 422
Kreatinin	$\mu\text{Mol/L}$	60 - 135	0 - 142
Cholesterin	MMol/L	2,4 - 4,6	0 - 6,7
Triglycerides	MMol/L	1,1 - 4,5	0 - 1,6
Chylomikrones		-	-

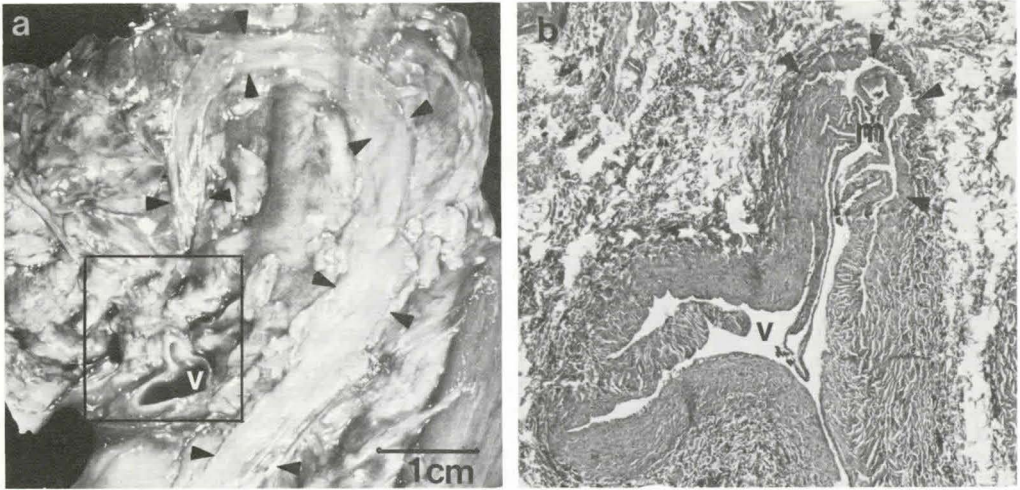


Fig. 2a Widened monotruncular thoracic duct (arrows) with thickened walls. Its upper arch-shaped portion approached the venous angle (v).

b) Photomicrograph of the demarcated area (square) showing occlusion of the entrance of the thoracic duct (arrows) to the vein (v) by a pleated membrane (m). (H.E. x 40)

areas filled with chylous fluid (approx. 300 ml). The lungs were collapsed and severely compressed by the pleural fibrosis, the left upper lobe being most severely affected. There was generalized induration of the lungs, again predominantly in the left upper lobe. Large lymphatic vessels filled with chylous fluid were prominently seen in the serosa of the small intestine and mesentery. Axillary and paraaortic, parailiac, mesenteric and bilateral inguinal lymphnodes were enlarged. Proximal lymphnodes, mainly on the left side, were spongy and filled with chylous fluid.

The liver (1780 g) and spleen (450 g) were enlarged. The thoracic duct was dilated and could be followed from the cisterna chyli up to the left jugular vein. Its entrance to the vein was completely occluded by a thin membrane (Fig. 2). No accessory inlet of the final part of the thoracic duct into the venous angle could be detected.

Most impressive microscopic changes were seen in the enlarged lymphatics of the skin of the lateral walls of chest and abdomen and scrotum, in the fibrotic areas of the pleura on both sides, in the hilus of liver and in the regions of interstitial lung fibrosis, especially in that surrounding the large blood vessels of the lung interstitium (Fig. 3).

Axillary lymphnodes exhibited similar ectasia of sinusoids, leading to their spongy consistency. In contrast, distal lymphnodes were more fibrotic, intermingled with proliferating muscle tissue in reticular or nodular arrangement, which surrounded spaces with endothelial-like covers. Occasionally, smooth muscular proliferation was restricted to vasa afferentia near their entrance into the subcapsular sinus.

Interstitial fibrosis was seen in both the lungs, most prominent in the left upper lobe. Large lymphatic spaces without muscular proliferations were present in the lung interstitium. Many macrophages were detectable in the lung, both in the alveoli and in the interstitial space, suggesting "fatty chylous" pneumonia (Fig. 5).

Of particular interest is the presence and distribution of lipid storing macrophages in the bone marrow, spleen and lymphnodes. These cells ranged from 10–100 μ m in diameter and exhibited a foamy appearance with small droplets of lipid in the cytoplasm (Figs. 6 and 7). They stained positively with Sudan-red and faintly with PAS.

Review of the bone marrow material obtained pre-mortem revealed identical cells in smears and sections (Fig. 8). The presence of storage

Table 2 Distribution of characteristic histological abnormalities in bone marrow and lymph nodes of patient C.L.

	Lymph- angie- ectasy	Myomatosis and/or fibrosis	Foam cells
Bone marrow			
Thoracic vertebra			+++
Sternum			++
Humerus right			+
Humerus left			+
Femur right			+
Femur left			+
Skull			+
Iliac crest left			+
Lymph nodes			
Beneath thoracic duct orifice	+	+++	(+)
Paraaortal left	++	++	++
Paraaortal right	+	+++	+
Mesenterium	++	+++	++
Axillary left	+++	+	+++
Axillary right	+++	+	+++
Inguinal left	+	+++	++
Inguinal right	++	+++	++
Omental	++	++	++

cells in lymphatic organs and in multiple bone marrow specimens obtained at autopsy is shown in Tab. 2. In the bone marrow, increased cellularity with prominent erythropoietic hyperplasia was seen mainly in those areas filled with storage cells. There was no evidence of neoplasia of the lympho-reticular tissue.

Discussion

The patient described in this paper showed an unusual association of pathological changes within the lymphatic vascular system, consisting of lymphoedema of the left leg, generalised lymphangiectasis, occlusion of the entrance of the thoracic duct to the internal jugular vein, and of pleural, pericardial and peritoneal chylous effusions. The disorder became evident at the age of two and progressed throughout infancy and adolescence. Death at the age of 22 resulted from progressive pulmonary insufficiency, resulting from severe pleural fibrosis and severe fibrotic changes in the parenchyma of the lungs. In addition, a great number of

lipid storing cells were present in the spleen, lymph nodes and bone marrow, suggesting the additional diagnosis of one of the lipid storage diseases.

This syndrome cannot be attributed to anyone of the well-known disorders of the lymphatic system. No similar case report could be found in the literature. The differential diagnosis included the following disorders:

1. Congenital lymphoedema of the lower extremity, as extensively studied and reviewed by *Kinmonth* (8). The findings in our case are consistent with the more frequent hypoplastic type, as in so-called *Milroys* or *Meiges'* disease. This was shown by the absence of chylous reflux into the affected limb and the results of a lymphangiography. The disorder may affect more than one limb, but is not connected with abnormalities of the central lymphatic vessels and chylous effusions.
2. Generalised or pulmonary lymphangiomyomatosis is a well defined disorder affecting mainly the lungs and the lymph nodes, in which chylous effusions, particularly chylothorax often occur. The microscopic picture, especially of the lymph nodes, is similar to the changes observed in some lymph node groups in the present case. However, all 75 patients reviewed by *Corrin* et al. (3) were females, and lymphoedema of the limbs has never been observed in this condition.
3. Generalised lymphangiomas with chylothorax is a rare, usually lethal form of congenital malformation of the lymphatic system (1). The characteristic lymphangiomas in the bone, appearing as multiple osteolytic lesions in X-rays, often lead to pathological fractures. No such lesions were present in our case. Lymphoedema of the limbs is not observed in skeletal lymphangiomas.
4. Secondary lymphatic occlusion resulting from hereditary lipid storage disease was thought of, even though such a complication has not been reported before. The autopsy findings did not show mechanical obstruction of lymphatic channels by enlarged lymph nodes. The possible coexistence of two independent diseases – malformation of the lymphatic system and hereditary lipid storage

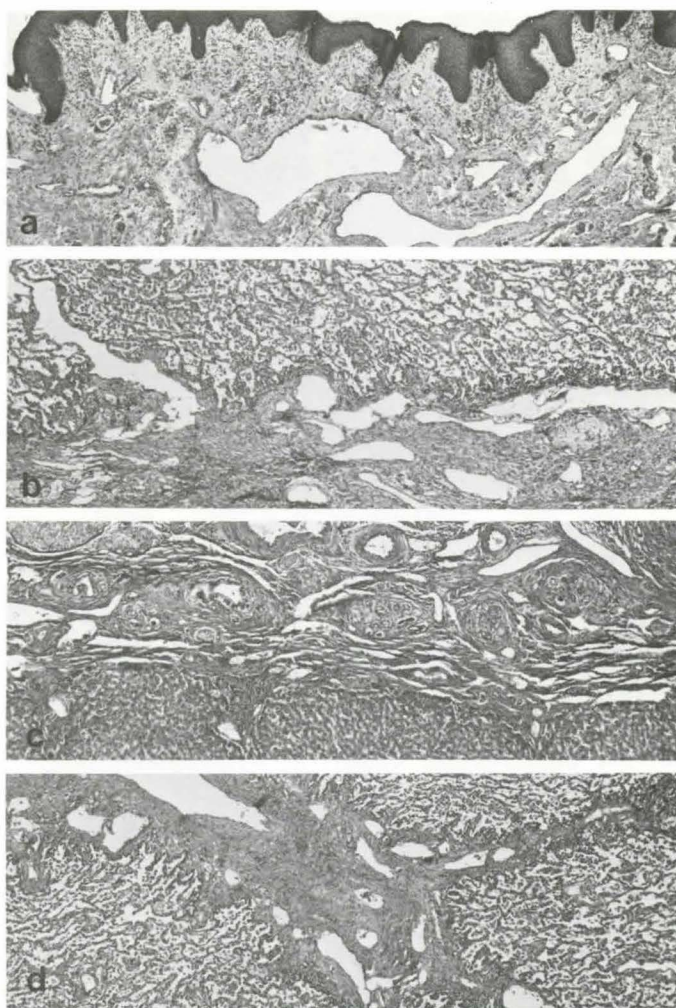


Fig. 3 Histological appearance of scrotal skin (a), pleura tissue (b), liver hilus (c) and lung interstitium (d). Many lymphatics are angioma-like arranged and some show myomatous thickened walls. Lung interstitium was fibrotic mainly in the left upper lobe, most of medium-sized interstitial blood vessels being surrounded by large dilated lymphatics. (H.E. x 40)

disease — has to be considered. However, the clinical and morphological picture — irrespective of the lymphatic changes — does not correspond to that of hereditary thesaurismoses. The gangliositoses are ruled out because of absence of neurological and mental defects. The non-neuronopathic form of *Gaucher's* disease shows morphologically as well as cytochemically characteristic foam cells and elevation of alkaline phosphatase, both features being absent in our case. Chronic non-neuronopathic (Typ B) *Niemann-Pick*-disease can-

not be completely excluded, because lipid analysis of the organs has not been performed. Lack of vacuoles in the mononuclear cells of the peripheral blood and lack of significant changes in the liver render this rare form of Sphingomyelin lipidosis unlikely (4).

5. Various syndromes of lymphatic vascular abnormalities, including lymphoedema, generalized lymphangiectasis, lymphomatosis and chylous effusions have been described mostly as single case reports, without forming any (Continued page 237)

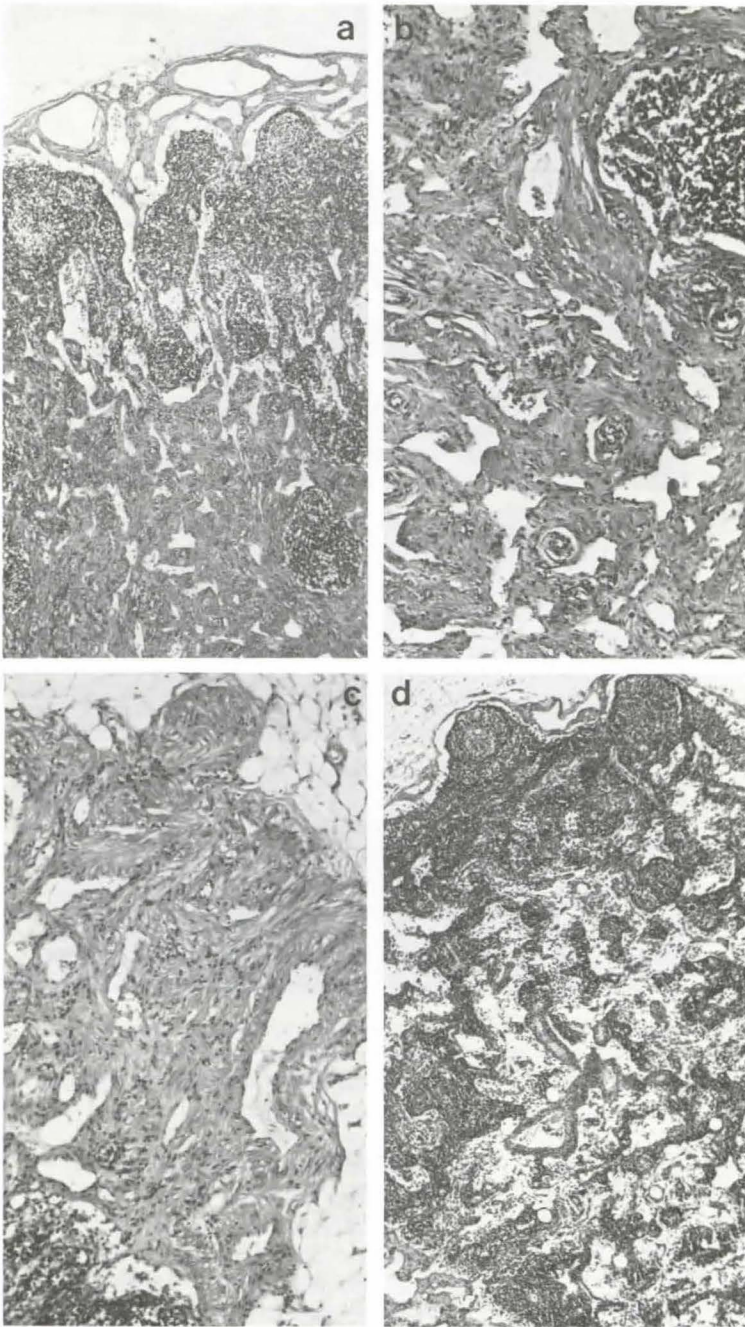


Fig. 4 Inguinal (a, b, c) and axillary (d) lymph nodes. Bundles of smooth muscles in reticular or nodular arrangement are intermingled with endothel-lined anastomosing vascular clefts (b). Similar angiomyomatous proliferations were present in the afferent lymphatics (c). In contrast, axillary lymph nodes exhibited extremely dilated sinus (d). (H.E.; a and d x 40, b and c x 90)

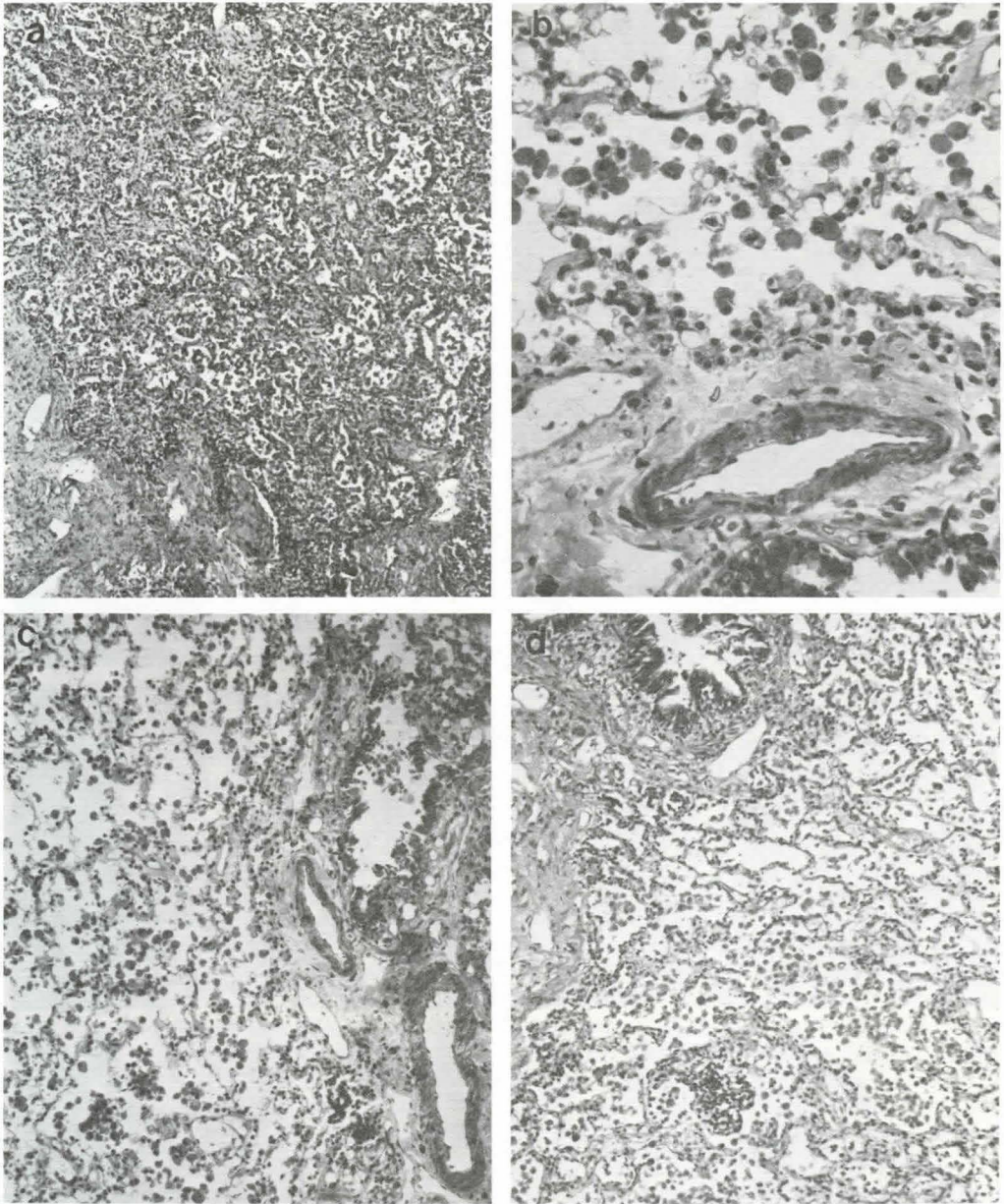


Fig. 5 Lung, left upper lobe (a), right upper and lower lobe (b, c, d). Alveolar walls and interstitial tissue mainly in the left upper lobe are broadened by fibrotic tissue. The alveoli in all lung areas are filled with numerous foamy macrophages. (H.E.; a x 40, b x 230, c and d x 90)

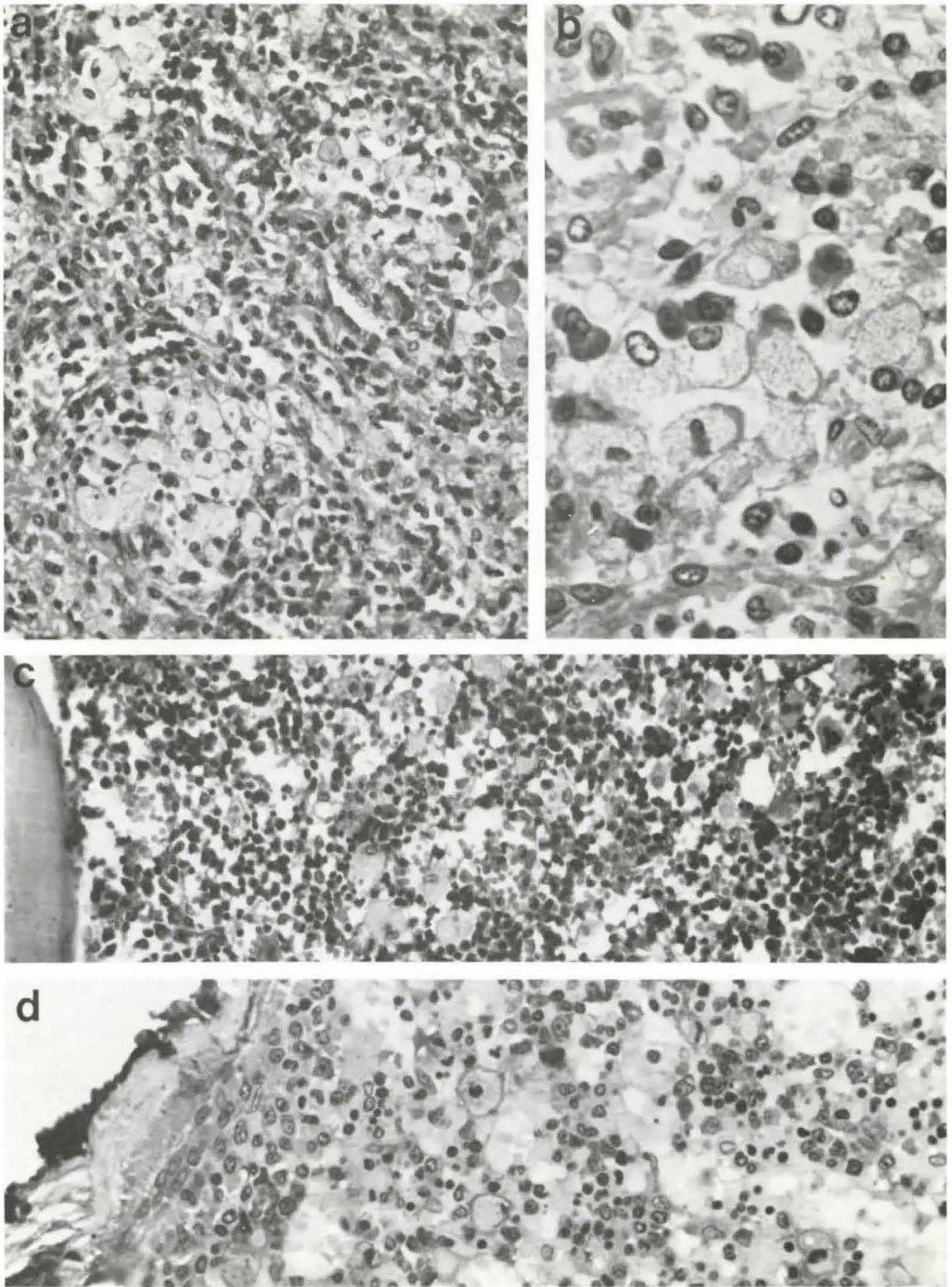


Fig. 6 Spleen (a, b), spinal (c) and sternal (d) bone marrow. Numerous foamy macrophages are present. (a, b, d Methylacrylate, Galliamin-Blue-Giemsa; c Paraffin, H.E.; a and c x 230, b x 580, d x 360).

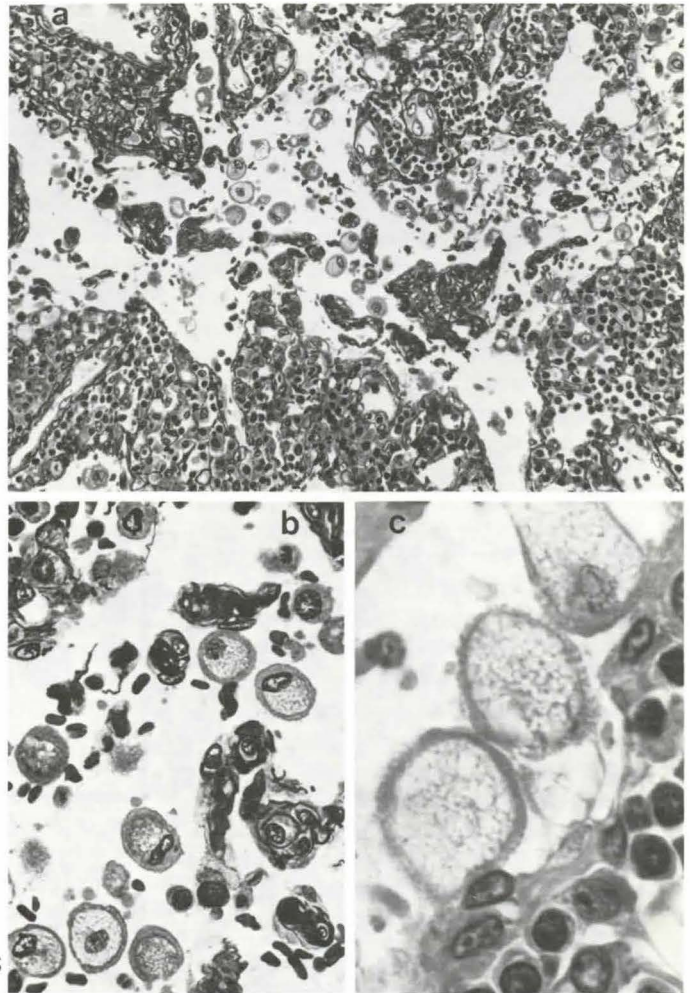


Fig. 7 Left-sided axillary lymph node. Numerous macrophages with foamy cytoplasm are present in the marginal sinus and in the network of extremely dilated medullar sinus. (Methylacrylate, Galliamin-Blue-Giemsa; a x 230, b x 580, c x 1450)

clear-cut nosological entity. Chylous ascites, chylothorax and lymphoedema were reported by *McKendry* et al. (10). In the latter case, multiple lymphangiectasis was observed at autopsy, corresponding to the findings in our patient. The same was seen in an adult female patient reported by *Freundlich* (5), who died from pulmonary insufficiency at the age of 30, and of one of the two children extensively studied by *Chang* et al. (2). In *Chang's* second case, the occlusion of the thoracic duct orifice was probably brought about by secondary thrombotic changes involving the adjacent veins. In none of these cases, the presence of lipid foam cells was reported. Such cases of generalised lymphangiectasis have

been separated from lymphangiomas by *Chang* et al. (2) and are regarded as delayed ectasia of abnormally developed lymphatic vessels.

In summary, the syndrome described cannot be attributed to any known disorder of the lymphatic system. The most probable explanation is a multiple malformation of the lymphatic system, with at least two well defined sites of abnormalities, the lymphatic channels of the left lower limb and the occlusion of the thoracic duct to its entrance into the left venous angle. The fact that non-chylous lymphatic fluid was being excreted from the skin of the lower part of the body, i.e. below the level of the cisterna chyli, and that chylous

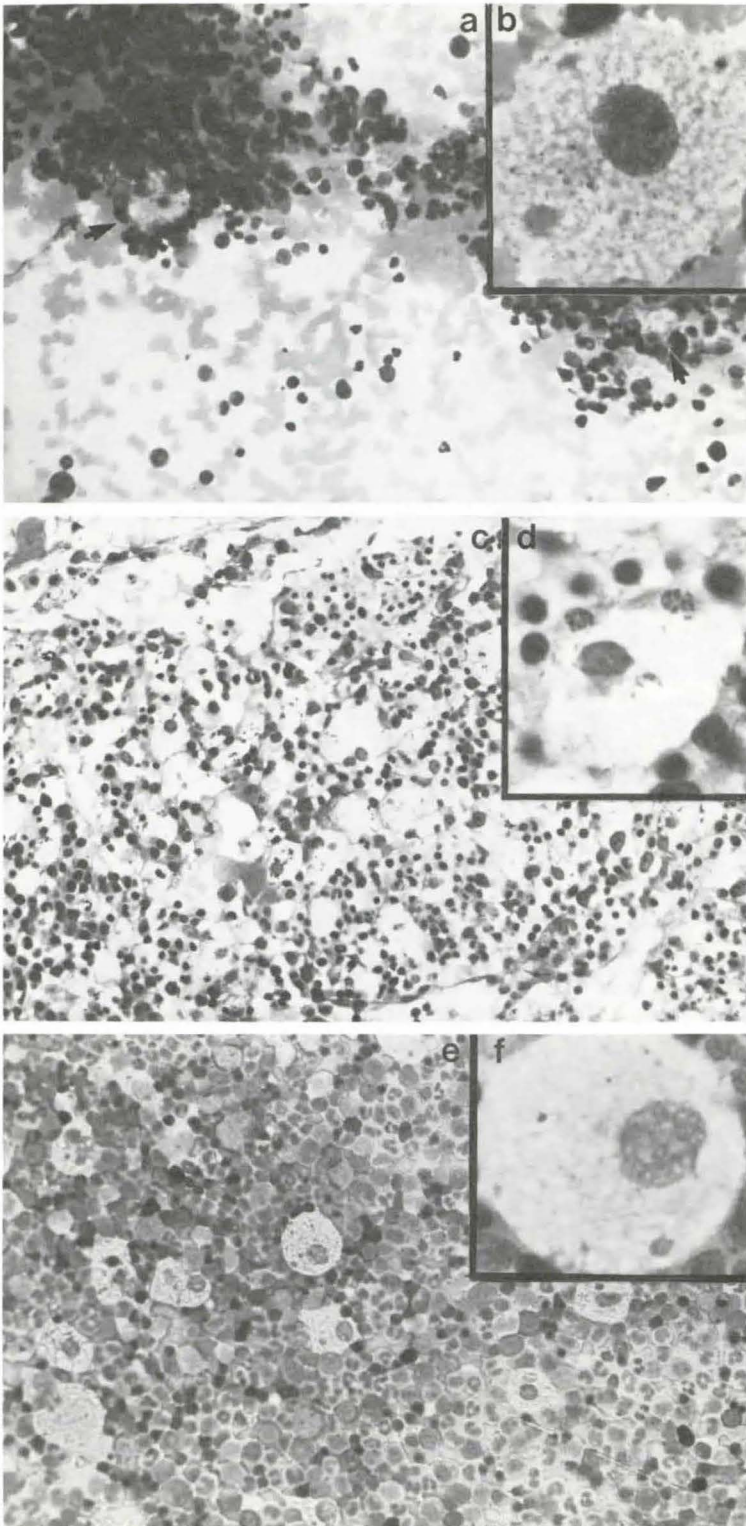


Fig. 8 Marrow specimens from the iliac crest. In aspirated material from 1960 (a) some storage cells with foamy cytoplasm (b) were seen. In the biopsy from 1971 (c) one sees similar storage cells (d). The amount of histiocytic storage cells in bone marrow increased up to 1974 (e). Phagocytes (f) were morphologically similar to those observed previously (a). (a, c, e x 580; b, d, f x 1450; a, b, e, f, Giemsa; c, d, Methylacrylate, Galliamin-Blue-Giemsa)

lymph fluid was escaping into the serous cavities and into the soft tissues of the upper part of the body, corroborates such an assumption. The recurrent, inflammatory, painful oedematous swellings of the subcutaneous tissue of the trunk can be attributed to ectatic lymphatics or lympho-venous anastomosis in the drainage area of the cisterna chyli and thoracic duct. The main evidence for such "chyloedema" was the leaking of milky fluid from the subcutaneous tissue of the chest wall at autopsy. The fibrotic changes in the lung were less prominent in the lower lobe of the left and the right lung, both areas drained by the right lymphatic trunk and not by the thoracic duct.

The question whether the occlusion of the thoracic duct at its termination is by itself responsible for the ubiquitous lymphangiectasis and the chylous reflux in the drainage area of the thoracic duct, remains open. In proximal thoracic duct occlusion occurring in children or adults secondary to trauma, mediastinitis, tumor or venous thrombosis, chylothorax but no chyloedema has been observed (7, 12, 13, 14, 16). Experimental ligation of the thoracic duct in animals does not lead to chyloedema and leads to chylothorax in only a minority of the animals (9). In patients with traumatic or neoplastic chylothorax, ligation of the thoracic duct at the diaphragmatic level is well tolerated (6). This is explained by the presence of lympho-venous anastomoses at various segments of the thoracic duct. On the other hand, multiple lymphangiectasis similar to our observation were described by *McKendry* et al. (10) and by *Chang* et al. (2) in patients with patent thoracic duct. Therefore, the combination of lymphangiectasis as primary malformation of the smaller lymphatic vessels with loss of valve function and of additional occlusion of the duct orifice with increased intraductal pressure and chylous backflow is the most likely explanation. It is possible that some patency of the thoracic duct or of one of its proximal branches — double or triple branch ducts occurring in about 30% (12, 15) — existed up to the time when the first chylothorax occurred. It is to be presumed that this opening was secondarily

occluded, leading to recurrent chylous refluxes and rapid deterioration in late adolescence.

The presence of numerous foam cells in the area drained by the thoracic duct including subcutaneous tissues, lymph nodes, spleen, pancreas and lungs, could be secondary to the backflow of chyle into these tissues. The lipids were apparently not reabsorbed into the blood stream, because plasma lipids in this case were essentially normal (lipophagocytosis resulting from hyperlipidemia occurs at excessively increased plasma triglyceride or cholesterol levels only). The access of bone marrow macrophages to chyle is difficult to explain, because lymphatics are normally not detectable within the marrow (*Calvo*, pers. comm.) and have not been seen in the bone marrow biopsies of our patient. However, this may be different in lymphatic malformations, e.g. *Morphis* et al. (11) noticed lymphatic spaces in the bone marrow of a child with generalised lymphangioma involving the bones.

Foam cells in lung tissue were reported in lymphangiomyomatosis with chylothorax by *Pamuckloglu* (13) and explained as "chylostasis". It is somewhat surprising that similar lipophagocytosis has not been reported in any of the other cases of multiple lymphatic malformations. However, in many of these no detailed description of lymph node and bone marrow biopsy is given.

In summary, we believe that the lymphatic dysplasia in the present case is not the result of noxious external factors. This is a congenital disorder which became clinically apparent in early childhood and adolescence. Delayed appearance of lymphoedema of the limbs — a disease commonly accepted as a congenital malformation — has been reported (8).

The therapeutic measures planned were frustrated by the poor and progressively deteriorating pulmonary functions. This did not permit major abdominal surgery when the patient was seen for the first time by the vascular surgeon. Decortication of the left lung failed to improve pulmonary insufficiency. With early diagnosis and surgical treatment with reopening of the thoracic duct, chylous effusions and chyloedema might have been

cured or alleviated. A therapeutic alternative could be the ligation of the duct(s) at the level of the diaphragm in an attempt to prevent recurrent chylothorax and pulmonary chylos-tasis. This naturally calls for energetic attempts to diagnose possible malformations of the central lymphatic duct by operative lymphangiography if a lymphatic vascular dysplasia is suspected.

References

- 1 Berberich, F.R., J.D. Bernstein, H.D. Ochs, R.T. Schaller: Lymphangiomatosis with chylothorax. *J. Pediatrics* 87 (1975) 941
- 2 Chang, C.K., C. Visekul, J. Opitz, J. Herrmann, J.R. Pellet, J.W. Baker, J. Gutenberg, E.F. Gilbert: Generalized lymphangiectasis associated with chylothorax: A possible dysplasia of the lymphatic system. *Z. Kinderhkl.* 118 (1974) 9
- 3 Corrin, B., A.A. Liebow, J.P. Friedman: Pulmonary lymphangiomatosis. A review. *Am. J. Pathol.* 79 (1975) 348
- 4 Fredrickson, D.S., H.R. Sloan: Sphingomyelin lipoidoses: Niemann-Pick-Disease. In: *The metabolic basis of inherited disease*, ed. by J.B. Stanbury, D. Wyngaarden, D.S. Fredrickson, McGraw Hill New York 1972, p. 783
- 5 Freundlich, J.M.: The role of lymphangiography in chylothorax. A report of six nontraumatic cases. *Am. J. Roentgenol. Radium Ther. Nucl. Med.* 125 (1975) 617
- 6 Goorwich, J.: Traumatic chylothorax: A review of the literature and report of a case treated by mediastinal ligation of the thoracic duct. *J. Thorax. Surg.* 29 (1955) 467
- 7 Henke, D., A. Hecht: Chylothorax und akuter Ascites chylosus bei neurinomatöser Harmartie im Bereich des Ductus thoracicus. *Thoraxchirurgie* 6 (1958) 564
- 8 Kinmonth, J.B.: *The Lymphatics. Diseases, Lymphography and Surgery.* Arnold, London 1972
- 9 Lee, F.C.: The establishment of collateral circulation following ligation of the thoracic duct. *John Hopkins Hops. Bull.* 33 (1922) 21
- 10 McKendry, J.B., W.K. Lindsay, M.C. Gerstein: Congenital defects of the lymphatics in infancy. *Pediatrics* 19: 21, 1957
- 11 Morphis, L.G., Arlineu, E., J.R. Krause: Generalised lymphangioma in infancy with chylothorax. *Pediatr.* 46 (1970) 566
- 12 Nusbaum, M., S. Baum, R. Hedges, W. Blake-more: Roentgenographic and direct visualisation of thoracic duct. *Arch. Surg.* 88 (1964) 105
- 13 Pamuckloglu, Th.: Lymphangiomyoma of the thoracic duct with honeycomb lungs. *Amer. Rev. Resp. Dis.* 97 (1968) 295
- 14 Randolph, J.G., R.E. Gross: Congenital chylothorax. *Arch. Surg.* 74 (1957) 405
- 15 Van Pernis, P.A.: Variations of the thoracic duct. *Surgery* 26 (1949) 806
- 16 Yater, W.J.: Non-traumatic chylothorax and chylopericardium; Review and Report of a Case due to carcinomatous thromboangiitis obliterous of the thoracic duct and upper great veins. *Ann. of intern. Med.* 9 (1935) 600

H. Heimpel, Abt. f. Innere Medizin u. Hämatologie, Kinderheilkunde und Dermatologie der Universität Ulm, 7900 Ulm