

Anatomical Study of the Pulmonary Lymphatics

Y. Okada, M.D.*, M. Ito, M.D.**, Ch. Nagaishi, M.D.***

* Professor and Chairman of the Second Department of Surgery,
Shiga University of Medical Science

** Lecturer, Department of Thoracic Surgery, Chest Disease
Research Institute, Kyoto University

*** Professor Emeritus of Kyoto University

Summary

As the result of anatomical as well as histological investigations on the lymphatics of the human lung, the authors have arrived at the following conclusions:

1. According to the distribution and the direction of lymph flow, pulmonary lymphatics are classified into two systems and four groups.
2. The lymphatics cannot be found in the interalveolar septum.
3. The extravascular fluid pathway system plays an important role for cleaning particles in the most peripheral part of the respiratory tract where no lymphatics are found.
4. Efferent lymph flow reaches the venous angles via two routes on both sides respectively.

Introduction

Since the lung is an organ which is exposed to extrinsic factors, its lymphatic system is possibly more significant than that of any other organs as a part of the defense mechanisms of the organism.

It has been known for a long time that inhaled particulate substances move in the mucous blanket of the bronchus or in pulmonary macrophages from the peripheral portion of the bronchiolus to the upper respiratory tract. That the inhaled particulate substances are subject to lymphatic clearance is also a long established fact. On the other hand, it is also a well known fact that the lymphatic system is closely involved in the development of various lung diseases, viz. pulmonary edema, infectious disease of the lung, lung cancer, metastatic lung tumors, etc. Thus the character of the lymphatic system is complicated, in that although it participates in the defense

mechanism of the lung, it also takes part in the development of diseases.

This paper reports on anatomical observations on lymphatics of the lung, particularly on the distribution of lymphatics in the lung, and the routes of efferent lymph flow from the lung. The alveolar clearance mechanisms are also discussed, with special emphasis on the pulmonary lymphatic system and "Das extravasculäre Saftbahnsystem" (the extravascular fluid pathway system).

I. Materials and Methods

Human lungs were obtained from ten fetuses of 3-8 months of fetal age, four still-born babies, one new-born baby, and the adult patients at the time of pulmonary resection. The injection of dye solutions was the most commonly method used to make observations of the lymphatics. India ink, Berlin blue and Gerota's solution were frequently used; moreover, X-ray contrast media and acrylic resin were also used for some cases.

Fig. 1 shows dye solution-injected subpleural lymphatics of a human fetus of 8 months age.

II. Results

A. Anatomy of the Pulmonary Lymphatics

The pulmonary lymphatics are roughly classified into the lymphatic capillaries, the lymphatics and the collecting lymphatics by their structural divergencies. Most of the lymphatics of the lung are capillaries according to this classification.

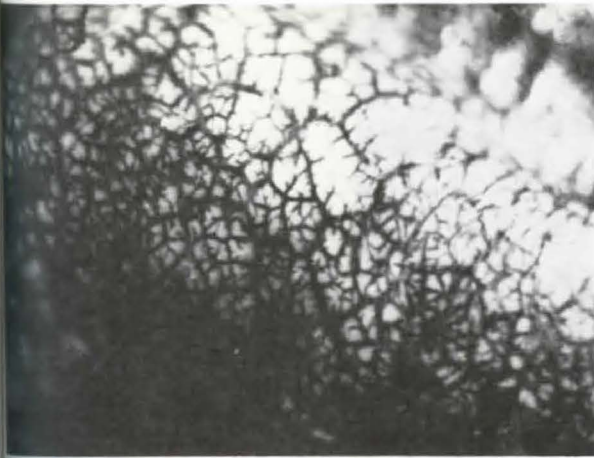


Fig. 1 Lymphatic nets of a human fetus (8th months of fetal age)

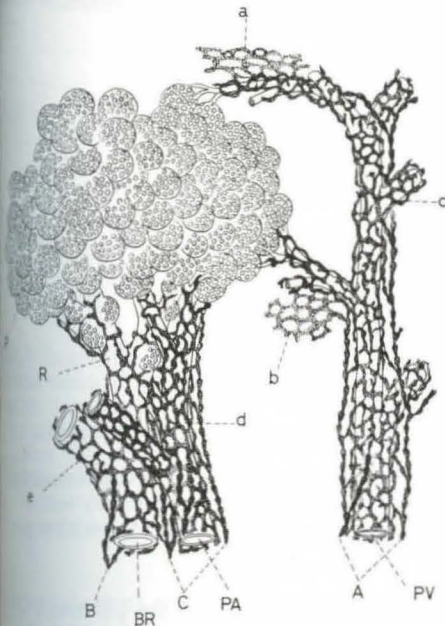


Fig. 2 Distribution of Lymphatics in the Human Lung

- A: subpleural lymphatics
- B: interlobular lymphatics
- C: lymphatics accompanying the pulmonary vein
- d: lymphatics accompanying the bronchus
- e: lymphatics accompanying the pulmonary artery
- A: collecting lymphatics accompanying the pulmonary vein (PV)
- B: collecting lymphatics accompanying the bronchus (BR)
- C: collecting lymphatics accompanying the pulmonary artery (PA)
- P: alveolar region
- R: respiratory bronchiolus

In lung tissue, lymphatics are distributed in the connective tissue of the subpleural layer, interlobular septa, intersegmental septa, perivascular space and peribronchial region as shown in Fig. 2.

The subpleural lymphatics are situated in the interstitial layer of the subpleural tissue and form a close network of lymphatics.

The subpleural lymph drain into hilar lymph nodes mainly via the subpleural-collecting lymphatics which usually run along branches of the pulmonary vein. The authors proved the following two facts with regard to the subpleural lymph drainage by injecting contrast medium for X-ray into the subpleural lymphatics of a human lung: (1) Free anastomoses are observed between the subpleural lymphatics and the interlobular lymphatics in particular areas. (2) A passage from the subpleural lymphatics to the deep lymphatics of the lung is observed even in a adult human.

A close network of lymphatics is seen in the interlobular and intersegmental connective tissue in the lung as shown in Fig. 3. Lymph in these lymphatics flows into collecting lymphatics accompanying branches of the pulmonary vein.

A close network of lymphatics is also seen around the pulmonary veins in the human lung as shown in Fig. 3. Some of the interlobular branches of the pulmonary vein are accompanied by lymphatics. The lymphatics and collecting lymphatics related to the pul-

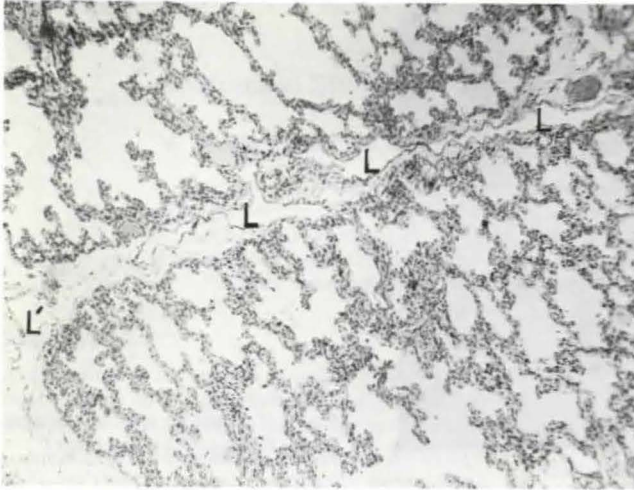


Fig. 3 Interlobular lymphatics
L: interlobular lymphatics
L': subpleural lymphatics

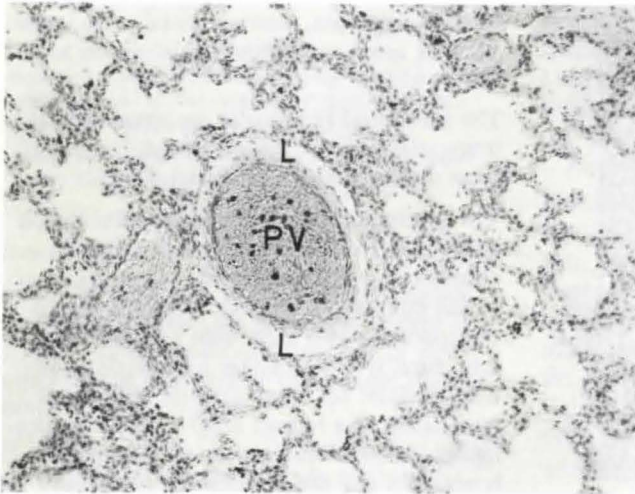


Fig. 4 Lymphatics accompanying
a branch of pulmonary vein.
L: lymphatics, PV: branch of pulmonary vein

monary vein are considered to perform the function of collecting and draining the lymph from not only the perivascular tissue but also from the subpleural and interlobular tissue.

The larger bronchi are doubly enclosed by the submucous lymphatics and the lymphatics in the adventitia as shown in Fig. 5. However, the smaller bronchi that are devoid of cartilage have only a single layer of the lymphatic network. The lymph in the peribronchial tissue is transported to the hilum by the lymphatics and the collecting lymphatics in the bronchial adventitia and by those related to branches of the pulmonary artery.

The lymphatics related to the pulmonary artery are observed to run to the outermost peripheral regions as compared with those related to the bronchi. The former are observed to extend as far as the region of the terminal bronchioli, and depending on the specimen, they sometimes extend to the respiratory bronchioli as shown in Fig. 6.

The lymphatics can not be found in the interalveolar septum in the human lung.

The connective tissues of the lung can be divided into those in the mesenchyma (i.e., subpleural, interlobular, and surrounding the

Fig. 5 Ly
the bronch
B: bronch
in the sub
phatics in

Fig. 6 L
a small b
artery.
A: a sma
artery;
B: lumen
chioli
L: lymph

pulmon
of the
and th
in the
differ
tion o
author
lung a
in sim
chym
Table
ics of
of ly

Fig. 5 Lymphatics accompanying; the bronchus.
B: bronchial lumen, L: lymphatics in the submucous layer, L': lymphatics in the adventitia

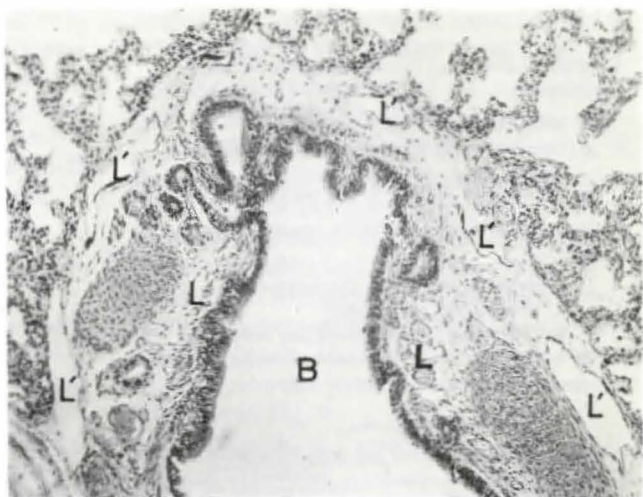
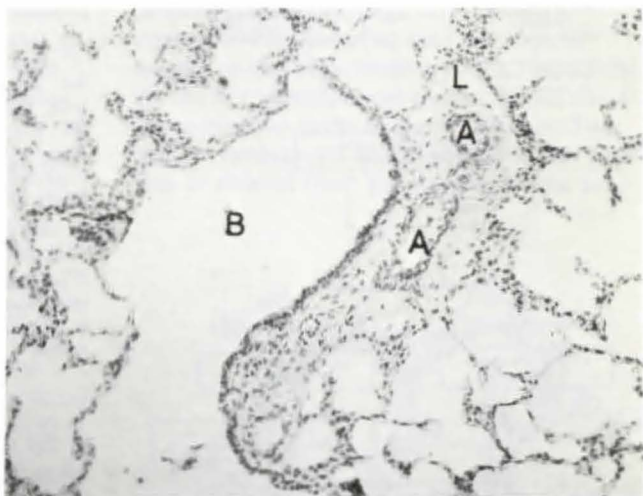


Fig. 6 Lymphatics accompanying; a small branch of the pulmonary artery.
A: a small branch of the pulmonary artery
B: lumen of the respiratory bronchiole
C: lymphatics



pulmonary vein), and those in the parenchyma of the lung (i.e., surrounding the bronchus and the pulmonary artery). The lymphatics in the lung are also considered to belong to different systems, depending upon the direction of their lymph flow. For this reason, the authors have classified the lymphatics of the lung as broncho-arterial and interstitial-venous; in simplified terms these are called "parenchymal" and "interstitial" lymphatics.

Table 1 shows a classification of the lymphatics of the lung, and Fig. 7 shows directions of lymph flows in the lung.

B. Efferent Lymph Flow of the Lung

Fig. 8 shows routes of efferent lymph flow of the lung as traced by the dye injection method in of a new-born baby.

The lymph of the right upper lobe flows into the right tracheobronchial node either directly or via the bronchopulmonary node and then runs to the right paratracheal node. The lymph of the middle lobe runs to the right paratracheal node via the bronchopulmonary node or via the right tracheobronchial or tracheal bifurcation lymph node. Much of the lymph from the right lower lobe flows into the

Tab. 1 Pulmonary Lymphatics

- A. Interstitial-venous lymphatics (interstitial lymphatics)**
1. subpleural lymphatics
 2. lymphatics in the interlobular connective tissue
 3. lymphatics related to the pulmonary vein
- B. Bronchio-arterial lymphatics (parenchymal lymphatics)**
1. lymphatics related to the bronchus
 - a. submucous lymphatics
 - b. lymphatics in the bronchial adventitia
 2. lymphatics related to the pulmonary artery

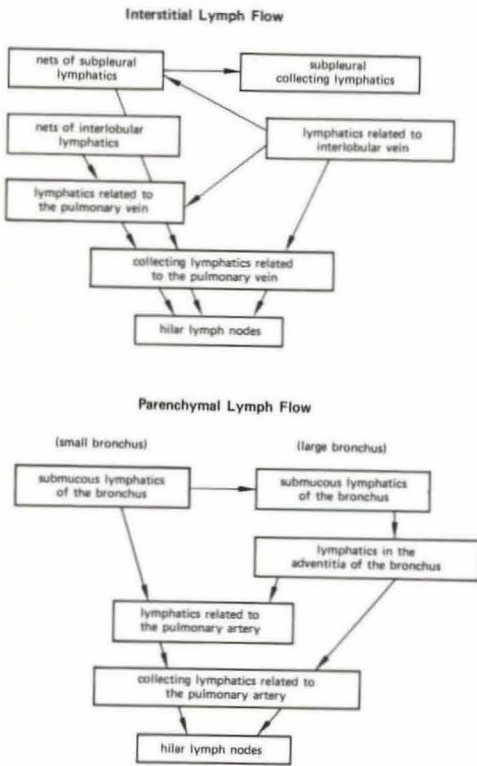


Fig. 7 Lymph Flow in the Lung

tracheal bifurcation node, and some lymph from it flows into the node of the pulmonary ligament. Most of the lymph of the left upper lobe runs in the left paratracheal lymph node and the aortic arch node. Some was observed to flow to the tracheal bifurcation node. The lymph from the left lower lobe runs primarily

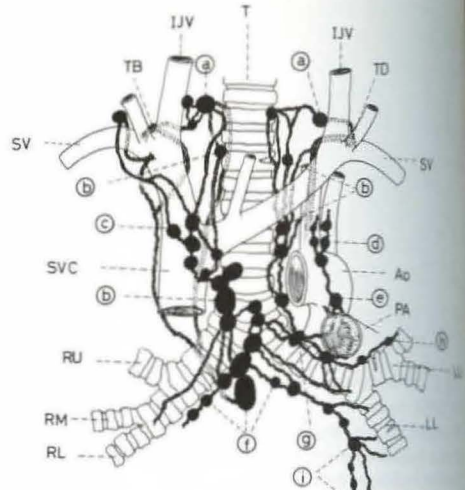


Fig. 8 Efferent Lymph Flow of the Lung

Ao: Aorta, IJV: Internal jugular vein, LL: Left lower lobe, LU: Left upper lobe, PA: Pulmonary artery, RL: Right lower lobe, RM: Right middle lobe, RU: Right upper lobe, SV: Subclavian vein, SVC: Superior vena cava, T: Trachea, TB: Broncho-mediastinal lymphatic trunk, TD: Thoracic duct

a: Cervical nodes, b: Paratracheal nodes, c: Anonymous nodes or superior mediastinal nodes, d: Aortic nodes, e: Botallo's nodes, f: Bifurcational or subcarinal nodes, g: Tracheo-bronchial nodes, h: Broncho-pulmonary nodes, i: Pulmonary ligament nodes.

to the tracheal bifurcation node. From the lower lobe, there is also a route running to the lymph node of the pulmonary ligament.

The efferent lymph flow runs via the regional broncho-pulmonary nodes of the respective pulmonary lobes to the nodes of the tracheal bifurcation, or to the right and left tracheo-bronchial lymph nodes. The route from these lymph nodes to the right and left venous angles runs in two ways. One route ascends along the trachea and via the paratracheal lymph node, running to the venous angle. The authors called it the paratracheal route.

Another route does not pass through the paratracheal lymph nodes. Slight differences are observed in the right side and the left side of this route. The right route starts from the

carcation or the right tracheobronchial lymph nodes, and, passing via the innominate vein angle nodes, reaches the venous angle. This is called the innominate vein route. The route starts from the tracheobronchial node (Botallo's node), and, passing via the aortic arch lymph nodes, reaches the left venous angle. This is called the aortic arch route.

Discussion

Wodzoff (1) (1866) reported on the lymphatics of dogs and horses; his report was one of the first to detail the anatomy of the lymphatic system of the lung. He classified the pulmonary lymphatics into two groups; superficial lymphatics and deep lymphatics.

Miller (2) divided the lymphatics of the lung into four groups according to their distribution, i.e., lymphatics of the bronchi, lymphatics of the pulmonary veins, lymphatics of the pleura and lymphatics of the interlobular septa.

The authors (*Okada* [3] and *Nagaishi*, et al. [4]) classified the pulmonary lymphatics into three groups according to their distribution, i.e., subpleural lymphatics, lymphatics in the interlobular connective tissue, lymphatics related to the pulmonary vein, lymphatics related to the bronchi and lymphatics related to the pulmonary artery. They called the former three groups the interstitial lymphatics and the latter two groups the parenchymal lymphatics as mentioned before.

Small lymphatics are often seen accompanying the intralobular branches of the pulmonary vein, and the branches of the pulmonary artery adjacent to the respiratory bronchioli. However, lymphatics have been never observed in the interalveolar septum by either electron microscopic (*Okada*, et al. [5]) or histological examinations (*Okada* [3]).

As can be seen in Figures 3–6 many lymphatics are situated between the so-called alveolar walls and the subpleural, perivascular, peribronchial or interlobular connective tissues. *Miller* (2), *von Hayek* (6), *Tobin* (7) and many other authors have recognized those lymphatics, and recently *Lauweryns*, et al. (8)

proposed to call them "juxta-alveolar lymphatics" instead of "alveolar lymphatics".

The routes of absorption by the respiratory tract were discussed in detail by *Nagaishi*, et al. (4). They differ according to the nature of the substances involved and particularly according to the size and physical property of the particles. In general, those of small molecular size are absorbed into the blood capillaries through the alveolar wall; on the other hand, those of larger particulate size are not absorbed directly into the blood vessels, but removed from the alveolar lumen by several pathways as shown in Fig. 9.

"Das extravaskuläre Saftbahnsystem" (the extravascular fluid pathway system) of *Kihara* (9) seems to play the most important role of cleaning particles through the connective tissue. Particles absorbed into the alveolar septum or the bronchiolar wall are transported via the extravascular pathway to the surrounding connective tissue of the lymphatics. They may be detoxicated and deposited in this portion or cleaned from this portion by the ad-

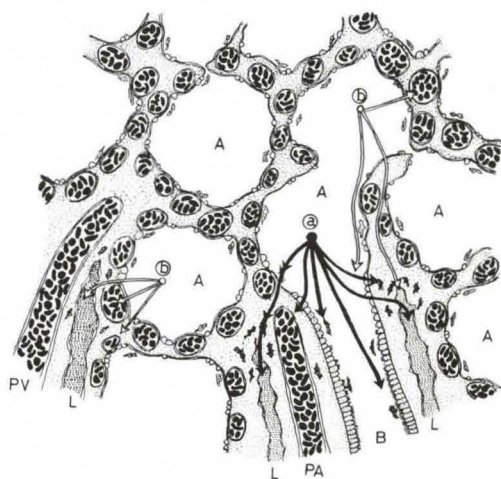


Fig. 9 Clearance of particles and fluid in the bronchiolo-alveolar area.

a : particles b : fluid

A: alveolar space, B: bronchiolar lumen
L: lymphatics, PA: branch of the pulmonary artery
PV: branch of the pulmonary vein

jacent lymphatics. Therefore, the dust accumulation in human lungs is found principally next to distal portions of peribronchiolar lymphatics and of intralobular lymphatics related to venules.

It has been pointed out by *Rouvière* (10), *Kutsuna* (11) and many other authors that most of the lymph from the right lung and the left lower lobe flows into the right bronchomediastinal lymphatic trunk. The authors revealed that the efferent lymph flow reaches the right and the left venous angles via four routes, viz., right and left paratracheal routes, aortic arch route and innominate vein route. It is worthy of attention that the bronchomediastinal lymphatic trunk is not always a single vessel.

References

- 1 *Wywodzoff, D.W.*: Die Lymphwege der Lunge. Wiener Med. Jahrbücher 11 (1866) 3
- 2 *Miller, W.S.*: The Lung. 2nd ed., C.C. Thomas Publ., Springfield, Ill., 1947

- 3 *Okada, Y.*: Studies on the structure of the pulmonary lymphatics. Recent Advances in The Res. 24 (1959) 356-386 (in Japanese, with English abstract)
- 4 *Nagaishi, C., N. Nagasawa, M. Yamashita, Y. Okada, N. Inaba*: Functional Anatomy and Histology of the Lung. University Park Press, Baltimore & London, 1972; Igaku Shoin, Ltd., Tokyo, 1972
- 5 *Okada, Y., Y. Akamine*: Ultrastructural Aspects of the Lung and Its Disorders. Igaku Shoin, Ltd., Tokyo, 1975
- 6 *von Hayek, H.*: Die menschliche Lunge. Springer Verlag, 1. Aufl., Berlin-Göttingen-Heidelberg, 1953
- 7 *Tobin, C.E.*: Human pulmonic lymphatics. An anatomic study. Anat. Rec. 127 (1957) 611
- 8 *Lauweryns, J.M., J.H. Baert*: Alveolar clearance and the role of the pulmonary lymphatics. Am. Rev. Resp. Dis. 115 (1977) 625
- 9 *Kihara, T.*: Das extravaskuläre Saftbahnsystem. Okajimas Folia Anat. Jap. 28 (1956) 601
- 10 *Rouvière, H.*: Anatomie der lymphatiques de l'homme. Masson et Cie, Paris, 1938
- 11 *Kutsuna, M.*: Anatomie des Lymphsystems der Japaner. Kanehara Shuppan, CO., Tokyo/Kyoto, 1968 (in Japanese)

Yoshio Okada, M.D., Professor and Chairman of the Second Department of Surgery, Shiga University of Medical Science, Otsu, Japan