

## Experimental Opacification of Mediastinal Lymph Nodes by Intraperitoneal Injection of an Iodinated Fatty Emulsion

M. Laval-Jeantet\*, A. M. Laval-Jeantet\*\*, O. Bacques\*\*\*

\* Professor of Radiology

\*\* Chargé de Recherche C.N.R.S.

\*\*\* Assistant in Radiology

Grant C.N.A.M.T.S. 1975-1977

### Summary

Absorption and lymphatic drainage of several lipiodol emulsions injected intraperitoneally have been studied in the rabbit and rat. Good opacification of the lymphatic channels and mediastinal lymph nodes is obtained in several hours with fine emulsions and in several days with coarse emulsions. The tolerance is related to dose, and the peritoneal reaction was moderate with the low doses, similar to that caused by the administration of physiologic saline alone. Computerized tomography in detecting low contrasts attained with small doses could render this method of indirect lymphography possible in man.

The diagnostic potential of lymphographic opacification of mediastinal lymph nodes has led to a series of experiments employing various contrast media since 1933. Although direct intranodal injection has been performed, the usual method of opacification has employed pleural or pericardial routes (1, 2) or preferentially peritoneal (3, 4) drainage because of abdomino-thoracic pathways. *Saito* (5) found that intraperitoneal injections of thorotrast opacified the mediastinal ganglions in the dog. However it rapidly became apparent that thorotrast could not be used in man. *Bennett* used angiopac (6), but severe peritoneal reactions ensued. In 1956, *Oury* (7) used lipid emulsions which were also employed later by *Koehler* (8), *Dumont* (9) and *Jonsson* (10). These emulsions remain the most interesting contrast products. Barium sulfate (11), tantalum (12), and water soluble iodine compounds (13) are too toxic or inadequate.

We have previously evaluated the use of a stable lipiodol emulsion injected intraperitoneally (14). It remained necessary to evalu-

ate peritoneal reactions, to quantitate the type and the amount of emulsion necessary, and to determine the timing of the examination.

### Material and Methods

Simple lipiodol emulsions in water are unstable. There are two types of stabilized lipiodol emulsions available:

1) AG 52315 Laboratoires *Guerbet* is a derivative of ultrafluid lipiodol with polyethylene-glycol monostearate, containing 46 g of iodine per 100 ml. The emulsion is obtained by mechanical dispersion, the average diameter of particles being related to the length of the agitation period. We have prepared two products:

a) coarse emulsion: 15 microns average diameter

b) fine emulsion : 4 microns average diameter

2) Stabilised iodolipid emulsion. AG 6099 Laboratoires *Guerbet* is a milky fluid produced from ultrafluid lipiodol, which contains soya lecithin (1.6 g/100 ml) and polyethylene monostearate (1.6 g/100 ml). The iodine content is 20 g per 100 ml.

The first series of experiments involved the comparison of the three emulsions (fine AG 52315, coarse AG 52315, AG 6099) including radiographic study and the sacrifice of three groups of 7 Wistar adult rats (225 to 375 g) receiving different quantities by the intraperitoneal route. Tables I and II detail the experimental plan. The second series of experiments concerned the minimum dose for the lymph node opacification. The rabbit was used because its larger size permitted better evaluation

Table I Coarse AG 52315 emulsion 2 ml/kg intraperitoneal injection

Number of Rats	Sacrifice	Opacification	Peritoneal reaction
1	15 min.	0	+
2	6 hr.	0	++
12	24 hr.	±	++
2	10 days	+	+(fibrosis)

Table II Fine AG 52315 emulsion 2 ml/kg intraperitoneal

Number of Rats	Sacrifice	Opacification	Peritoneal reaction
1	15 min.	0	+
2	6 hr.	0	++
2	24 hr.	+	++
2	10 days	++	+(fibrosis)

of the abdominal and thoracic lymphatic channels.

Lastly, an anatomic-pathologic study was performed on six groups of rats:

- 7 receiving 2 ml/kg of coarse AG 52315 emulsion.
- 7 receiving 2 ml/kg of fine AG 52315 emulsion.
- 10 receiving 0.15 ml/kg of AG 6099 emulsion, sacrificed at 4 days.
- 5 receiving 0.15 ml/kg of AG 6099 emulsion, sacrificed at 5 weeks.
- 10 receiving 0.15 ml/kg of physiologic saline sacrificed at 4 days a control group of 5 rats receiving no injections.

All X rays were performed using non screen film (Kodak PE 4006). The anatomic-pathologic specimens were interpreted without knowledge of the group to which the animal belonged.

## Results

### 1. Lymphatic drainage of the peritoneum.

*Abdomino-thoracic lymphatic* channels in the rat are too fine to be seen on standard X ray. In the rabbit, intraperitoneal injection opacifies anterior latero-sternal channels and a posterior channel analogous to the thoracic canal (fig. 1). The anatomic distribution is shown by the diffusion of patent blue injected intraperitoneally. There is a median anterior abdominal channel which divides in two laterosternal channels and a posterior channel which joins the thoracic canal (fig. 2). The lymphatic drainage pathways of the rabbit are very similar to those in man (15).

*Lymph node opacification* was present in rats receiving coarse emulsion at high doses (2 ml/kg). In this case the best images were seen late (3th to 14th days). No opacification

was seen with fine AG 52315 emulsion. The best results in the rabbit were seen with the stabilised AG 6099 emulsion. Opacification was rapid and of good quality with 0.8 ml/kg. Four to six pre and laterotracheal lymph nodes were visible (fig. 3). The distribution of the contrast in the node was studied by microradiography (fig. 4); opacification was dense and complete, with a slight predominance in the cortical zone.

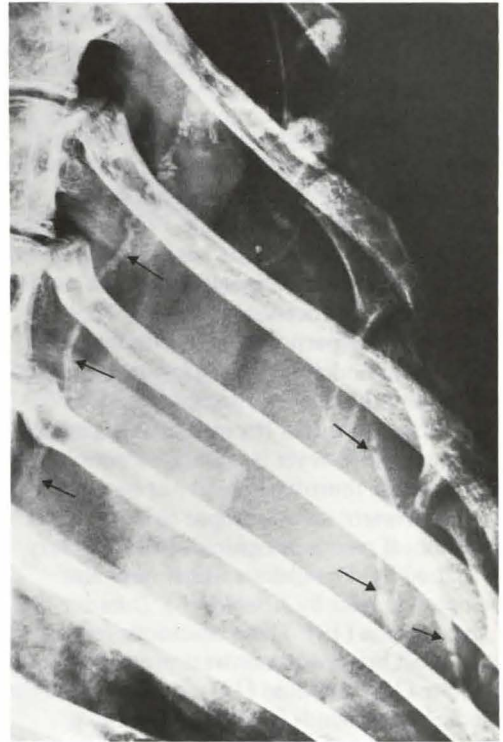

Fig. 1 Lateral radiography of the chest of a rabbit 30 min. after the intraperitoneal injection of 0.8 ml/kg of emulsion. Filling of laterosternal channels and thoracic duct.

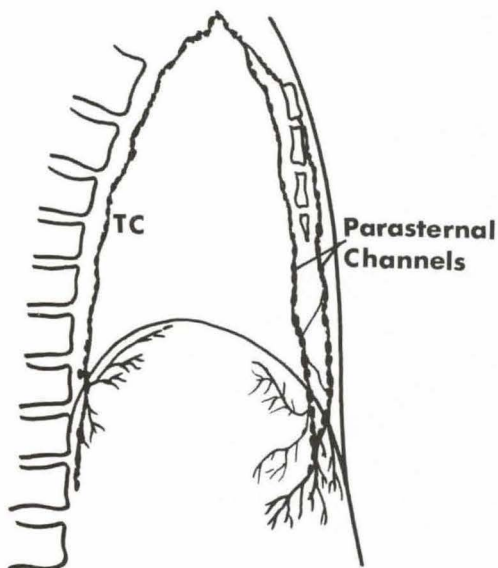


Fig. 2 Anatomy of abdomino thoracic lymphatic pathways.

In the rat, the 6099 emulsion also gave good results and permitted visualisation of posterior abdominal nodes analogous to coeliac and mesenteric nodes in 40 p. cent of cases (fig. 5).

## 2. Minimum dose.

Intraperitoneal injection of 2 ml/kg gives a good opacification of lymph nodes, but produces severe peritoneal reactions. With 0.14 ml/kg, opacification is less dense but still permits satisfactory analysis. 0.05 ml/kg was insufficient to opacify the ganglions (table III). The minimal useful dose is in the order of 0.15 to 0.20 ml/kg of AG 6099 in the rat and the rabbit.

Table IV

Product Intraperitoneal	Number of rats	Sacrifice	Peritoneal reaction		
			moderate	strong	necrosis
6099. 2 ml/kg	10	4 days		10	6
6099.0.15 ml/kg	10	4 days	6	4	2
Phys. saline 0.15 ml/kg	10	4 days	6	1	0
6099. 0.15 ml/kg	5	5 weeks	4	0	0
No injection	5	5 weeks	0	0	0

Table III Fine AG 6099. Intraperitoneal injection.

Number of Rats	Dose ml/kg	Lymphoid opaci- fication at 24 hrs
1	0,05	0
3	0,14	0
2	0,83	±
2	2	±

## 3. Peritoneal reactions.

High doses (2ml/kg) of emulsion injected intraperitoneally always led to peritoneal reactions. We studied this experimentally by sacrificing animals at variable times after the injection.

- At 15 minutes mesothelial desquamation was seen throughout the peritoneum.
- At 6 hours a fibrinous exudation with polymorphonuclear blood cells and macrophages was seen. A localized fibrinous exudate was grossly visible.
- At 24 hours diffuse edema and a frank exsudative reaction with vasculitis was apparent.
- At 8 days moderate fibrosis was present.
- After the 15th day a fairly dense collagenous sclerosis was seen with several granulomatous foci. Residual fatty material was seen in the middle layers.

Similar reactions were seen in the groups of animals receiving either the fine or coarse emulsion. Inflammatory peritonitis was found in the 15 animals of the first two groups, resulting in a fibrosis by the 8th day. Reducing the dose to 0.15 ml/kg did not avoid this reaction. The 10 rats sacrificed on the 4th day also had a peritoneal reaction. Two of the ten had signs of necrosis (table IV).

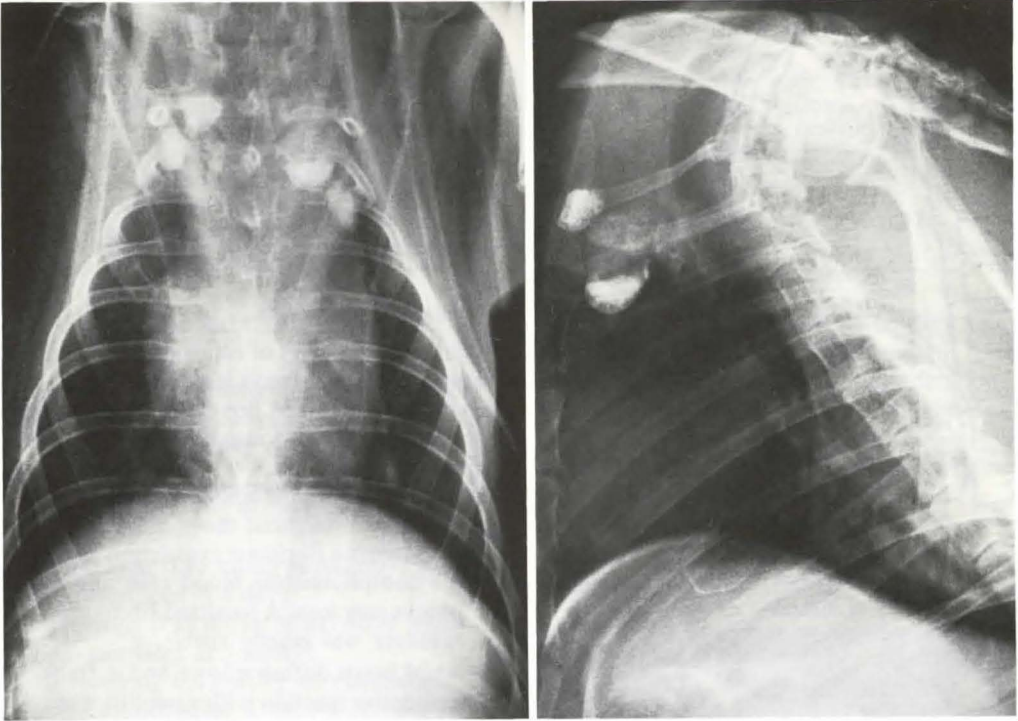


Fig. 3 Intraperitoneal injection of 0.8 ml/kg 6099 in a rabbit. Good filling of pre and laterotracheal lymph nodes.

This reaction apparently is a transitory, because late control (5 weeks) of a second group of rats showed a moderate peritoneal reaction without residual necrosis.

The control groups receiving physiologic saline also showed a peritoneal reaction usually moderate, but never with signs of necrosis. The control group which had never received injections showed normal peritoneum.

*Modifications of composition and particle size of the emulsion*

The peritoneal reaction was always seen and is not influenced by the type of materials used in the emulsion, as we saw it always both with glycol monostearate or soya lecithin. Actually, all intraperitoneal injections even with saline, resulted in transitory exsudative and macrophagic reactions in the rat. Necrotical lesions, much more serious, were only seen with high doses and with strong concentrations. Dilution of the emulsion

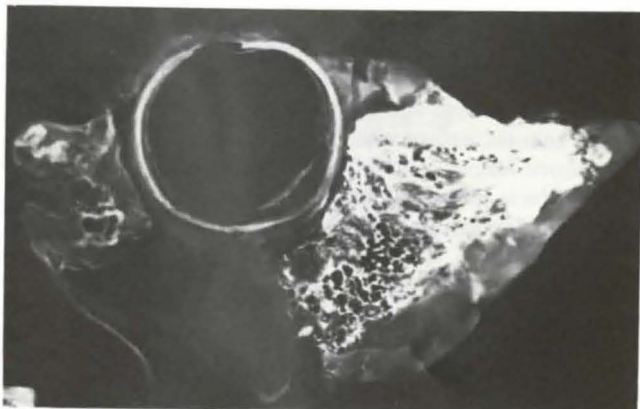diminishes the intensity of the reactions, but also diminishes the density of the lymph node opacification.

*Discussion*

Incidental opacification of mediastinal lymph nodes is seen in 4.5 per cent of lymphangiographies performed by pedal injection (16, 17). The observation of adenopathies revealed by this mean and not seen with other radiologic studies of the mediastinum suggests the value of a radiologic evaluation of these lymph nodes groups.

Our studies show that a new stable lipiodol emulsion can be used for indirect lymphography. Peritoneal drainage is rapid for fine particles (10 to 15 min.) and slower for coarse particles (1 to 5 days). Inconstant early opacification of the nodes is seen with the fine emulsion 6099. Late visualisation (8 to 13 days) was seen with the coarse AG

Fig. 4 Microradiographic study of a latero tracheal lymphnode. Opacification is dense, with a slight predominance in the cortical zone.



52315 emulsion. These results should be compared with *Jonsson's* (10). Nodal opacification is dense, and comparable to that obtained with pedal lymphography. It is persistent with sharp images remaining up to five weeks after injection. Mesenteric and coeliac ganglions were visible, but their morphology is not easily evaluated because of the residual intraperitoneal lipiodol which did not disappear until after several weeks. Only pre and laterotracheal mediastinal lymph nodes were visible, the interbronchial or intertracheo-bronchial nodes were not seen. The possible diagnostic usefulness of the opacification of the mediastinal lymph nodes groups, even if this is only partial, is sufficient to justify this experiment. Peritoneal reactions constitute the major problem with this type of examination. Lipiodol produces serious reactions. The pure lipiodol employed in hystero-graphy is well tolerated by the peritoneum, but intra-articular injection leads to severe arthritis and intense synovial reaction (18). Emulsification of lipiodol does not eliminate this problem. As others reported (19, 20), we also observed more or less intense peritoneal reactions with both fine and coarse emulsion. The emulsifying agents are probably partly responsible, but the reactions are identical with polyoxyethylene glycol and lecithin. Other less toxic agents must be found.

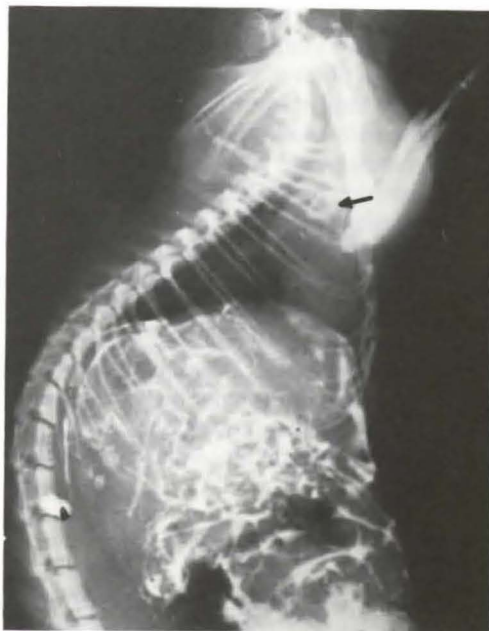


Fig. 5 Intraperitoneal injection of 2 ml/kg of fine emulsion in a rat. Opacification of laterotracheal lymphnodes.

However some conclusions can be drawn from our experiments:

- the disquieting histologic reactions did not accord with the clinical state of the animals, except when there were necrotic lesions. The inflammatory reaction is transitory; by the sixth week, four of five rats had a nearly normal peritoneum.
- Comparison of the groups receiving emulsions and those receiving physiologic saline showed that peritoneal injections can result in an inflammatory reaction, regardless of the product employed. This means that it is necessary to have at least three series in the study of any product injected in the peritoneum: untreated animals, those injected with sterile water or physiologic saline, and the tested product. It is this protocol that we have followed.
- The relation between the dose and the severity of reaction was clear. Severe reactions, including necrotic lesions were present in 6 of 10 cases with high doses (2 ml/kg) and 1 in 10 cases at low doses (0.15 ml/kg). The use of the low doses of a diluted contrast product was acceptable from the point of view of tolerance, but was usually insufficient to visualize the lymph nodes with conventional X rays. Computerized tomography might be useful in this connection by detecting small differences in attenuation created by an injection of very small quantities of contrast.

Mediastinal lymphography remains experimental, but our results showed that it is feasible and potentially valuable. If side effects may be diminished to an acceptable level, the clinical use of this technique could be interesting. But this requires less toxic emulsions, lower doses and evaluation by computerized tomography.

## References

- 1 *Ishida, O., H. Tachiri, S. Sone, Y. Taji, H. Uchida:* The experimental pulmonary and mediastinal lymphography  
In Progress in Lymphology. G. Thieme, Stuttgart 1967.

- 2 *Capua, A.:* Sullo studio dei linfatici della pleura, del polmone del pericardio per mezzo di thorostrast. *Radiologia Medica* 21 (1934) 119
- 3 *Menville, L.J. and J.N. Ane:* A Roentgen study of the absorption by the lymphatics of the thorax and diaphragm of thorium dioxide injected intrapleurally into animals. *Amer. J. Roentgenol* 31 (1934) 166
- 4 *Weyeneth, R. and A. Calame:* Recherches expérimentales sur les propriétés du sel iodé de Degkwitz. *J. Radiol. Electrol.* 28 (1947) 1–10
- 5 *Saito, M., W. Kamikawa, H. Yanagizawa:* Nouvelle méthode de radiographie des artères et des veines sur le vivant. *Presse Méd.* 101 (1930) 1725–1729
- 6 *Bennett, H. S., A. A. Shivas:* The visualization of lymph nodes and vessels by ethyl iodostearate (angiopac) and its effect on lymphoid tissue. *J. Fac. Rad.* 5 (1954) 261–266
- 7 *Oury, F.:* Essais de lymphographie chez l'animal par l'injection intraperitonéale de substances opaques. These. Paris 1956.
- 8 *Koehler, P. R.:* Radiographic visualization of the substernal lymph nodes. *Radiology* 85 (1965) 565–567
- 9 *Dumont, A. E.:* Roentgenography of the diaphragmatic and retrosternal lymphatics by intraperitoneal injection of contrast material. In Progress in Lymphology, G. Thieme, Stuttgart 1967
- 10 *Jonsson, K., T. Olin:* The study of iodized oil emulsion for indirect lymphography. *Invest. Radiol.* 9 (1974) 37–42
- 11 *Berdon, W. E., D. H. Baker, A. Poznanski:* Opacification of retrosternal lymph nodes following barium peritonitis. *Radiology* 106 (1973) 171–173
- 12 *Lawson, T. L., A. R. Margulis, J. A. Nadel, O. N. Rambo and W. G. Wolfe:* Intraperitoneal introduction of tantalum powder. A roentgenographic and pathologic study. *Invest. Radiol.* 4 (1969) 293
- 13 *Margulis, A., G. B. Cook, G. L. Tucker, S. L. Saltzstein:* Coeliography with iothalamic acid. Experimental study in dogs and rats. *Amer. J. Roentgenol* 90 (1963) 723
- 14 *Bacques, O., M. Laval-Jeantet, A. M. Laval-Jeantet, N. Chelloul:* Opacification chez l'animal des ganglions lymphatiques médiastinaux par injection intrapéritonéale d'une nouvelle émulsion iodée. *Ann. Radiol* 19 (1976) 535–540
- 15 *Rouviere, H.:* Anatomie des lymphatiques de l'homme. Masson Ed. Paris 1936.
- 16 *Weidner, W. A., R. M. Steiner:* Roentgenographic demonstration of intrapulmonary and pleural lymphatics during lymphangiography. *Radiology* 100 (1971) 533–539
- 17 *MacDonald, J. S., M. J. Peckham:* Lymphography in Smithers D., *Hodgkin disease.* Churchill Livingstone Edit., London 1973.

- 18 *Chevrot, A., F. Delrieu, J. M. Galmiche, G. Pallardy*: Hydarthrose récidivante du genou due au lipiodol. *J. Radiol. Electrol.* 55 (1964) 427-428
- 19 *Koehler, P. R., H. A. Rodriguez*: Radiography of the substernal nodes in experimental animals. *Invest. Radiol* 3 (1968) 165
- 20 *Kozakewitch, H. P. W., G. F. Gray, H. A. Baltaxe*: Opacification of the mediastinal nodes by the emulsions. *Invest. Rad.* 7 (1972) 48-55

*M. Laval-Jeantet, Laboratoire de Radiologie Expérimentale  
Lariboisiere - Saint-Louis School of Medecine 10, Avenue de Verdun, F 75010 Paris*