

Admittance Plethysmographic Evaluation of Undulatory Massage for the Edematous Limb

Z. Yamazaki, Y. Fujimori, T. Wada, T. Togawa*, K. Yamakoshi*, H. Shimazu*

2nd Surgical Department, Tokyo University Hospital,

* Institute for Medical and Dental Engineering, Toky Medical and Dental University, Tokyo, Japan

Summary

A new apparatus, called *Hadomer* has been developed for the treatment of peripheral lymphedema and venous disorder. It has cuffs with 5 rooms, through which the air pressure moves from periphery to proximal point, just like surging waves. The peripheral stagnant lymph and venous blood are displaced toward the heart by this pneumatic massage.

Hadomer has been applied to more than 400 patients with the edematous limbs, with satisfactory results, such as decrease of swelling, pain and induration. These clinical results have been also confirmed by electrical admittance plethysmography which is useful to measure noninvasively the edematous volume and the blood flow.

The admittance of the edematous limbs is high and after massaging with *Hadomer* it approaches normal range. The blood flow in the diseased limbs is less than the healthy one and it is observed better after pneumatically massaging.

A new apparatus, called "*Hadomer*" has been devised for the treatment of peripheral lymphedema and venous disorder. This device has been accomplished through our studies (1) on the lymphatic circulation for the last five years. *Hadomer* has cuffs with five rooms, through which the air pressure moves from periphery to proximal point, just like surging waves (Fig. 1). The peripheral stagnant lymph and venous blood are displaced toward the heart by this pneumatic massage.

The edematous volume and blood flow have been measured by electrical admittance plethysmography in order to evaluate the undulatory massage for the edematous limb.

Material and Method

Hadomer has been applied to more than 360 patients with postmastectomy edema of the arms and 80 patients with edema of the lower

limbs. The clinical results such as decrease of swelling, pain and induration have been satisfactory. Thirty two of these patients have been at random selected for this investigation.

In Fig. 2 the principle of electrical admittance plethysmography is illustrated. The admittance is a unit representing the conductivity of alternating electric current, therefore the admittance figure is proportional to the retention of the fluid in the tissue. The admittance change is measured by the tetrapolar technique (2) and specific electrical conductivity (3) is calculated by assuming the limb as an uniform

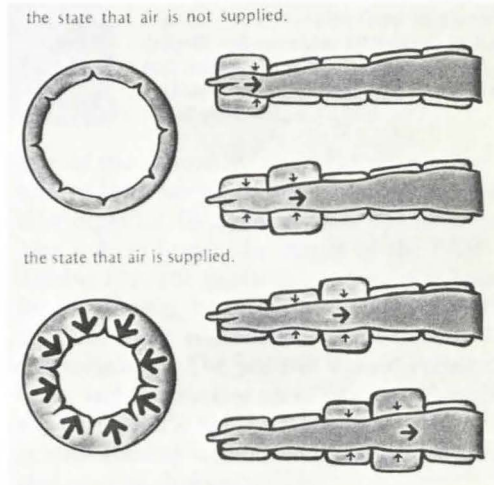
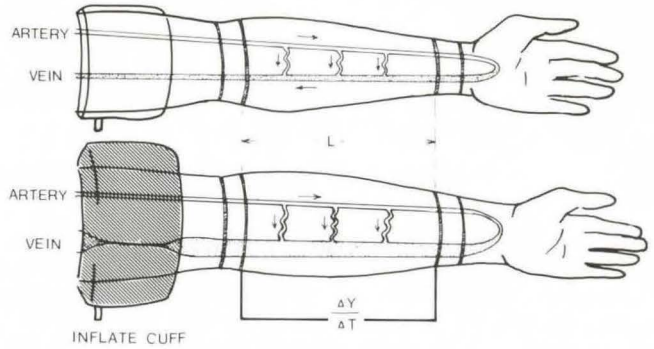


Fig. 1 Principle of undulatory massage. When air is supplied to the cuff the outside of which is reinforced, the cylindrical cuff tries to swell inside. Making use of this force swelling into inside, the treatment is made by massaging the diseased part, as shown in the above illustration



$$\text{LIMB BLOOD FLOW (F}_L\text{)} = \rho_b \times L^2 \times \frac{\Delta Y}{\Delta T}$$

Fig. 2 Principle of electrical admittance plethysmography

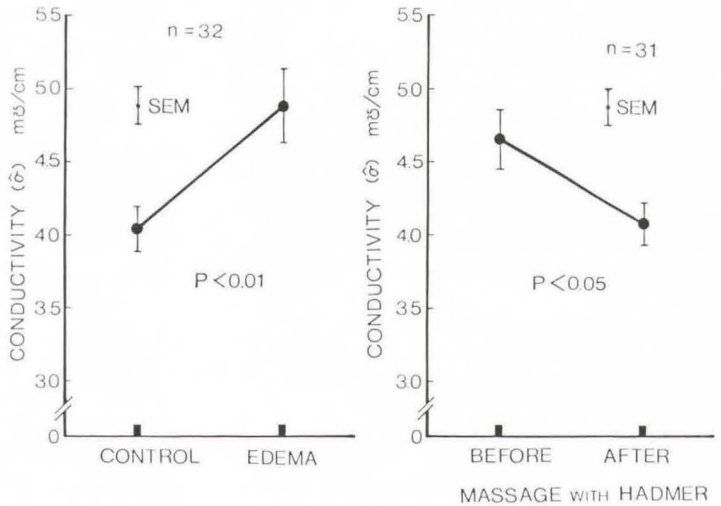


Fig. 3 Conductivity of healthy and edematous arm (left side) Conductivity of post-mastectomy edema of the arm before and after massage with Hadomer (right side)

cylindrical volume conductor. The arterial inflow to the segment of the arm can be calculated from the initial slope of the corresponding volume variation with time. The blood volume change following venous occlusion (ΔV ; ml) is calculated from the admittance change (ΔY ; mho) by the following equation (3);

$$\Delta V = \rho_b L^2 \Delta Y \quad (1)$$

where ρ_b is the blood resistivity (Ω cm) and

L is the length of the segment (cm). The blood flow can be obtained from the initial slope ($[dY/dt]_{t=0}$; mho/s) of the admittance change (3).

Results

The conductivity of the edematous arm is high and after massage by *Hadomer*, it approaches to the normal range (Fig. 3).

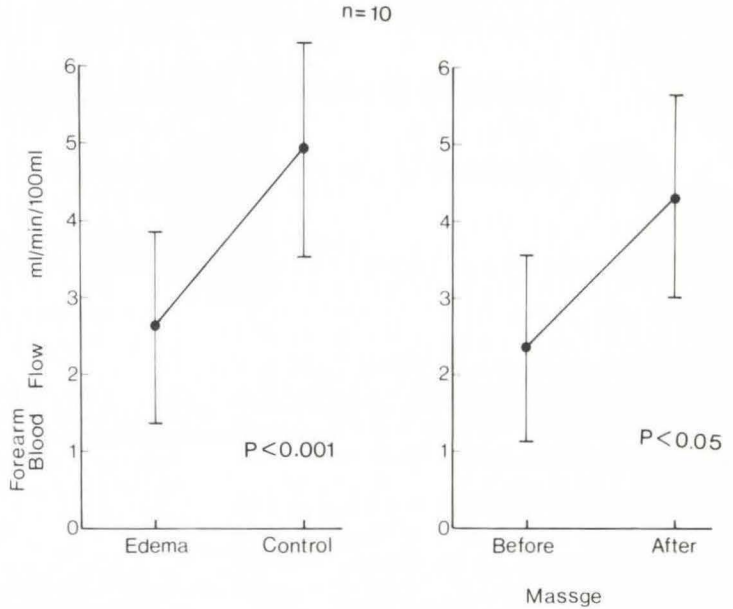


Fig. 4 Forearm blood flow of the patients with postmastectomy edema of the arm; edematous and healthy arm (left side) before and after massage with Hadomer (right side)

The blood flow in the diseased arm is less than the healthy arm and it is observed better after undulatory massage (Fig. 4).

Conclusion

The undulatory massage has been proved to be effective in decreasing the stagnant lymph and also in improving the blood

flow in the edematous arm using electrical admittance plethysmography.

References

- 1 Yamazaki, Z. et al.: Jinkozoki (Artificial Organ) 2 (1973) 380-386
- 2 Nyboer, J.: Circulation 2 (1950) 811-821
- 3 Yamakoshi, K. et al.: Proc. of the 30th ACEMB., Los Angeles, Calif. (1977) p. 41

Z. Yamazaki, 2nd Surgical Department, Tokyo University Hospital, Tokyo, Japan