

Peripheral Lymphocyte Count in Untreated Non-Hodgkin's Lymphoma Patients and Their Lymphographic Findings

Sho Matsubara, M.D., Soji Suzuki, M.D., Junichi Horiuchi, M.D.,
Hitoshi Shibuya, M.D., Manabu Maeda, M.D.¹ and Hiroshi Miyamoto, M.D.²

1) From the department of Radiology, School of Medicine, Tokyo Medical and Dental University, Tokyo, Japan

2) Department of Radiology, School of Medicine, Keio University, Tokyo, Japan

Summary

The relation between grades of foaminess in lumbar, iliac and inguinal nodes on bipedal lymphograms, and peripheral lymphocyte counts was assessed in patients with untreated non-Hodgkin's lymphoma. The lymphocyte counts were widely distributed in and around the normal range in patients with normal lymphographic findings, but in patients with increased grades of foaminess they were depressed to a marked degree. The decrease in peripheral lymphocyte counts in patients revealing no pathological grades of foaminess may be caused by the occult abdominal non-Hodgkin's lymphoma or may suggest the impending extension of the disease in these nodal chains.

Non-Hodgkin's lymphoma, a malignant disease originating in the immunological organs, affects patients by altering their immunological functions. As the disease advances, the lymphocytes are progressively depleted, and the prognosis deteriorates (1, 2, 3). Although lymphography has been widely used in the diagnosis and management of malignant lymphoma (4, 5), few attempts have been made to correlate the lymphographic pattern of non-Hodgkin's lymphoma with the patients' immunological status. In the present study, the relation between the lymphographic appearances of lymph nodes and the number of peripheral lymphocytes including their subpopulations is analyzed.

Materials and Methods

Seventy-two cases of untreated non-Hodgkin's lymphoma were histologically confirmed prior to the inception of therapy. Those with leuk-

emic changes and/or those complicated by diseases which might reveal reactive lymphoid hyperplasia were excluded. Patients who had been surgically examined and/or those who had received treatment for the disease in their abdominal cavities before lymphography had been performed were also excluded.

By using Ann Arbor classification (6), clinical stages were determined by thorough physical and laboratory examinations, lymphography, bone marrow aspiration, liver and ⁶⁷Ga scans. Lymphography was performed by the standard bipedal route, and lymphographic abnormality evaluated according to the Takahashi and Abrams criteria (4, 5, 7, 8).

To record the results, the lymph node chains were divided into 7 anatomical areas: right and left inguinal, right and left iliac, common iliac, and right and left lumbar chains. Foaminess or filling defect of the lymph node was the basis for quantitative analysis; however, other terms such as granular, reticular, lacy, blubby or scattered were also used to describe internal node appearance (4, 5). The filling defect was used to express lymph node involvement only when foaminess could not be evaluated.

The degree of foaminess or filling defect was classified by the grade 0–3 determined by Takahashi and Abrams (8) (Fig. 1), but for the sake of convenience, these grades were arbitrarily assigned scores, i.e. grade 0 = 10, grade 1 = 40, grade 2 = 70, and grade 3 = 100. With respect to the filling defect, grade 0 in-

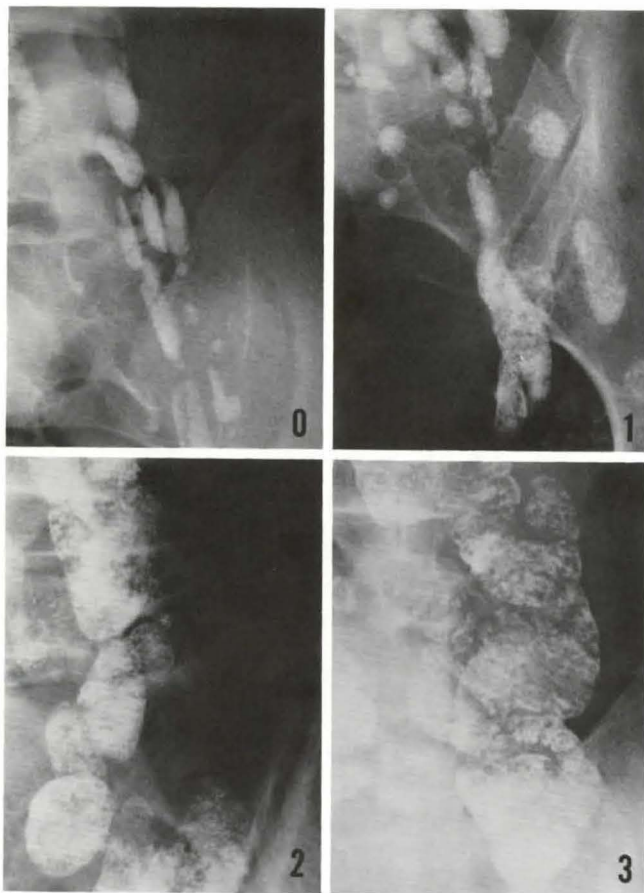


Fig. 1 Standard lymphograms for evaluation. Foaminess was classified into grades 0, 1, 2 and 3

dicating no filling defect, grade 1 less than 1/3 replacement of the node, grade 2 1/3 to 2/3 replacement, and grade 3 more than 2/3 replacement. The total score was obtained by adding the individual scores for the degree of foaminess or filling defect in all lymph nodes greater than 5 mm in diameter in the seven anatomical regions.

Peripheral lymphocyte counts, calculated from white blood cell counts and differential counts on Giemsa-stained preparations, were performed within a week before lymphography. In addition, lymphocyte subpopulations (2, 3, 9) in 43 patients were examined for rosette-forming cells by using sheep red blood cells and for complement receptor carrying lymphocytes. Only the rosette-forming cell values are analyzed in this study.

The radiologist evaluating lymph nodes foaminess was not informed histology, stage or lymphocyte counts, and the sign test was used for statistical analysis.

Result

The peripheral lymphocyte counts were plotted against the total score assigned to the degree of foaminess in lymph nodes evaluated on lymphograms in the adenographic phase (Fig. 2). As shown, patients with a foaminess score above 200 had low peripheral lymphocyte counts, resulting in an L-shaped curve on a linear scale.

In stage I and II patients, the peripheral lymphocyte counts widely ranged between 860 and 4550/mm³. However, in stage III patients,

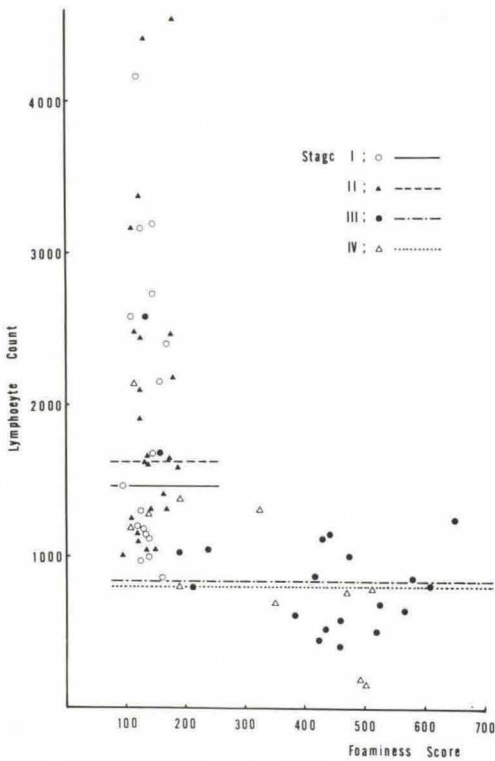


Fig. 2 Peripheral lymphocyte counts, plotted against total foaminess score in patients classified according to the clinical stage of the disease
 —○— stage I; —▲— stage II; —●— stage III;
 - - - Δ - - - stage IV. Cross lines indicate the median counts

12 out of 17 with foaminess score above 200, reveal decreased lymphocyte counts below $1000/\text{mm}^3$, while all of three patients with foaminess score below 200 had lymphocyte counts of above $1000/\text{mm}^3$. The difference between these two groups was statistically significant ($P < 0.05$). Five out of six stage IV non-Hodgkin's lymphoma patients with a foaminess score above 200 had lymphocyte counts below $1000/\text{mm}^3$, but only one of five such patients with a total foaminess score below 200 exhibited marked lymphocytopenia below $1000/\text{mm}^3$.

Ninety two percent (45 out of 49) of those with foaminess score below 200 and 26% (6 out of 23) of those with foaminess score

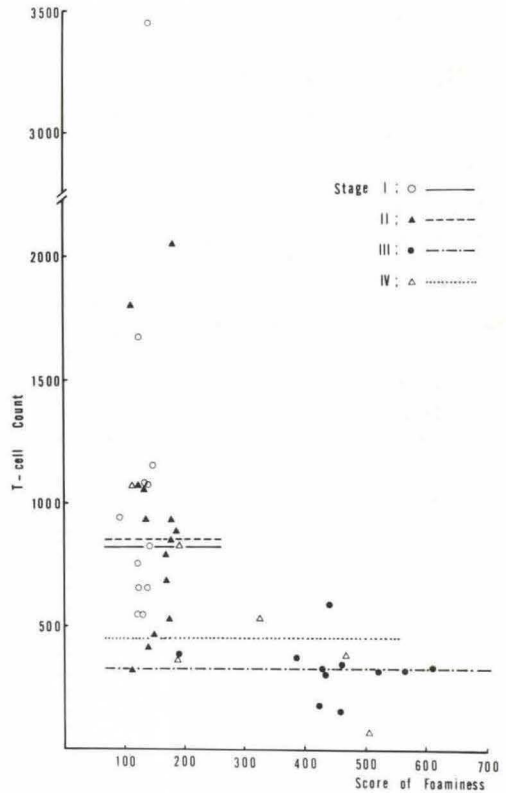


Fig. 3 T-lymphocyte counts, plotted against the total foaminess score.
 —○— stage I; —▲— stage II; —●— stage III;
 - - - Δ - - - stage IV. Cross lines indicate the median counts

above 200 constituted the patients with lymphocyte counts above $1000/\text{mm}^3$. The difference thus obtained was also statistically significant ($P < 0.01$)

In Fig. 3, T-lymphocyte counts of 43 clinically staged patients were plotted against foaminess scores. Again, those with a total foaminess score above 200 exhibited an abrupt decrease in T-cell counts.

Discussion

In malignant lymphoma patients, the immunological response, especially cellular reactivity, is impaired (1, 2, 3, 9).

Peripheral lymphocyte counts, including T-lymphocytes, frequently decrease, with the

extent of the decrease varying with the stage and duration of the disease. In the present study, the relation between peripheral lymphocyte counts, including T-lymphocytes, and foaminess score from pre-therapy lymphograms has been analyzed.

The number of peripheral lymphocytes decreased in patients with foaminess score above 200. In cases with grade 2 or 3 foaminess in the lumbar and/or iliac nodal chains, there were conspicuously lowered peripheral lymphocyte counts. As illustrated in Fig. 3, the number of T-lymphocytes decreased as the foaminess score increased, resulting in L-shaped distribution on a linear scale. This conforms with the results obtained with the total lymphocyte counts. Less than 500 T-lymphocytes/mm³ were present in all but two patients with foaminess score greater than 200. Among 27 patients with T-lymphocyte counts above 500/mm³, 25 had foaminess score below 200 ($P < 0.01$).

Experimental studies show that small lymphocytes, especially T-lymphocytes, enter nodes by crossing the walls of post-capillary venules. Some of the recognition receptors on lymphocytes control this passage through the capillary walls, so that loss of these receptors alters migration pattern (9, 10). In recirculation from the lymphoid tissue to the blood, a large number of lymphocytes pass through the thoracic duct with other routes probably playing a minor role (11).

Yoffey et al. (12), who investigated the source of lymphocytes in the cannulated thoracic duct, noted a loss of weight and reduction in the number of lymphocytes. Since initial lymphopenia in untreated patients with non-Hodgkin's lymphoma may result in a conspicuous reduction in lymphocytes within the lumbar and iliac nodal chains, the lumbar and iliac nodes may serve as major reservoirs which, upon a decrease in peripheral lymphocytes, may be uniformly emptied to supplement this loss of circulating lymphocytes.

If most of the lymph nodes with grade 2 or 3 foaminess in the present study are involved by non-Hodgkin's lymphoma cells, the obtained pattern of lymphocyte distribution

against foaminess suggests that such abnormal findings may be preceded by a marked decrease in the peripheral blood lymphocyte counts. Non-Hodgkin's lymphoma cells more likely migrate from the primary lesion to these lymphocyte-depleted lumbar, iliac and inguinal nodes.

Wong et al. (13) reported that the abdominal regions appeared to be common sites for the spread of non-Hodgkin's lymphoma of the head and neck. According to Heifetz et al. (14) by staging laparotomies, occult abdominal disease was frequently discovered in lymphography staged I and II patients. The results shown here should contribute to the evaluation of lymphograms in non-Hodgkin's lymphoma, especially in equivocal cases. However, further study on the correlation between impaired immunological function in such patients classified on Rappaport system and lymphograms, especially in the cases of occult malignant lymphoma, may result in some insights on the treatment of the disease.

References

- 1 Lapes, M., M. Rosenzweig, B. Barbieri, et al.: Cellular and humoral immunity in non-Hodgkin's lymphoma. *Am. J. Clin. Pathol.* 67 (1977) 347-350
- 2 Hansen, J.A., R.A. Good: Malignant disease of the lymphoid system in immunological perspective. *Human Pathology* 5 (1974) 567-599
- 3 Lukes, R.J.: The immunologic approach to the pathology of malignant lymphomas. *Am. J. Clin. Pathol.* 72 (1979) 657-669
- 4 Hessel, S.J., D.F. Adams, H.L. Abrams: Lymphology in lymphoma. (In) Clouse, M.E.ed.: *Clinical Lymphography*. Baltimore, Williams & Wilkins, 1977, Chap. 8, 160-184
- 5 Kuisk, H.: Interpretation of lymphograms. (In): *Technique of Lymphography and Principles of Interpretation*. St. Louis, Warren H. Green, 1971, Chap. 20, 212-283
- 6 Carbone, P.P., H.S. Kaplan, K. Musshoff, D.W. Smithers, M. Tubiana: Report of the committee on Hodgkin's disease staging classification. *Cancer Res.* 31 (1971) 1860-1861
- 7 Gordon, I., D.J. Stoker, J.S. MacDonald: The lymphographic pattern in Hodgkin's disease: A correlation with the Rye histological classification. *Clin. Radiol.* 27 (1976) 57-64
- 8 Takahashi, M., H.L. Abrams: The accuracy of lymphographic diagnosis in malignant lymphoma. *Radiology* 89 (1967) 448-460

- 9 *Parker, J.W.*: Immunologic basis for the redefinition of malignant lymphomas. *Am. J. Clin. Pathol.* 72 (1979) 670-686
- 10 *Gowans, J.L., E.J. Knight*: The route of re-circulation of lymphocytes in the rat. *Proc. Roy. Soc. B* 159 (1964) 257-282
- 11 *Elves, M.W.*: The circulation and life span of lymphocytes. (In): *The Lymphocytes*. London Lloyd-Luke, 1972, Chap. 2, 59-111
- 12 *Yoffey, J.M., W.J.C.C. Rich, M.K. Tidnan, B.H. Cummins, R.R. Roy*: The source of the lymphocytes in thoracic duct lymph during prolonged drainage. *Ann. N.Y. Acad. Sci.* 113 (1964) 1053-1065
- 13 *Wong, D.S., L.M. Fuller, J.J. Butler, C.C. Shul-lenberger*: Extranodal non-Hodgkin's lymphoma of the head and neck. *Am. J. Roentgenol.* 123 (1975) 471-481
- 14 *Heifetz, L.J., L.M. Fuller, R.W. Rodgers, et al.*: Laparotomy findings in lymphogram-staged I and II non-Hodgkin's lymphomas. *Cancer* 45 (1979) 2778-2786

Sho Matsubara, M.D., Department of Radiology, School of Medicine, Tokyo Medical and Dental University 5-45, Yushima 1-chome, Bunkyo-ku, Tokyo, Japan 113