

Iotasul, a Water-soluble Contrast Agent for Direct and Indirect Lymphography

Results of Preclinical Investigations

H.M. Siefert, W. Mützel, C. Schöbel, H.-J. Weinmann, B.I. Wenzel-Hora and U. Speck

Research Laboratories of Schering Berlin (West) and Bergkamen, Federal Republic of Germany

Summary

Iotasul, a non-ionic dimeric water-soluble contrast agent with outstanding physico-chemical properties is well suited for direct as well as indirect lymphography, as demonstrated in experimental animals. The contrast medium is eliminated practically completely within 24 hours by the renal route. The tolerance of this agent is far better than that of oily contrast media.

Radiological investigation of the lymphatic system is currently performed by injecting oily contrast media into surgically exposed lymphatic vessels. Conventional water-soluble X-ray contrast media are not well suited for this kind of diagnostic procedure. During intralymphatic infusion these contrast medium solutions spread rapidly into the surrounding tissues, cause discomfort in patients and become increasingly diluted by the lymph. This leads to blurred X-rays, rapidly increasing loss of contrast and, thus, to incomplete visualization of the lymphatic system (1, 2, 3, 4, 5, 6, 7, 8, 9, 10, 11).

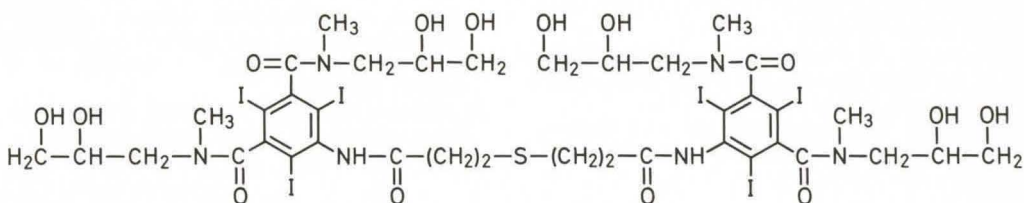
It seems that among other causes, the high osmotic pressure and low molecular weight are responsible for the short retention time of these contrast medium solutions in the lymphatic system.

In the Schering research laboratories water soluble x-ray contrast media have been developed that differ from conventional contrast agents, for instance, in that they have a higher molecular weight and a lower osmotic pressure.

The aim of the present communication is to give a preliminary report on preclinical investigations performed with a representative of this class of substances which is especially well suited for lymphographic investigations. The proposed INN for the radio-opaque compound is iotasul.

Material and Methods

All investigations were performed with an aqueous formulation of iotasul having an iodine content of 275 or 300 mg/ml.



Chemical structure of Iotasul

1. Chemistry of the radio-opaque compound

Chemical name: 5,5'-(4-thiaheptanedioyl-di-imino)-bis[2,4,6-triiodoisophthalic acid-bis-(2,4-dihydroxypropyl-N-methyl)diamide]
(see formula p. 150).

Empirical formula: $C_{38}H_{50}I_6N_6O_{14}S$

Molecular weight: 1608

Iodine content: 47%

2. Physico-chemical properties of an aqueous formulation of iotasul

Iodine-content	Viscosity (MPas)	Density at 37°C (kg/l)
275 mg/ml	19.8	1.30
350 mg/ml	32.9	1.32

If an aqueous formulation of iotasul is infused into body fluids such as serum or lymph, it separates into two phases having different degrees of molecular association. The more highly associated phase – it has an apparent molecular weight of more than 100,000 and an iodine content of about 450 mg/ml – can be demonstrated in the form of ultrafine droplets or streaks sinking to the bottom of a test tube filled with human serum (see Fig. 1).

By shaking, this highly associated phase is increasingly disassociated, which means it dissolves to give a monophasic, clear solution.

3. Lymphographic investigations

All X-ray studies were performed in anaesthetized dogs and monkeys. Anaesthesia was performed by intravenous administration of Combelen® + 1-Polamivet® or Nembutal® and inhalation of evaporated Ethrane®

a) Direct lymphography

The contrast medium solutions were injected at different volumes (3–15 ml/animal) into a superficial lymph vessel of a hind limb with an automatic injection pump at a rate of 0.08 ml/min.

b) Indirect lymphography

The contrast medium solutions were injected at different injection sites as described in Table 1.

The administration was performed manually or with an automatic injection pump at a rate of 0.02 to 0.08 ml/min.

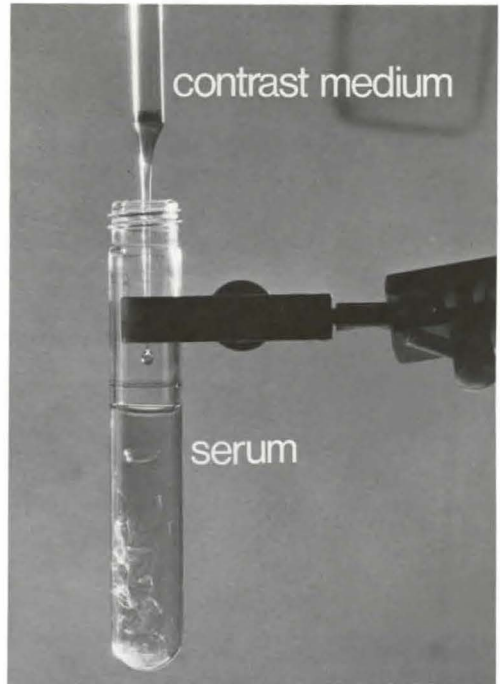


Fig. 1 Physico-chemical properties of iotasul. Separation of an aqueous formulation into two phases

4. Pharmacokinetics

All investigations were performed in dogs, anaesthetized with Combelen® + 1-Polamivet®, injected intravenously. The contrast medium solution (275 mg iodine/ml) was administered at a dose of 300 mg iodine/kg intralymphatically, as described in Material and Methods 3a. The concentration of iodine was measured in the blood, urine and faeces by x-ray fluorescence analysis over a period of four days.

The urine was analyzed for metabolites by thin-layer chromatography.

5. Toxicity tests

a) Systemic toxicity

Systemic toxicity of the contrast medium solution (275 mg iodine/ml) was tested by intraperitoneal, subcutaneous and intragastric administration of various volumes in mice and rats. The LD₅₀ values of the contrast medium were determined.

Table 1 Injection sites for indirect lymphography

Species	Injection site	Lowest volume of contrast medium necessary to opacify the first lymph node stage
dog	popliteal lymph node	2.0 ml/animal
	mandibular lymph node	1.2 ml/animal
dog	parenchyma of the mammary glands	1.0 ml/animal
	parenchyma of the testicle	3.0 ml/animal
	mucosa of the vagina	1.5 ml/animal
	mucosa of the rectum	2.0 ml/animal
	mucosa of the stomach	1.0 ml/animal
	tissues of the prostate gland	10.0 ml/animal
	skin of a hind paw	1.0 ml/animal
	skin of the neck	1.0 ml/animal
monkey	parenchyma of the testicle	3.0 ml/animal
	mucosa of the urinary bladder	1.5 ml/animal
	skin of a foot or hand	8.0 ml/animal

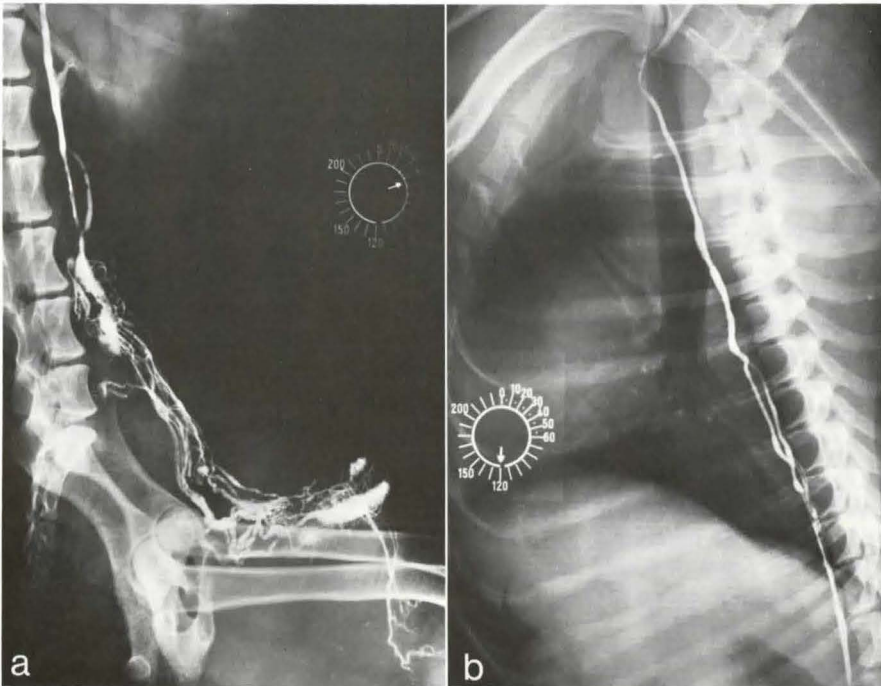


Fig. 2 Direct lymphography in dog. a) Opacification of inguinal and iliac lymph nodes with afferent lymph vessels and lumbar trunks after intralymphatic (hind limb) administration of iotasul (300 mg iodine/ml) infusion volume: 3.75 ml. b) Opacification of the thoracic duct after intralymphatic (hind limb) administration of iotasul (300 mg iodine/ml) infusion volume: 10.0 ml

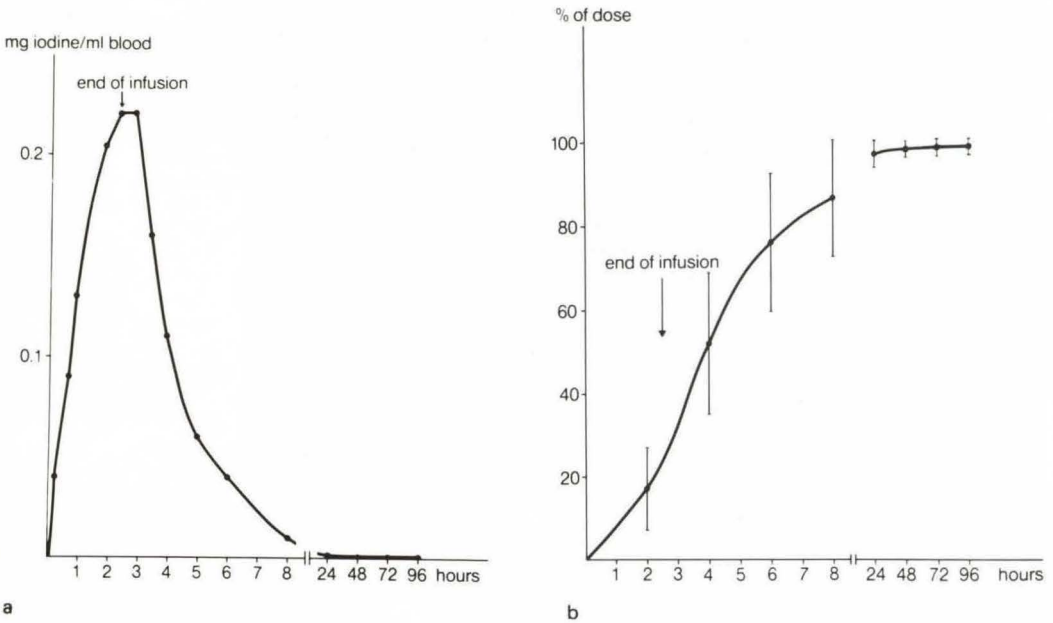


Fig. 3 Pharmacokinetics in dog after intralymphatic (hind limb) administration of iotasul (275 mg iodine/ml). Dose: 0.3 g iodine/kg; a) blood level, mean of five animals, b) cumulative renal excretion, mean of five animals

b) Local toxicity

The tolerance of the contrast medium administered intralymphatically or intracutaneously, as described in Material and Methods 3a and b, was investigated in the lymphatic system, the heart, lungs, kidneys, liver and spleen by light and electron microscopic methods.

Results and Discussion

Based on the physico-chemical properties of aqueous formulations of iotasul, as described above, and the extremely low osmotic pressure typical of non-ionic dimeric contrast media, iotasul is particularly well suited to lymphographic investigations.

When carrying out direct lymphography the contrast medium showed a strikingly low tendency to spread through the walls of lymphatic vessels because of its high degree of association. The continuing flow of lymphatic fluid did not influence contrast quality in any visible way. Thus, the retention of iotasul in the lymphatic system was sufficient for satisfactory lymphographic investigations. The

quality of contrast and detail of the lymphatic system, visualized by iotasul, was as good as that obtained after administration of oily contrast media. Information which is usually obtained in two separate stages after instillation of oily contrast media is simultaneously available after intralymphatic infusion of iotasul, as demonstrated in dogs (see Fig. 2a).

The course of the thoracic duct up to its entry into the venous system could be visualized homogeneously with the new contrast medium (see Fig. 2b).

Immediately after commencement of intralymphatic administration of iotasul in the dog a continuous increase of blood iodine concentration could be demonstrated. At the end of infusion of the contrast medium the maximum blood iodine concentration was about 0.2 mg/ml (see Fig. 3a). This value corresponds to about 4% of the dose in total blood volume of the dog. After the end of infusion blood iodine concentration decreased continuously with a biological half-life of about one hour, a value consistent with that of conventional X-ray contrast media for urographic investigations.

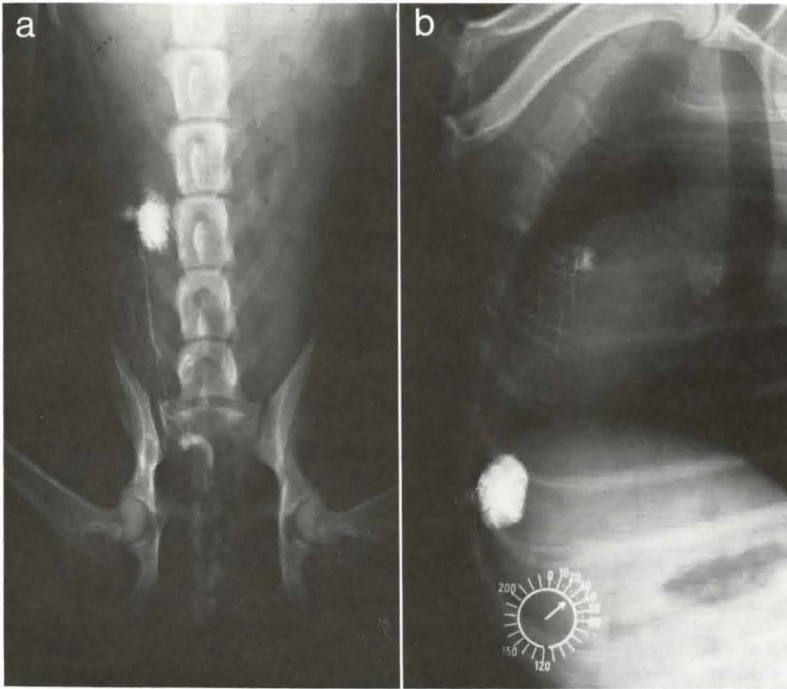


Fig. 4 Indirect lymphography in dog.

a) Opacification of a superficial inguinal lymph node after intraparenchymal (abdominal mammary gland) administration of iotasul (300 mg iodine/ml) injection volume: 1.0 ml; b) Opacification of an axillary lymph node after intraparenchymal (thoracic mammary gland) administration of iotasul (300 mg iodine/ml) injection volume: 1.5 ml

After intralymphatic administration in the dog, elimination of iotasul is practically complete within 24 hours by the renal route (see Fig. 3b). Less than 2% of the dose is excreted with the faeces.

A thin-layer chromatographic analysis of dog urine did not reveal any biotransformation of this contrast agent.

Visualization of the lymphatic system comparable to that after intralymphatic infusion of iotasul could also be achieved by injecting the contrast medium into lymph nodes, a procedure which might be termed indirect lymphography.

Both after intralymphatic and intranodal administration of the contrast medium the first lymph node group of organs, which is important for early recognition of metastatic involvement, could be visualized very occasionally.

By using indirect methods, as described in Ma-

terial and Methods 3b, it was possible to visualize these lymph nodes excellently with iotasul (see Figs. 4–6). Intraparenchymal, submucosal, and intracutaneous administration of the contrast medium might induce aqueous infiltration and swelling of the connective tissue opening the endothelial cells of the lymph capillaries at the intracellular junctions. The pressure gradient between the connective tissue and the lymphatic system seems to be responsible for passage of the contrast medium into the lymph capillaries and the intralymphatic pathway (*vis a tergo*). Therefore, areas well drained with lymphatics seem to be the most suitable injection sites for indirect lymphography.

By slow intratissue infusion of the contrast medium at different injection sites simultaneously, it was also possible to opacify further lymph nodes stages.

After administration (end of infusion) of iota-

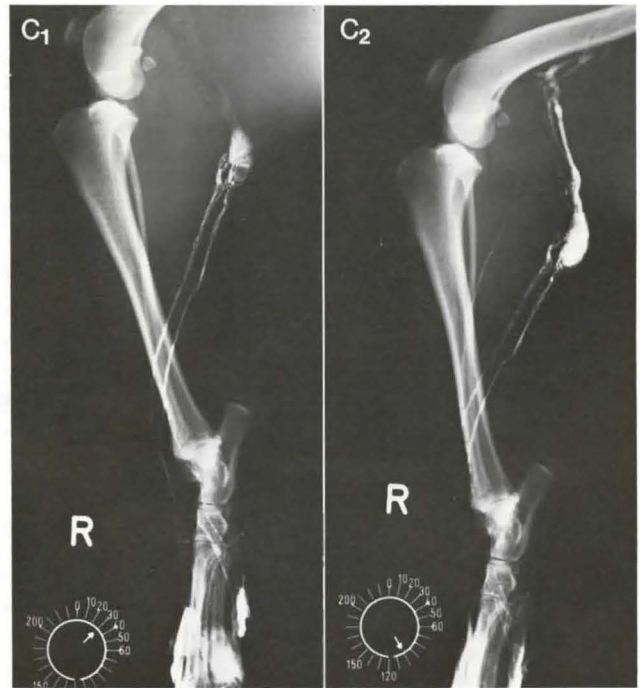


Fig. 4c₁—c₂

c₁) Opacification of a popliteal lymph node after intracutaneous (hind paw) administration of iotasul (300 mg iodine/ml) infusion volume: 2.0 ml;
 c₂) Opacification of a popliteal lymph node and efferent lymphatic vessels leading to an iliac lymph node after intracutaneous (hind paw) administration of iotasul (300 mg iodine/ml) infusion volume: 4.0 ml

Table 2

Route of administration	Species	LD ₅₀ (g iodine/kg)
intraperitoneal	rat	> 11
	mouse	> 14
	dog	> 10
subcutaneous	rat	> 11
	mouse	> 14
intra-gastric	rat	> 11
	mouse	> 14

sul, opacification of the lymphatics and the regional lymph nodes could be demonstrated by X-rays for about 45 minutes.

The systemic toxicity of iotasul after intraperitoneal, subcutaneous, and intra-gastric administration was generally low in mice as well as in rats (see Table 2). Even after the highest tested doses of this contrast medium no mortality could be demonstrated.

After intralymphatic or intratissue administration of iotasul in the dog no inflammatory reactions or other pathologic alterations could be demonstrated in the lymphatics system, in the heart, lungs, kidneys, spleen, and liver, either by light microscopic or electron microscopic methods (*Huth, F.* and co-workers, unpublished results).

Conclusion

Iotasul seems to meet the essential requirements for lymphography:

- adequate radiopacity
- very low diffusion through lymphatic vessel walls
- good local and systemic tolerance
- easy passage from tissues into the lymphatic system
- short retention time, yet sufficient for radiological work.

The following clinical advantages in direct lymphography could be attributed to the water-soluble contrast medium iotasul:

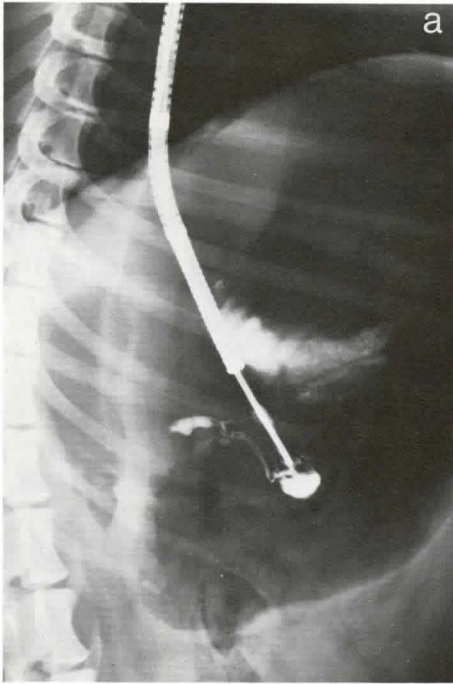


Fig. 5a

Fig. 5 Indirect lymphography in dog.

a) Opacification of a gastric lymph node after submucosal (stomach) administration of iotasul (275 mg iodine/ml) injection volume: 1.0 ml.

b, c) Opacification of sacral lymph nodes after submucosal (vagina) administration of iotasul (300 mg iodine/ml) infusion volume: 6.0 ml

1. The ability to recognize details of the lymphatic system is better than after administration of oily x-ray contrast media.
2. The tolerance of iotasul is far better than that of oily contrast media. There is no risk of microembolism in the lungs or pathologic alterations in the lymphatic system.
3. The diagnostic procedure can be performed within a short time. Less radiation exposure for the patient is probable.

In addition, iotasul seems to be most suitable for indirect lymphography:

4. Radiological investigation of the lymphatic system is possible without surgery. Local anaesthesia is not necessary. There is less chance for secondary infection or allergy to vital dyes.

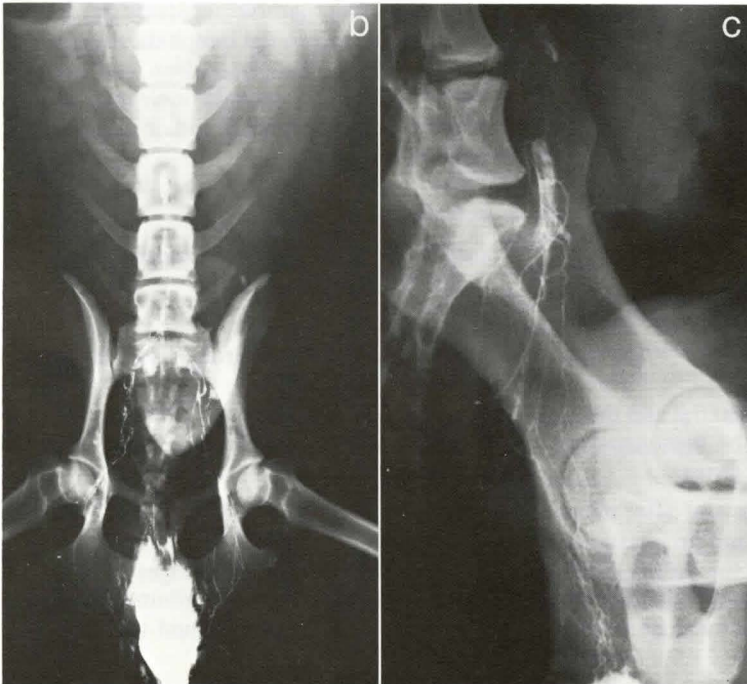


Fig. 5b-c

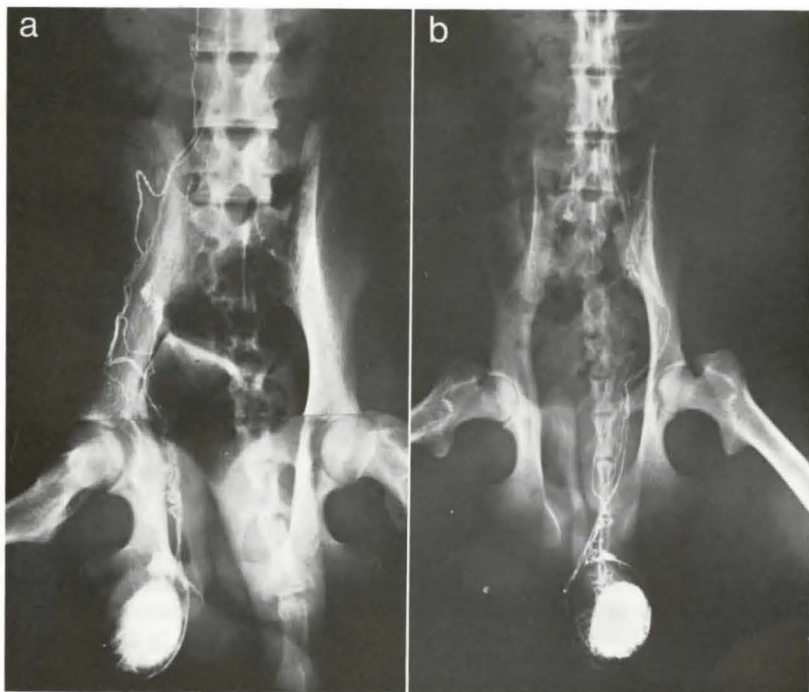


Fig. 6a—b

Fig. 6 Indirect lymphography in monkey. Opacification of sacral and lumbar lymph nodes with afferent lymphatic vessels and lumbar trunks after intraparenchymal (testicle) administration of iotasul (275 mg iodine/ml). a) Investigation in baboon, Injection volume: 4.0 ml; b) Investigation in rhesus monkey, Injection volume: 5.0 ml

5. Opacification of the lymphatic system can be carried out by simplified techniques of administration.
6. Visualization of the first lymph node group of organs permits improved tumor staging.

References

- 1 Barke, R., M. Elke: Kontrastmittel in: Lüning, M., Wiljasalo, M., Weissleder, H.: Lymphographie bei malignen Tumoren. Georg Thieme Verlag Stuttgart 1976, p. 33
- 2 Collette, J.M.: Lymphographie expérimentale et clinique. Description d'une technique d'opacification radiologique du système périphérique du group ganglionnaire ilio-pelvien. Acta Chir. Belg. 54 (1955) 607
- 3 Collette, J.M.: Envahissements ganglionnaires inguino-ilio-pelviens par lymphographie. Acta. Radiol. (Stockh.) 49 (1958) 154
- 4 Fischer, H.W.: Lymphangiography and lymphadenography with various contrast agents: Ann. N.Y. Acad. Sci. 78 (1959) 799
- 5 Fischer, H.W., G.R. Zimmermann: Roentgenographic visualization of lymph nodes and lymphatic channels. Amer. J. Roentgenol. 81 (1959) 517
- 6 Kaindl, F., E. Mannheimer, B. Thurnher: Lymphangiographie und Lymphadenographie am Menschen. Fortschr. Röntgenstr. 89 (1958) 1
- 7 Kinmonth, J.B., R.A.K. Harper, G.W. Taylor: Lymphangiography by radiological methods. J. Fac. Radiol. (Lond.) 6 (1955) 217
- 8 Leenhardt, P., R. Colin, M. Pélissier, H. Pourquoi: La lymphangiographie directe in vivo chez l'homme. J. Radiol. Electrol. 37 (1956) 947
- 9 Mälek, P., J. Kolc, L. Buřka, M. Semorádová: Grundlagen der experimentellen und klinischen Lymphographie. Zbl. Chir. 83 (1958) 1303
- 10 Tjernberg, B.: Lymphography as an aid to examination of lymph nodes. Acta. Soc. Med. Upsal. 61 (1956) 207
- 11 Tjernberg, B.: Lymphography. An animal study on the diagnosis of VX 2 carcinoma and inflammation. Acta. Radiol. Suppl. 214 (1962) 29

Dr.H.M. Siefert, Schering-Pharma-Forschung, Dept. Röntgenkontrastmittel, Postfach 650311, D-1000 Berlin 65