

## Lymphography in Toxoplasmosis — A Case Report

Hiroshi Miyaji, M.D., Eiji Nakagawa, M.D.\*, Hidekatsu Sugimoto, M.D. \*\*

Departments of Radiology\* and Internal Medicine\*\*, Kokura National Hospital, Kitakyushu, Japan

### Summary

Reported here are the lymphographic findings of a patient with toxoplasmosis, which, though non-specific, aided in evaluating the effects of treatment. Toxoplasmosis should be included the differential diagnosis of patients with unexplained lymphadenopathy.

**Key-Words:** Lymphography — Toxoplasmosis

Based on its developmental patterns, toxoplasmosis can be classified as disseminated, with involvement of the lung, liver, heart and skin; or lymphadenopathic, characterized by lymphadenopathy (1).

Only one report has documented the lymphographic findings in toxoplasmosis (2). The present report cites such findings in detail and underscores, the usefulness of lymphography in observing the effects of treatment of the toxoplasmosis.

### Case Report

In May, 1977 this 36-year-old male proprietor of a Chinese restaurant experienced swelling of his cervical and inguinal lymph nodes, accompanied by a low grade fever, and was admitted to the Kokura National Hospital.

At admission he was well-nourished and of medium build. On physical examination, his liver, spleen and kidneys were not palpable, but multiple freely movable lymph nodes ranging up to 3 cm in greatest dimension were palpable in both cervical and inguinal regions. There was no local heat, pain or tenderness.

His ESR was 35/75; WBC, 7,500 with a normal differential; RBC,  $5.13 \times 10^4$ ; Hb, 15.8 g/dl; CRP 5+; and his tuberculin skin test re-

action was 18 x 18 mm. Urine and stool studies were normal. Lymphography provided a tentative diagnosis of malignant lymphoma or lymphadenitis. The paraaortic, pelvic and inguinal lymph nodes were enlarged, and their internal architecture was granular, lace-like, strongly suggestive of malignant lymphoma (Fig. 1). The bone marrow contained  $139 \times 10^3$  nucleated cells, but no malignant cells. Infectious mononucleosis was also suspected, but the Paul Bunnell test titer was normal. Cervical lymph node biopsy revealed diffuse proliferation of lymphocytes and infiltration by chronic inflammatory cells, but no suggestion of malignancy. The toxoplasma test was therefore performed, the dye test titer was elevated (2048), and toxoplasmosis was diagnosed. Sulfisomezole 2.0 g and pyrimethamine 25 mg/daily were administered orally. Within 10 days, the superficial lymph nodes decreased from about 10 to 3 mm in size. On abdominal radiography, the paraaortic, pelvic and inguinal lymph nodes became markedly reduced in size, and toxoplasma titer decreased from 2048 to 512. There was no further reduction in size of the lymph nodes clinically or by abdominal radiography during the subsequent six weeks (Fig. 2), the toxoplasma titer remained at 512, and the patient was considered cured. His course following discharge has remained uneventful.

### Discussion

Toxoplasmosis is endemic in cattle, swine, sheep, rabbits, dogs, fowl, and other animals. As in the present case, the mode of transmission of the disease to man is incompletely understood. The patient reported here is the

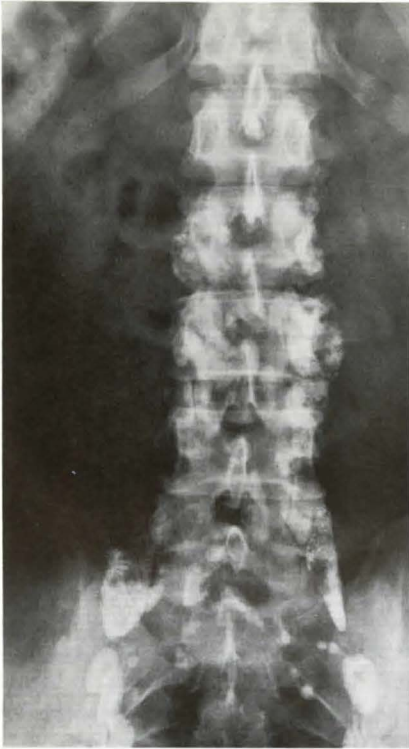


Fig. 1A

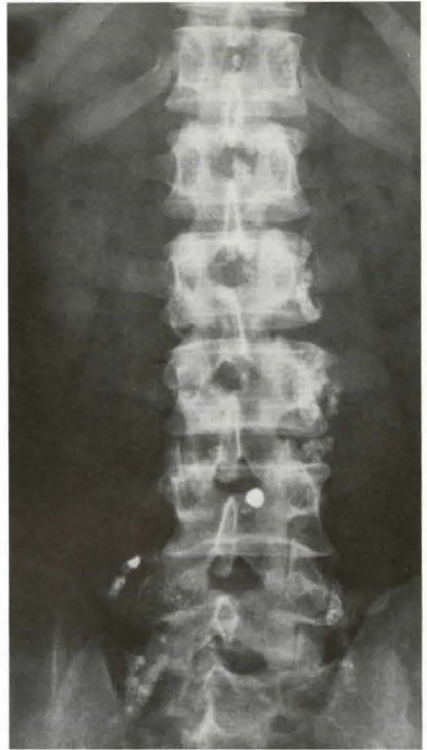

Fig. 2A

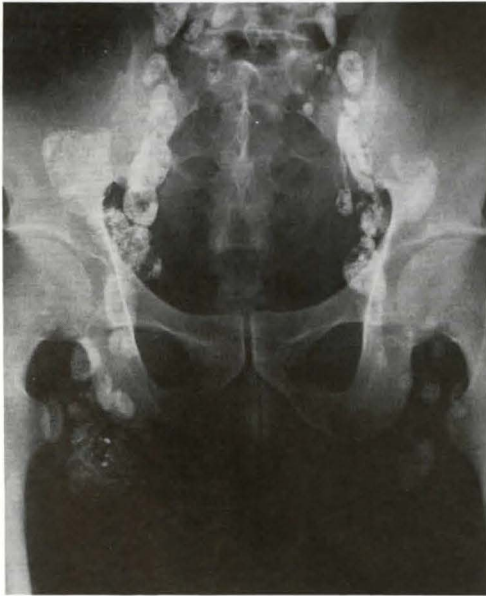

Fig. 1A, B Pelvic and paraaortic lymph nodes are enlarged and have granular and lace-like patterns

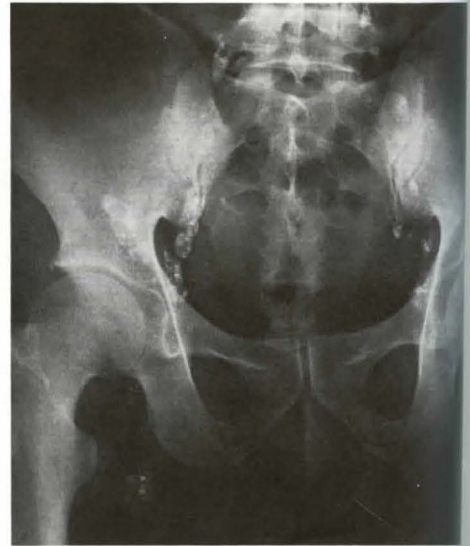

Fig. 2A, B The lymph nodes had decreased markedly in size during a 3-months period



proprietor of a Chinese restaurant, it is strongly suspected the source was contaminated pork.

Toxoplasmosis can be definitively diagnosed serologically, by smears, and by injecting the isolated parasites into mice (3). Characteristic histological features have been cited in lymphadenopathic toxoplasmosis (4, 5), however, toxoplasma cysts are rarely isolated from lymph nodes. It is therefore difficult to establish the diagnosis purely on the basis of lymph node biopsy.

In the present case, toxoplasmosis was diagnosed by the high titer of the dye test after a lymph node biopsy suggested a chronic immunological reaction.

In the first case of lymphadenopathic toxoplasmosis involving lymphography and follow-up observations (2), the lymphography revealed most of the femoral and paraaortic lymph nodes to be enlarged and to have coarse granular or lacy appearances. Other entities with such findings include Hodgkin's disease, malignant tumors, infectious and granulomatous diseases and immunologic disorders. Thus, the lymphographic findings are non-specific (6, 7). *Dorfman et al.* (4) reported that even though toxoplasmosis is a rare cause of lymph nodes enlargement, it should be considered in the differential diagnosis of such cases.

The lymph nodes of the present patient decreased in size nearly in proportion to the quantities of the oral medications he received

and he was considered cured after six weeks during which his lymph nodes remained unchanged. The lymphographic findings, particularly the changes in lymph node size, provide a relatively objective criterion for assessing the effect of therapy.

#### Acknowledgements

The authors thank Dr. Walter J. Russell and Dr. Keiichi Matsuura for editing this manuscript.

#### References

- 1 *Knight, V.*: Toxoplasmosis, Protozoan Infection. In: Textbook of Medicine, Edited by Beeson, P.B. and W. McDermott, pp. 736-739, 13th ed., W.B. Saunders Co., Phil. & London, 1971
- 2 *Harzmann, R., R. Chiari*: Differentialdiagnose der Lymphadenitis toxoplasmotica. *Med. Klin.* 69 (1974) 1614-1619 (Nr. 40)
- 3 *Feldman, H.A.*: Toxoplasmosis, Diseases caused by protozoa. In: Principles of Internal Medicine, Edited by Thorn G.W., R.O. Adams, E. Braunwald, K.J. Isselbacher and R. Petersdorf, pp. 1082-1084, 8th ed. International Student Edition. Mcgray-Hill Kogakusha Ltd. (1977)
- 4 *Dorfman, R.F., J.S. Remington*: Value of lymph-node biopsy in the diagnosis of acute acquired toxoplasmosis. *New Engl. J. Med.* 289 (1973) 878-881
- 5 *Uchiyama, K., H. Koizumi*: Lymphadenopathic toxoplasmosis. Report of 13 cases. *Jap. J. Clin. Path.* 13 (1965) 43-51
- 6 *Caires, G., J.H. Gafnon*: Lymphography in clinically suspected lymphoma. A retrospective analysis of 63 cases. *Radiology* 121 (1976) 631-634
- 7 *Parker, B.R., N. Blank, R.A. Castellino*: Lymphographic appearance of benign conditions simulating lymphoma. *Radiology* 111 (1974) 267-274

*Hiroshi Miyaji, M.D., Department of Radiology, Kyushu University Hospital, Fukuoka, Japan*