

## Lymphography for Fever of Unknown Origin-A Reappraisal

Y. Tsukamoto\*, Y. Numaguchi, H. Nakata\*, T. Kishikawa, J. Ikeda, K. Matsuura

From the Department of Radiology, Faculty of Medicine, Kyushu University, Fukuoka, Japan

\*Present address: Department of Radiology, School of Medicine, University of Occupational and Environmental Health, Kitakyushu, Japan

### Summary

Among the lymphograms of 25 F.U.O. patients whose diagnoses were unknown after several weeks of detailed examinations, abnormalities were noted in 4. Of the 4 abnormal cases, 2 were finally diagnosed by superficial lymph nodes biopsies as having malignant lymphomas. The other 2 had no final diagnoses; though biopsies of enlarged superficial lymph nodes were performed, they showed only reactive hyperplasia. No exploratory laparotomy was performed among the 25 cases. We conclude that lymphography is not absolutely indicated in the evaluation of F.U.O..

### Introduction

Fever of unknown origin (F.U.O.) was defined by *Petersdorf and Beeson* (1) as "an illness of more than three week's duration, with a fever higher than 101 °F (38.3 °C), and a diagnosis uncertain after one week of study in a hospital". A generally used broader definition refers to "fevers, including slight fever, of unknown cause" (2). When the cause of a fever of unknown origin induces changes in the abdominal lymph nodes in the manner of malignant lymphoma, knowledge of the conditions of these nodes is very important diagnostically. From June 1967 to October 1978, 1032 patients received bipedal lymphography in the Department of Radiology, Kyushu University Hospital. Twenty-five were examined because of F.U.O. and 4 of these had abnormal lymphograms. The significance of lymphography in F.U.O. is discussed.

### Material and Method

Twenty-five patients received bipedal lymphography using Kinmonth's method. Among

them were 10 males and 15 females, whose ages ranged from 18 to 78 years. Lymphographies were performed from 9 days to 5 months after admission and following various physical, bacteriological, serological and roentgenological examinations.

### Results

Among the 25 F.U.O. patients, 4 had abnormal abdominal lymphograms; the lymphograms of the remaining 21 were normal. Among the 4 patients with abnormalities, 2 were diagnosed as having malignant lymphomas by superficial lymph nodes biopsies:

*Case 1:* This 49 year-old male was first seen at Kyushu University Hospital in October 1974, complaining of generalized fatigue, weight-loss and a fever of 38 °C of 2 months duration. Post-admission temperatures of 37 °C were recorded on several occasions. Elevated ESR, CRP (+6) and increased  $\alpha_2$ -globulin and alkaline phosphatase were noted, but there was no superficial lymphadenopathy. There were no other abnormalities, and no definitive diagnosis was made. After 4 weeks of observation, the patient insisted on being discharged, but his temperature rose to 39 °C monthly thereafter, persisting for a week each time. In March 1975, abdominal lymphography revealed foamy internal structures and enlargement of the paraaortic lymph nodes (Fig. 1a). There was no superficial lymphadenopathy. The patient refused exploratory laparotomy. In March 1976, he was readmitted with hepatosplenomegaly. Repeat lymphography revealed slight decreases in sizes of the lymph nodes,

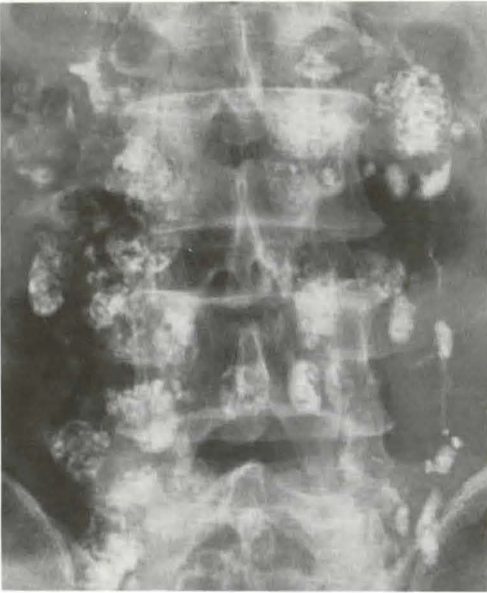


Fig. 1a Case 1, Lymphogram (Mar. 4, 1975), anteroposterior view. Enlarged and foamy internal structures are observed in bilateral abdominal paraaortic lymph nodes

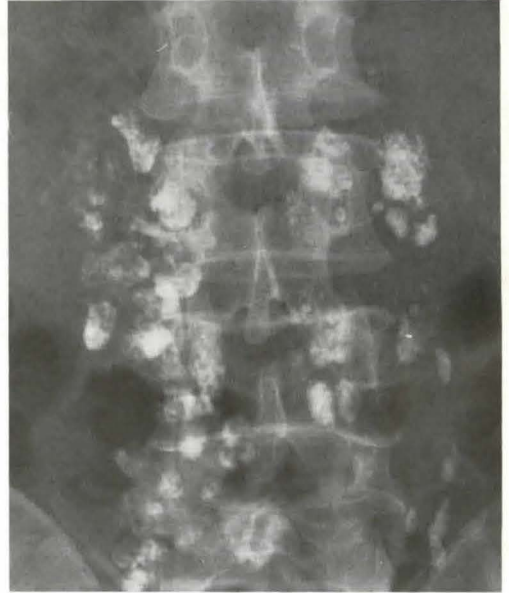


Fig. 1b Case 1, Second lymphogram (Mar 31, 1976), anteroposterior view. There is a slight decrease in size of lymph nodes, compared to previous study, but they are still enlarged with foamy internal structures

but their abnormal internal structures persisted (Fig. 1b). The cervical lymph nodes subsequently became enlarged, and Hodgkin's disease was diagnosed by cervical node biopsy.

*Case 2:* In May 1972, this 26 year-old male consulted his physician because of low back and hip pain, and a fever of 38 °C. Subsequently, he developed generalized lymphadenopathy. Inflammatory reactive hyperplasia was diagnosed by superficial lymph node biopsy in July 1972. In August 1972, he was referred to Kyushu University Hospital to determine the cause of his fever. Elevations of his ESR, CRP (+6), and increased LDH and  $\alpha_2$ -globulin, and hepatosplenomegaly were noted, but his hematology, biochemistry, bacteriological tests, chest radiography and an upper G.I. series were all normal. A fever of 38 °C persisted after his admission. Lymphography on the 14th postadmission day revealed enlarged paraaortic and iliac lymph nodes, with defective and foamy node structures (Fig. 2). Reticulum cell sarcoma was diagnosed

on repeat biopsy of the superficial lymph nodes.

In the other 2 patients who had abnormal lymphograms, definitive diagnosis were not obtained. Though biopsies of enlarged superficial lymph nodes were performed, they revealed only reactive hyperplasia. No exploratory laparotomy was performed in these 2 cases. In the 21 cases with no lymphographic abnormalities, the final diagnoses were 2 with chronic tonsillitis, 2 with dermatomyositis, and 1 each with renal cell carcinoma, rheumatic fever, corynebacterium infection, viral infection, aortitis, subacute bacterial endocarditis, and bile duct infection. No diagnoses were made in the other 10 cases.

#### Discussion

The superficial lymph nodes are not palpable in malignant lymphomas restricted to the retroperitoneum. The chief complaint is generally a fever, making its early detection difficult (3). Ascertaining the state of the retro-

peritoneal lymph nodes may provide clues to the diagnosis of the disease responsible for the fever. *Caires and Gagnon* (4) reported that the lymphography of 17 of 63 patients with possible malignant lymphoma were abnormal. Seeking the cause of a F.U.O. was the most frequent reason for their performing lymphography [25 cases (40%)]. The number among those 25 who had abnormal lymphograms was not mentioned. *Hayashi et al.* (5) performed lymphography on a patient with F.U.O. whose previous two lymph node biopsies were normal. On the basis of the abnormal findings indicated by lymphography, a third lymph node biopsy performed was abnormal and instrumental in establishing a diagnosis of reticulum cell sarcoma. There were also several similar case reports (3, 6, 7). In our first F.U.O. case, lymphography demonstrated abdominal lymph node abnormalities before obvious superficial lymphadenopathy occurred, but no biopsy by laparotomy was performed, and the opportunity for an early diagnosis was lost. The reason for the decreasing sizes of lymph nodes in this case is unknown. *Scanlon et al.* (8) described a similar experience in which cyclic variations in lymph node size occurred, related to a *Pel-Ebstein* fever in a patient with Hodgkin's disease. Our second case had reactive hyperplasia in enlarged superficial lymph nodes at the first biopsy. However, malignancy and reactive hyperplasia occur simultaneously (9). Therefore, abnormal lymphography is an indication for repeat lymph node biopsy. *Petersdorf* (10) and others (11, 12, 13) have reported exploratory laparotomy to be valuable in abdominal abnormalities possibly causing F.U.O.'s. However, in lymphography for 44 suspected malignant lymphomas and F.U.O.'s, *Dunnick and Castellino* (14) detected 9 abnormalities among 23 F.U.O. patients. Three of these 9 patients had laparotomy and a diagnosis of reactive hyperplasia was thus established. The lymphographic findings were reportedly practically nonspecific. They further concluded contrary to other investigators, that lymphography for evaluating F.U.O. patients was of no value as regards the eventual diagnosis. Their policy is, if the patient is scheduled for exploratory laparotomy, they may perform lymphography to guide the

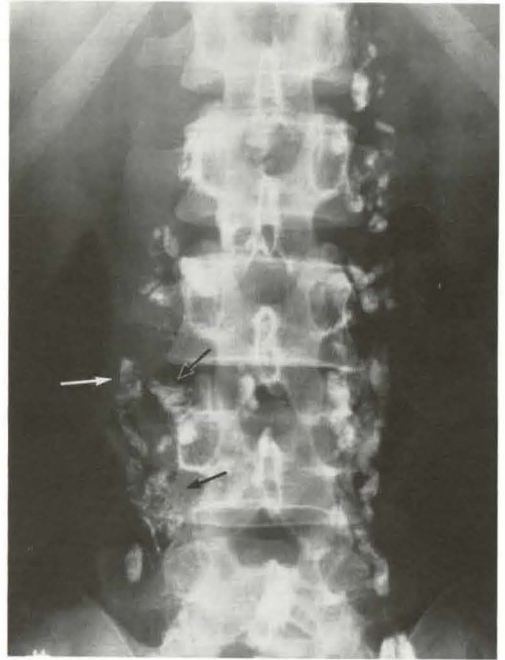

Fig. 2 Case 2, Lymphogram, anteroposterio view  
Paraaortic lymph nodes are slightly enlarged, with foamy internal structures and filling defects (arrows)

surgeon in obtaining the most abnormal-appearing lymph nodes for biopsy. In conclusion, among our 25 patients who received lymphography in evaluation of F.U.O., lymphography added nothing in 21 and very little in 4 regarding the patients' management and final diagnoses. Therefore, we agree with *Dunnick and Castellino* (14), that lymphography is not absolutely indicated in the evaluation of F.U.O..

#### Acknowledgement

We thank Dr. *Walter J. Russell* for criticisms and editorial suggestions.

#### References

- 1 *Petersdorf, R.G., P.B. Beeson*: Fever of unexplained origin: Report on 100 cases. *Medicine* 40 (1961) 1-30
- 2 *Kashiwagi, S., M. Kaji*: How to diagnose fever of unknown origin. *Jap. J. Clin. Exp. Med.* 50 (1973) 2819-2826
- 3 *Molavi, A., L. Weinstein*: Persistent perplexing pyrexia: Some comments on etiology and diagnosis. *Med. Clin. N. Amer.* 54 (1970) 379-396

- 4 *Caires, G., J.H. Gagnon*: Lymphography in clinically suspected lymphoma: A retrospective analysis of 63 cases. *Radiology* 121 (1976) 631–634
- 5 *Hayashi, S., J. Nishikawa, H. Oka, T. Araki, A. Tasaka*: Diagnosis of malignant lymphoma by lymphography with particular emphasis on differential diagnosis of diseases with images simulating malignant lymphoma. *Jap. J. Clin. Med.* 32 (1974) 1203–1212
- 6 *Constantinides, S., C.J. McPeak*: Lymphangiography and its applications. *Surgery* 57 (1965) 515–521
- 7 *Goldstein, E., P.D. Hoerich*: Lymphangiography in diagnosis of fever of unknown origin. *Calf. Med.* 119 (1973) 59–61
- 8 *Scanlon, G.T., R.A. Castellino, R. Rudders*: Lymphographic demonstration of cyclic changes in lymph node size during Pel-Epstein fever. *Cancer* 36 (1975) 2026–2028
- 9 *Parker, B.R., N. Blank, R.A. Castellino*: Lymphographic appearance of benign conditions simulating lymphoma. *Radiology* 111 (1974) 267–274
- 10 *Petersdorf, R.G.*: Fever of unknown origin. *Ann. Int. Med.* 70 (1969) 864–866
- 11 *Barr, J., P. Magnusson, S. Wallensten*: Diagnostic laparotomy in cases of obscure fever. *Acta Chir. Scand.* 138 (1972) 153–158
- 12 *Geraci, J.E., L.A. Weed, D.R. Nichols*: Fever of obscure origin – the value of abdominal exploration in diagnosis: Report of seventy cases. *J.A.M.A.* 169 (1959) 1306–1315
- 13 *Deal, W.B.*: Fever of unknown origin: Analysis of 34 patients. *Postgraduate Medicine* 50 (1971) 182–188
- 14 *Dunnick, N.R., R.A. Castellino*: Lymphography in patients with suspected malignancy or fever of unexplained origin. *Radiology* 125 (1977) 107–111

*Yuji Numaguchi, Department of Radiology, Faculty of Medicine, Kyushu University, 3-1-1 Maidashi, Higashi-ku, Fukuoka, Japan 812*