

The Influence of Multidirectional Vibrations on Wound Healing and on Regeneration of Blood- and Lymphvessels

A. Leduc, P. Lievens, J. Dewald

Laboratory of revalidation Vrije Universiteit Brussel Faculteit Geneeskunde en Farmacie Laarbooklaan, 103, Brussel, Belgium

Summary

Experiments show that the multidirectional vibration therapy is not an aggressive technique: when applied to the newly-formed lymph-vessels in the scar, we observed that they were not damaged by this technique whereas we had found in earlier studies that a gentle effleurage destructed the newly formed lymph network in the scar.

When using this treatment, little or no adhesion of the scar to the underlying tissues is observed.

There is a significant decrease of the local edema when compared to a standard group of wound-healing without multidirectional vibrations.

There is also a significant decrease of general and local congestion and no increase in the permeability of veins and lymphvessels is present.

The application of the local multidirectional vibration therapy accelerates the regeneration of the severed vein and lymphvessel.

Introduction

Wound healing is a very complex process. *Lindsay et al.* (6) and *Gillman* (4) conclude that the epidermis is the first tissue that bridges over the scar lumen beneath the clot. The regeneration of the epidermis is followed by the regeneration of the connective tissues and blood capillaries.

However, the reconstruction of the lymphatic vessels during this process is a rather neglected factor, although the role of the lymphatic system is well defined by *Clodius* (2). Better comprehension of the phenomenon of lymphatic reconstruction was due to a large extent to the studies of *Reichert* (7), *Clark* and *Clark* (4) and more recently to *Danese* (3) and *Satjukowa* (8).

In a previous paper (5), we also studied regeneration of blood- and lymphvessels during the process of wound healing after surgical incisions on 500 mice. By means of transillumination microscopy *in vivo*, we found that the recovery of the lymphatic system is an important factor in wound healing. Compared to the venous system, we find that the severed lymphatic vessel regenerates in the form of a disordered network in the scar region (Fig. 1). This network is even seen up to six months after the incision. To understand the influence of vibration therapy on the process of wound healing, we studied a second experimental group of incisions which were submitted three times a day to a 20' local multidirectional vibration therapy (Niagara therapy*).

Procedure

Under ether inhalation anesthesia, a transabdominal incision was performed on 500 mice. The incision cut the main vein, artery and lymphatic vessel of the ventro-lateral aspect of the skin. The two edges of the wound were sutured with a 5-0 silk suture.

At different intervals of 1 hour to 6 months, the mice were anaesthetized by means of a subcutaneous injection of urethane in order to examine the internal aspect of the scar. We proceeded to make a longitudinal incision along the Linea Alba and carefully dissected the abdominal skin.

*Registered Name

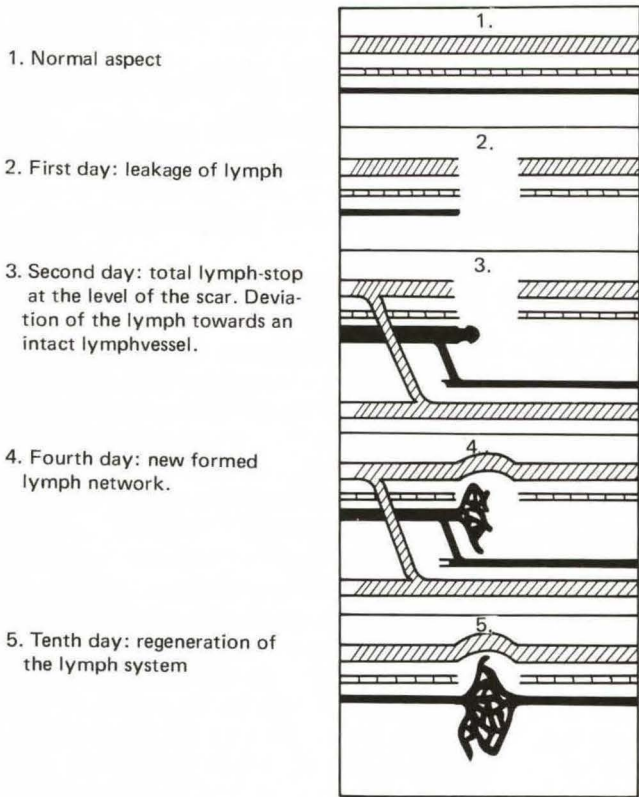


Fig. 1

The wound was then examined by means of transillumination microscopy *in vivo*.

In our second experimental group we submitted the mice three times a day to a 20 min multidirectional vibration therapy.

Results

1. Woundhealing without vibration (Standard group)

We examined about 50 different parameters on each mouse for each interval. We thus obtained a good picture of the evolution of each parameter from 1 hour to six months post-incisional.

The main conclusions of this study were as follows:

1) The cut artery had not recovered its original form. An important constriction over a large part of the cut artery remains directly after the incision. The distance between the two

cut ends probably became too wide and this resulted in resumption of arterial flow by means of collateral channels entering the wound in different directions.

2) However, in all our experiments, we found that the vein has recovered its original pattern after a period of 14 days.

After this time period, negative signs like permeability of the veins in the scar region are disappearing.

Regeneration first appears in the form of many small capillaries bridging over the wound after 5 days.

When the capillaries become functional, the abnormal dilatation of the veno-venous anastomosis is decreasing.

After fourteen days, one vessel in most cases remains functional: this is the elective way of the venous blood-circulation. At that point, the other vessels are no longer functional.

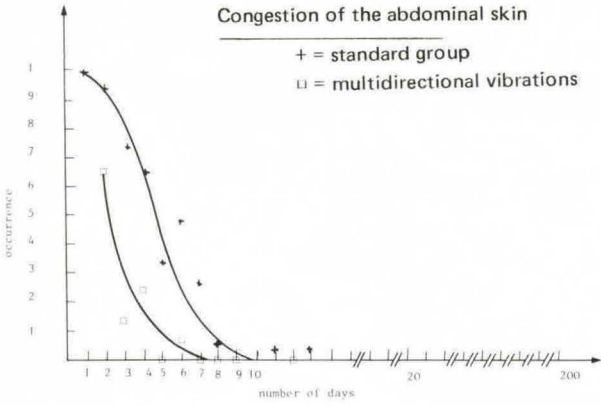


Fig. 2

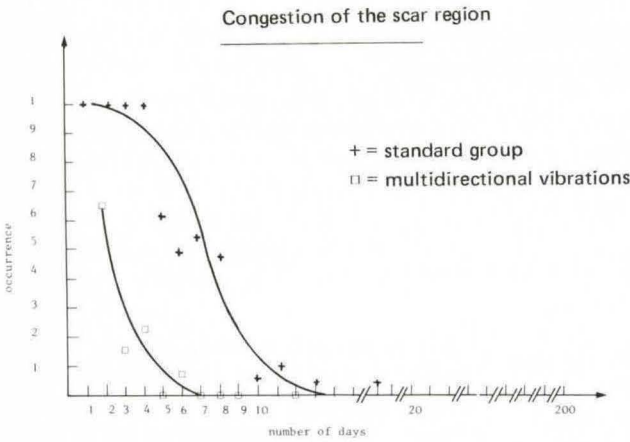


Fig. 3

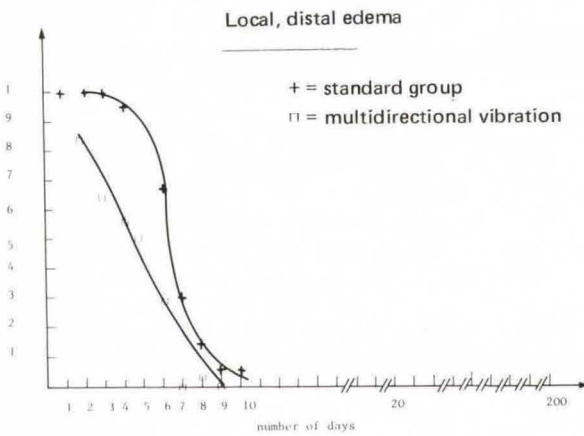


Fig. 4

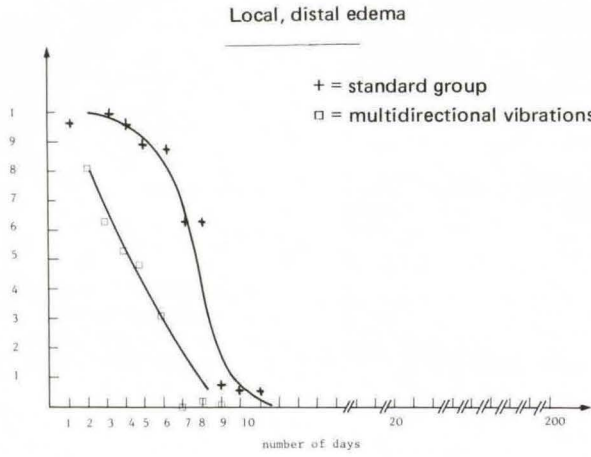


Fig. 5

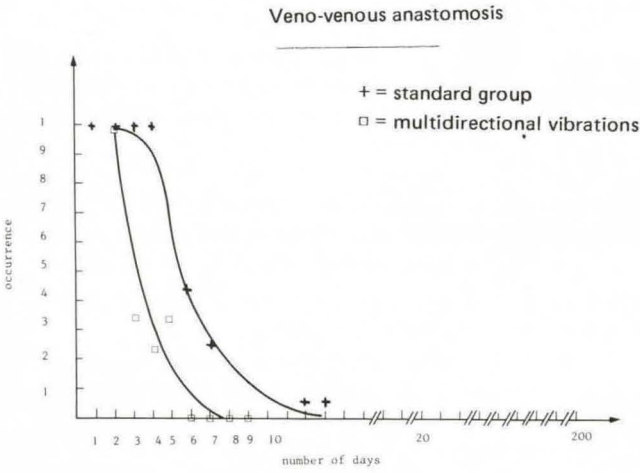


Fig. 6

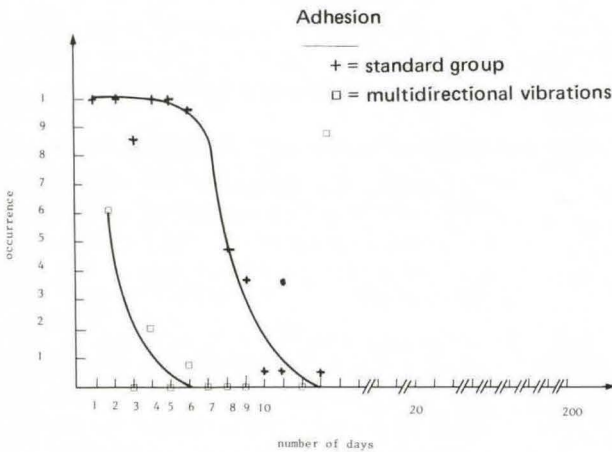


Fig. 7

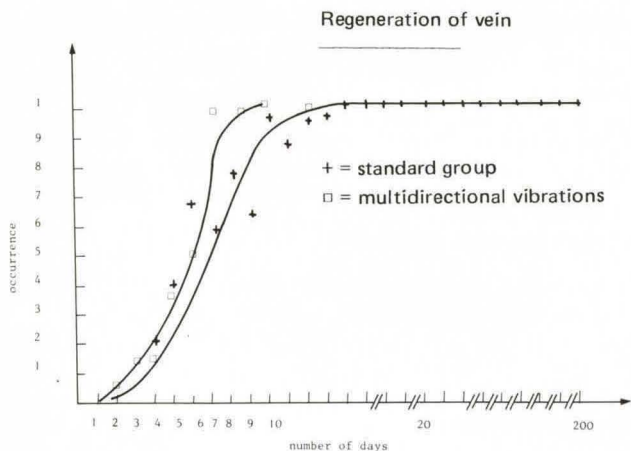


Fig. 8

The flow is inversed in the distal end of the cut vein: it goes from the wound to the nearest veno-venous anastomosis.

When the vein has regenerated, the flow becomes normal again. During the healing process, we also noticed that the blood flow was delayed in the region of the scar. This phenomenon also disappears when the normal out-flow channel is reestablished. During the healing process, dilatation of the veins was also noted.

3) The existence of lympho-venous shunts
After the fourth day, we observed junctions between the newlyformed veins and lymphvessels at the level of the scar.

These lympho-venous junctions are not seen under normal conditions and after the seventh day, they were no longer observed.

4) The lymphvessel is restored in the form of a network.

The regeneration of the cut lymphvessel appears in a very specific form which is not seen in cases of regeneration of the veins. A network of small lymphvessels is observed in the scar after the third day and is abnormally permeable so that the injected dye easily leaves the vessels a few minutes after injection. This increase of permeability is even seen six months later in half of the cases. Like in venous circulation reconstruction, we noted that during

lymph regeneration the lymph was evacuated by means of lympho-lymphatic anastomoses until and even after restoration of the original system.

5) Swelling of the extremities did not appear and general edema of the abdominal skin quickly disappeared after the incision.

6) Local edema is a very important factor during woundhealing.

The local edema can be divided into distal and proximal local edema in regards to the edges of the wound. In our experiments we noticed that the distal local infiltration was more extensive than the proximal swelling. The distal edema also remained longer than the proximal edema.

We found a high correlation between this local edema and the evolution of the regeneration process in the vein and lymphvessels.

2. Woundhealing with the Niagara therapy

To examine the influence of multidirectional vibration therapy on wound healing we studied a second experimental group of mice, which were subjected to the same surgical procedure (N = 120).

At the same time-intervals as for our standard group, we examined the internal as well as the external appearance of the wound. From our initial 50 parameters we selected those who were most important to our study:

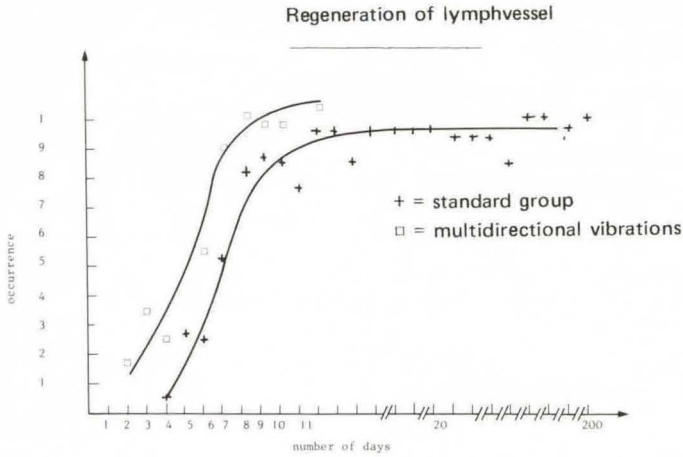


Fig. 9

- general congestion of the skin (Fig. 2)
- local congestion of the scar (Fig. 3)
- local, proximal edema of the scar (Fig. 4),
- local, distal edema of the scar (Fig. 5),
- the existence of veno-venous anastomosis from the scar to intact veins (Fig. 6)
- adhesion of the scar to the underlying tissue (Fig. 7)
- regeneration of vein (Fig. 8)
- regeneration of lymphvessel (Fig. 9)

The evolution of these parameters were compared with the evolution of the same parameters of the standard group (incisions without vibration therapy).

The data were computerized to obtain a frequency analysis. The percentual frequencies are represented by means of a curve.

These new curves were then compared to the curves of our standard group. To detect eventual significant differences between both curves, we used the *Kolmogorov-Smirnov test*: This test can prove whether two cumulative, independent curves are from the same or different populations. When the deviation between the two curves is large enough, we can withdraw the zero-hypothesis, which says that there is no significant difference.

When we have two cumulative frequency curves with the same intervals, we can calculate the deviations for each interval. For a well-known interval (X) the observed func-

tion of $(y) = S_{n_1}(X)$ for one curve and for the other $(y') = S_{n_2}(X)$. We determine the maximal deviation by making the difference.

$$D = \max |S_{n_1}(X) - S_{n_2}(X)|$$

When n_1 and n_2 are bigger or equal to 40 we have a large sample. For large samples like these the theoretical values can be found in tables.

It is also necessary that n_1 is equal to n_2 so we calculated the maximal deviation between the two curves and compared it with the theoretical value of the table.

For instance: for a significant area of 0.01 the theoretical value is 0.23. This means that when the observed maximal difference is greater or equal to 0.23, we can conclude that with a significant label of 0.01 the curves are from different populations.

For all these curves we obtained a significant difference between the standard group and the group of animals which were subjected to a treatment with multidirectional vibration therapy.

References

- 1 Clark, E.R., E.L. Clark: Observation on the new growth of lymphatic vessels as seen in transparent chambers introduced into a rabbits ear. *Amer. J. Anat.* 51 (1932) 49
- 2 Clodius, L.: *Lymphedema*, Georg Thieme Verlag, Stuttgart 1977
- 3 Danese, C.A.: Regeneration of lymphatic vessels.

- Lymph and the lymphatic system. Mayerson III, 53 (1968)
- 4 *Gillman, T.*: Healing of cutaneous wounds. The Glaxo Volume, 31 (1968) 5
- 5 *Lievens, P.*: Lymphatic regeneration during wound healing, Lymphology Proceedings of the VIth International Congress. Prague. Eds. P. Malek et al., Georg Thieme Verlag, Stuttgart pp. 194–197 (1977)
- 6 *Lindsay, W.K., J.R. Birch*: Thin skin healing. Can. J. Surg. 7 (1964) 297
- 7 *Reichert, F.L.*: The regeneration of the lymphatics. Arch. Surg. 13 (1926) 871
- 8 *Satjukowa, G.S., L.I. Woikowa*: Besonderheiten der Morphogenese des Lymphsystems unter experimentellen und pathologischen Bedingungen. Verh. Anat. Ges. (Jena), 69 (1975) 63

Prof. Dr. Pierre Lievens, Prof. Dr. Albert Leduc, Jules Dewald, Laboratory of revalidation Vrije Universiteit Brussel Faculteit Geneeskunde en Farmacie, Laarbeeklaan, 103 1090 Brussel (Belgium)