

## Spontaneous Contractility in the Human Lymph Vessels

S. Armenio, F. Cetta, G. Tanzini, C. Guercia\*

Istituto di Semeiotica Chirurgica dell'Università di Siena (Direttore: Prof. Salvatore Armenio)

\*Istituto di Radiologia dell'Università di Siena (Direttore: Prof. Carlo Stuart)

### Summary

During the diagnostic lymphangiography of the lower limbs, the motility of the lymph vessels was investigated in 79 consecutive patients, by means of a particularly performed serial radiography, aided by photographic magnification of films.

Because of technical difficulties, a rather high incidence of imperfect examinations occurred.

In 26 out of 35 (74.3%) technically satisfactory observations obtained from patients with no obstacle to lymph flow, evident morphological modifications were demonstrated, surely caused by intrinsic spontaneous contractility. Only in few cases a contractile activity, somehow resembling a true peristaltic wave could be demonstrated; usually the lymphatic "pulse" appeared irregular and greatly varying and no specific rhythm was detected.

Our findings suggest that: intrinsic contractility may be an important determinant of lymph flow; the pattern of contractility is strongly influenced by the anatomical feature of the lymphatic chain, whose lymphangions (interval segments), appear continuously varying in size and shape.

Factors determining the propulsion of lymph along lymphatic vessels are not completely known. According to the classic theory, the massaging and squeezing effects of skeletal muscles on lymphatics have been considered previously to play, at least in the limbs, the most important role in propelling lymph along lymphatic vessels.

Such theory is supported by the evidence that, in animals used for experiments, there is very little lymph flow from cannulated lymph vessels of the limbs, unless these parts are moved passively and massaged.

In recent years, *Mislin* (1) demonstrated active contractility in smooth muscles of lymphatic walls in the isolated mesenteric lymph

vessels of the guinea pig: he called "lymphangions" (2) the segments of the lymphatic chain between two unidirectional valves. *Hall et al.* (3) confirmed those findings, showing intrinsic rhythmic propulsion of lymphatics in the free unanaesthetized sheep.


The absence of rhythmic contractility in previous experiments was suggested by *Hall* to be due to the effects of anaesthesia or surgical trauma, which inhibited the contractile activity in the wall of the lymph vessels. The purpose of this paper is to present a new approach in investigating the motility of lymph vessels in man, avoiding in any case the influence of anaesthesia or surgical trauma.

### Material and Methods

Our method of investigation of the active contraction of peripheral lymphatics is based on a particularly performed radiographic study, during diagnostic lymphangiography, aided by photographic magnification of films.

79 consecutive patients (45 males and 34 females, aged 18-76), who gave their informed consent, have been studied. Indications for lymphangiography of the lower limbs, performed according to *Kinmonth's* technique (4), have been: 1) malignancies without lower limb edema in 57 patients and 2) lower limb edema, (lymphedema; postphlebotic syndrome, venous and lymphatic obstruction from cancer metastasis) in 22 patients.

Following the injection of the contrast medium in a collecting vessel of the dorsum of the foot, serial radiography of the superficial lymph vessels was performed, distantly to the injection



**Fig. 1** Metal frame used to mark the site selected for serial radiography. The dimensions of the marker enable us to calculate the actual enlargement, following photographic magnification of the films

site, in the anteromedial aspect of the upper third of the leg. The selected site was surrounded by a metal frame (diameter 5 cm), to control exactly the magnification ratio (Fig. 1). The marker was fixed to the skin with a small strip of adhesive tape.

In 74 patients Lipiodol ultrafluid\* was used, while in the other 5 patients a water soluble medium (Uromiro 420\*\*) was tried: the same results were obtained, though the poor quality of films in the last case greatly disturbed proper photographic magnification.

After preliminary observations in the first 5 patients, radiograms were taken every 8–15 sec., starting from 1.5 to 15 min. following the injection of the contrast medium. To avoid side-effects of the X-rays, not more than 15–20 radiograms were obtained from each patient.

3M films (no screen), placed directly on the skin of the patient, were used. The factors were 100 mA, 1.2 sec. at 60–65 KV and 1.20 m. distance.

In order to demonstrate eventual morphological modifications that might occur in rapid

radiograms, series were obtained from 4 patients every 1–3 sec, by means of a rapid-film changer, capable of making films at a rate of one per second.

The study was performed in all patients with the subject lying in the supine position, avoiding any movements.

Dynamic tests, performed in 9 patients, gave inconclusive results, because subjects were never able to assume the same position as before the beginning of the movement.

### Results

In 56 patients lymphangiography was performed in the supine position, according to usual technique and injecting Lipiodol Ultrafluid as contrast medium.

Technically adequate observations were achieved in 35 patients (62.5%), while incomplete or imperfect examinations occurred in 21 patients (36.5%).

Technically inadequate studies were due to: 1) severe edema of the limbs, which greatly disturbed cannulation or appropriate visualization of the lymphatics in 14 patients; 2) change of patient's position during serial radiography; 3) poor quality of films.

In 26 out of 35 patients with technically adequate studies (74.3%) evident morphological modifications were observed demonstrating intrinsic spontaneous contractility (Fig. 2–7).

Analyzing the photographic enlargements (5–7 diameters) obtained from the serial radiograms in these patients, some interesting observations of the pattern of contractility of the lymph vessels could be made.

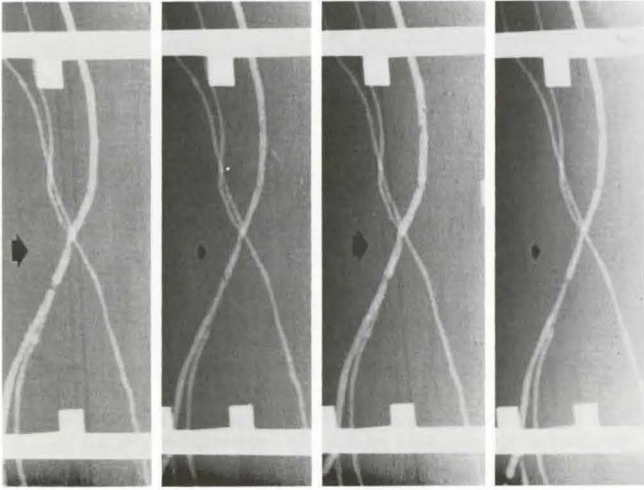
Even if considerable individual variations occurred, some similar aspects could be detected.

Usually not a single lymphangion, but 2–3–4 lymphangion groups could be observed contracting simultaneously (Fig. 2–5). The contracting lymphangion grouping was not fixed, because of possible asynchronous contraction of single lymphangions.

Systole (the contraction phase of the lymphatic cycle) was never equal to diastole, which

\*Furnished by Laboratoires André Guerbert, Aulnai-sous Bois-France

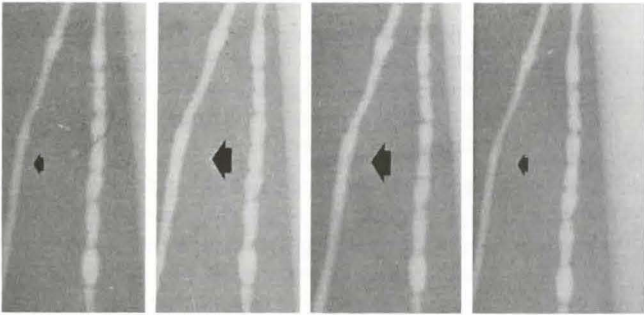
\*\*Furnished by Bracco, Industria S.P.A. Milano, Italy.



**Fig. 2** C.G., male, aged 61; cancer of the lower rectum; left lower limb lymphangiography; no obstruction to lymph flow.

4 serial radiograms, taken every 10 sec., 10 min. after the injection of Lipiodol Ultrafluid.

2 Lymphangions (Lymphangion = segment of the lymphatic chain between 2 unidirectional valves), dilated (1,3) and contracted alternatively (2, 4) are demonstrated



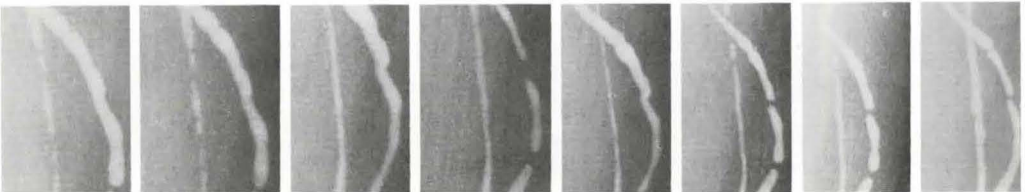
**Fig. 3** M.A., male, aged 45; Hodgkin's disease; left lower limb lymphangiography; no obstacle to the lymph flow in the lower limbs.

4 serial radiograms, taken every 10 sec., 10 min. after the injection of Lipiodol Ultrafluid. Again lymphangions dilated (2, 3) and contracted alternatively (1, 4) are shown. In this patient a simultaneous visualization of the superficial and deep lymphatic system was obtained

was always longer. The pulsation frequency was extremely variable: spontaneous contractions could be observed also in the short 4 radiograms series, occurring every 20 sec. (Fig. 2-3). Usually, however, in 19 patients, contractions occurred every 30-120 sec. Only in few cases a contractile activity, somehow resembling a true peristaltic wave, moving centripetally, could be demonstrated (Fig.

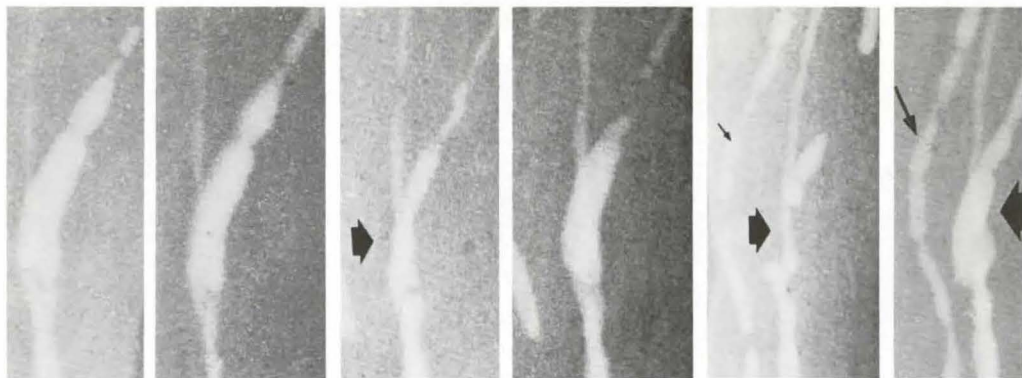6-7). Usually the lymphatic "pulse" appeared irregular and greatly varying: in particular, no specific rhythm could be detected by our method.

The lymphatic chain appeared greatly and continuously varying in size and shape. Even after keeping under observation some segments of the lymphatic chain for relative long intervals



**Fig. 4** G.A., male, aged 63; cervical mass (lymphonal metastasis from squamous cell carcinoma). no lymphatic pathology in the lower limbs.

8 serial radiograms, taken every 12 sec., 2 min. after the injection of the contrast medium. Continuously varying contractile activity in a group of lymphangions is demonstrated. Parallel running vessels seem to alternate in activity



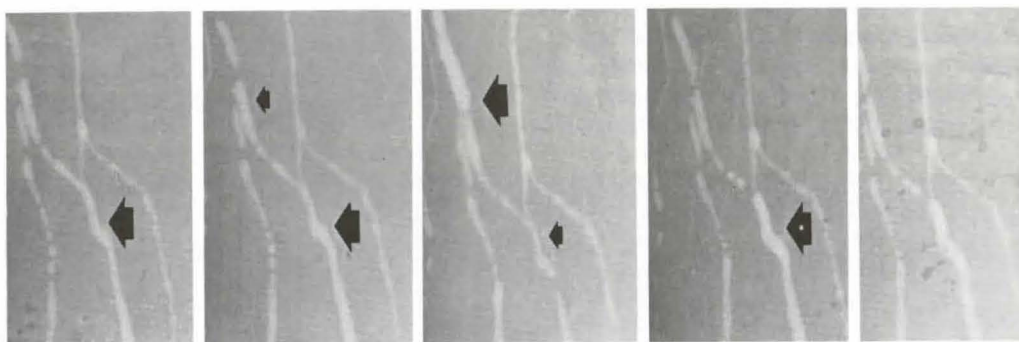
**Fig. 5** F.G., male, aged 45: mediastinal mass (lymphoma?): no lymphatic pathology in the lower limbs. 6 serial radiograms, taken every 15 sec., 5 min after the injection of the oily contrast medium. A large lymphangion is shown initially dilated, successively empty, and fastly again refilled with the contrast medium. In this case parallel running vessels seem to contract together

some lymphangion groups always appeared dilated while others always appeared contracted (Fig. 7).


In 9 out of 35 patients (25.7%) with technically adequate examinations, spontaneous contractility could not be recorded. Possible reasons for the failure in observing spontaneous contractility were: too short series (less than 2 min. observation) in 5 cases, and too long intervals between radiograms (more than 20 sec.) in 2 cases. In the last 2 cases no morphological modification could be detected after 180 sec. observation, despite of the per-

fect visualization of the lymphatic and the proper timing of serial radiograms. Probably, for unknown causes, in these 2 cases, lymphatics were quiescent.

Incidentally, by means of serial radiograms, the velocity of lymph flow could be determined, observing in consecutive radiograms the centripetal movement of a single air bubble in the lymph vessel. In the case reported in Fig. 8 the velocity of lymph flow, so measured, was 0.18 mm/sec.



**Fig. 6** A.G., male, aged 40: seminoma of the testis: no obstruction to lymph flow in the lower limbs. 5 serial radiograms, taken every 15 sec., 15 min. after the injection of the contrast medium. A contractile activity, somehow resembling a peristaltic wave, is clearly shown; no specific rhythm can be detected



**Fig. 7** R.P., female, aged 62: melanoma of the right foot. Controlateral limb lymphangiography.

15 serial radiograms, taken every 12 sec. 5 min. after the injection of the contrast medium. In this long series, a contractile activity, resembling a peristaltic wave, can be demonstrated (Radiograms no. 12, 13, 14, 15). The lymphatic chain appears as a sequence of lymphangions, which are greatly and continuously varying in size and shape.

Also during a long interval (12 sec x 15 = 180 sec.) some segments of the lymphatic chain always appear larger and dilated than others, while other lymphangions always appear contracted

### Discussion

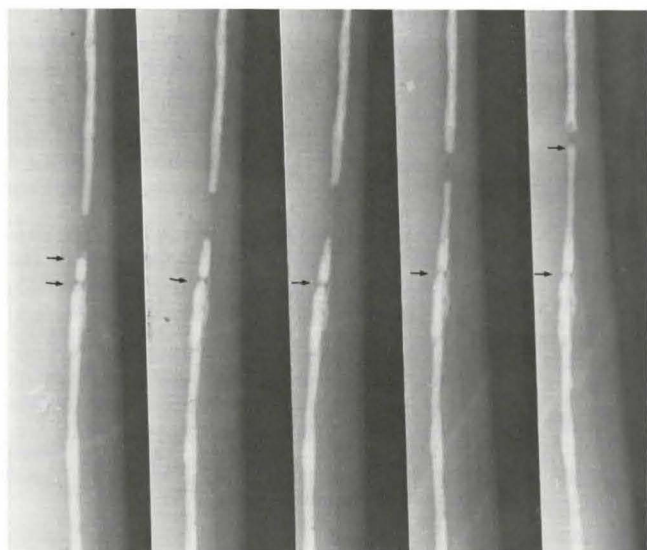
Intrinsic propulsive movements of the lymph vessels have recently been observed in animals: guinea pigs (1, 2), sheep (3), wings of bat (5), rats (6), cattle (7), dogs (8).

Data suggesting intrinsic contractile activity in man are extremely rare. Only few occasional observations are reported in sites other than thoracic duct.

In 1956 *Kinmonth* and *Taylor* (9) demonstrated in a film the contractility of mesenteric megalymphatics during laparotomy. In 1963 *Szegvari et al.* (10) published two photographs of a contracted and relaxed lymphatic vessel of the dorsum of the foot in a patient undergoing diagnostic lymphangiography.

Our data (11–13), obtained from functionally normal legs, with no obstruction to lymph flow, are in accordance with results reported by *Olszewski* and *Engeset*, (14) who, in the same period (1979), demonstrated in 5 healthy volunteers rhythmic pulse-pressure waves in peripheral lymphatics and observed spontaneous contractions with the operating microscope at time of lymphatic cannulation. They were not able to record actual contractions: therefore, only indirect evidence of intrinsic lymphatic contractility was given.

To our knowledge, the present study gives, for the first time in a series of patients, a direct demonstration of spontaneous contractility in the lymphatics of lower limbs in



**Fig. 8** F.F., male, aged 41: Hodgkin's disease.

5 serial radiograms, taken every 10 sec., 5 min. after the injection of the contrast medium. Proximal propulsion of an air bubble in a lymph collecting channel. The velocity of lymph flow can be determined, by measuring space and time. In this case  $V = 0.18$  mm/sec

man during rest. In fact, all the patients with demonstrated contractility were studied while lying in the supine position, avoiding any movements.

In such conditions, the massaging and squeezing effects of skeletal muscular activity could not be invoked; morphological modifications could be determined only by intrinsic contractility.

Using the present method, no uniform pattern of contractility could be detected in lymphatics, because considerable variation occurred in the frequency and amplitude of contractions, not only from individual to individual but also from segment to segment of the lymphatic chain in the same individual. Differences in the pattern of contractility could also be detected in lymphangions of the same group, during different time periods.

Only in few cases a contractile activity, strongly suggesting a true peristaltic wave, could be observed (Fig. 5, 6, 7). Usually the lymphatic "pulse" appeared irregular and greatly varying.

In particular, in the lymphatic chain a single lymphangion never appeared contracted while the preceding and the following ones were dilated, as suggested by *Mislin*, who in the guinea pig stated that adjacent lymphangions, as a rule, alternate in activity (2).

In our opinion, the anatomical feature of the lymphatic chain, the lymphangions of which are greatly and continuously varying in size, may play a mayor role in determining the motility pattern.

In conclusion, the present method of investigation is undoubtedly able to demonstrate the motility of the lymph vessels in man. Intrinsic contractility may be an important determinant of the propulsion of lymph, in particular at rest, with the subject lying in the supine position, when the squeezing effect of muscular contraction is absent. In addition it seems useful for further investigations, concerning the physiological and pathophysiological aspects (i.e. velocity of lymph flow), connected with lymph vessels motility; but perhaps other devices or new methods

are necessary for further study of the pattern of contractility in lymphatics.

#### Acknowledgements

It is a pleasure to acknowledge the professional help provided by Mr. *F. Burrioni* and Mr. *N. Pasqui* for serial radiograms and by Mr. *E. Pozzebon* for photographic magnification.

#### References

- 1 *Mislin, H.*: Experimenteller Nachweis der autochthonen Automatie der Lymphgefäße. *Experientia* 17 (1961) 29
- 2 *Mislin, H.*: Die kontraktilen Eigenschaften der Lymphgefäße. *Angiologica* 8 (1971) 207
- 3 *Hall, J.G., B. Morris, G.J. Wooley*: Intrinsic rhythmic propulsion of lymphatics in the unanaesthetized sheeps. *J. Physiol. (Lond.)* 180 (1965) 336
- 4 *Kinmonth, J.B.*: The lymphatics. Diseases, lymphography and surgery. *Arnold Ltd., London* 1972
- 5 *Nicoll, P.A., R.D. Hogan*: Pressure associated with lymphatic capillary contractility. *Microvasc. Res.* 15 (1978) 257
- 6 *Hargens, A.R., B.W. Zweifach*: Contractile stimuli in collecting lymph vessels. *Am. J. Physiol.* 233 (1977) 57
- 7 *Kirkpatrick, C.T., N.G. McHale*: Electrical and mechanical activity of isolated lymphatic vessels. *J. Physiol.* 272 (1977) 330
- 8 *Staub, N.C., N.P. Reddy*: Intrinsic propulsive activity of thoracic duct perfused in anaesthetized dogs. *Abstr. VII. Intr. Congr. Lymphology. Florence* (1979) 57
- 9 *Kinmonths, J.B., G.W. Taylor*: Spontaneous movements of lymph vessel. *J. Physiol. (Lond.)* 133 (1956) 30
- 10 *Szegvari, M., A. Lakos, F. Szontagh, M. Földi*: Spontaneous contractility of lymph vessels in man (Letter to Editor) *Lancet* 1963/I, 1939
- 11 *Armenio, S., G. Tanzini, F. Cetta, L. Caliendo, C. Guercia*: Anche nell'uomo i collettori linfatici sono dotati di una ritmica attività contrattile. *Abstr. IV Congr. Soc. Ital. Ricerche in Chirurgia* (1978) 64
- 12 *Armenio, S., G. Tanzini, F. Cetta, I. Caliendo, C. Guercia*: Even in man lymphatic vessels are endowed with rhythmic contractile activity. *Il. Policlinico (Sez. Chir.)* 86 (1979) 756
- 13 *Armenio, S., G. Tanzini, F. Cetta, C. Guercia, F. Burrioni*: Spontaneous contractile activity in lymphatic vessels of lower limbs in man. *Abstr. VII Int. Congr. Lymphology, Florence* (1979) 75
- 14 *Olszewski, W.L., A. Engeset*: Intrinsic contractility of leg lymphatics in man. Preliminary communication. *Lymphology* 12 (1979) 81