

Secondary Limb Edemas Following Irradiation

A.F. Tsyb, M.S. Bardychev, L.I. Guseva

Research Institute for Medical Radiology, Academy of Medical Sciences of the USSR, Obninsk, USSR

Summary

The results of clinical examination and treatment of 96 patients with secondary limb edemas, developed at late periods after radiation therapy of malignant tumors are discussed. The genesis of edema is accounted both for direct radiation injury of lymphatics and blood vessels (veins) and fibrous changes of tissue in irradiated areas.

The treatment of malignant tumors at present is based both on primary radiation therapy and on its combination with surgery. Following irradiation of major lymph vessels (cervical, supraclavicular, subclavicular, axillary, inguinoiliac irradiation fields) disturbances of regional blood and lymph circulation are often observed. Clinically they manifest in fibrosis of skin and limb edema of different extent. The disorders of lymph drainage and blood circulation are not caused by direct radiation damage to the lymph vessels, but mainly by compression due to severe radiation fibrosis of tissues.

The introduction of angiographic methods of examination of blood vessels and lymphatics ("angiolymphography") and especially their simultaneous study allow to obtain an objective information on the extent of disturbances of regional circulation and localization of radiation injury of vessels.

At present, two types of lymphovenous anastomoses are used for the treatment of lymphedema:

- 1) anastomosis of lymph node with vein and
- 2) direct anastomosis of lymphatic vessel with vein (1, 2, 3, 4, 5, 6).

The operations on the lymphatics became possible with the introduction of special microsurgical sets of instruments and different optical means.

Materials and Methods

In the period from 1970 to 1978 we examined 320 patients with late radiation fibrosis of skin; in 96 (30.0%) of them there was a decompensation of blood and lymph circulation. The patients aged 21 to 70 years (79 women, 17 men). The total absorbed dose of ionizing radiation is determinant in the development of late radiation damages. The analysis of our material has shown that radiation damages of blood vessels developed more often in patients in whom the total absorbed dose exceeded 50 Gy within 5-6 weeks. Isolated radiation injury of the lymphatic system is observed at values of absorbed dose of 40 Gy. The total absorbed dose in radiation injury area made up 40-60 Gy in 68 patients and over 60 Gy in 28 patients.

The time interval from the end of radiation therapy to manifestation of clinical signs of fibrosis and edema of limbs was from 7 months to 3 years in 63 patients, more than 3 years in 33 patients and in 12 of these patients it exceeded 15 years.

The area of radiation fibrosis of skin and underlying tissues corresponds usually to the size of radiation fields used. Since the lymphatic collectors of a few areas were irradiated several times, edema of two or even three extremities was observed in 13 patients (Fig.1). The basic data classifying the patients in de-

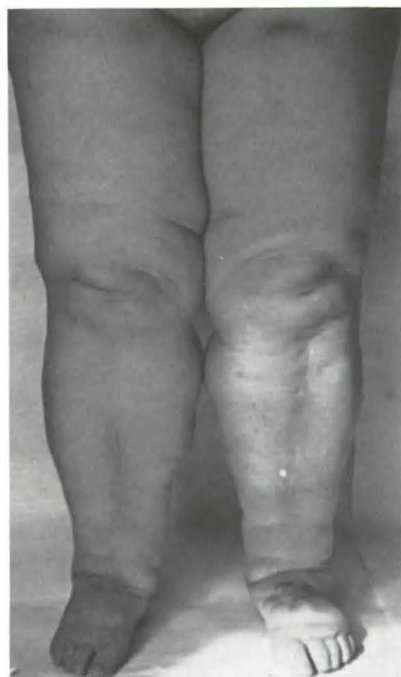

Fig. 1 Female patient, L., 50 years. Bilateral lymphostasis of the lower extremities. The combined gamma therapy for II-stage-carcinoma of uterine cervix was performed 4 years before at a total absorbed dose of 60 Gy on the primary lesions and of 40 Gy on the regional lymph nodes and the parametrium. Two months later, in irradiated field of both inguino-iliac areas the apparent fibrosis of skin and underlying soft tissues developed and 8 months later the increase of volume of both limbs was observed

pendence on radiation therapy type and disease are given in Table 1.

Table 1 Findings of investigations of patients with radiation-induced fibrosis of skin and disturbance of regional circulation

Disease	Number of patients	Type of radiation therapy		Localization of injury	
		x-ray therapy	Gammatherapy	Upper extremity	Lower extremity
Breast carcinoma	46	15	31	46	—
Cancer of female genitals	21	12	9	—	21
Hodgkin's disease	17	—	17	11	6
Malignant tumours of skin and soft tissues	5	2	3	1	4
Other malignant tumours	7	—	7	—	7
Total	96	29	67	58	38

Simultaneous phlebolympography was carried out in 74 (71%) patients, in others the lymphography was unsuccessful and only phlebography was performed. From the analysis of phlebograms we could judge indirectly the state of lymphatics and regional lymph flow in this group of patients. If these patients had clinically manifested edemas and normal venous pattern on phlebograms, it was possible to suggest decompensation of lymph circulation. The study started with lymphography. A lymphatic vessel was punctured on the dorsum of the foot, using common technique, and then endolymphatic injection of 3–5 ml of contrast-medium (Ultrafluid Lipiodol, Myodil) was made. Passage of contrast-medium was observed by means of fluoroscopy. If symptoms of lymph circulation blockade appeared, injection of contrast-medium was stopped.

Phlebography was performed on a sheet-film changer. 25–30 ml of 60% contrast-medium were injected intravenously by means of an automatic injector. Serial roentgenologic survey was performed according to a special program with duration of 25–30 sec. The number, calibre and course of vessels, the state of valvular apparatus, the passage rate of contrast medium, the presence of pathological reflux and other characteristics were taken into account during analysis of lymphograms. The venous system state was evaluated according to the findings of phlebography (vein contours, presence of anastomoses, duration of opacification etc.). The passage rate of contrast material was the main roentgenologic sign in assessment of regional circulation.

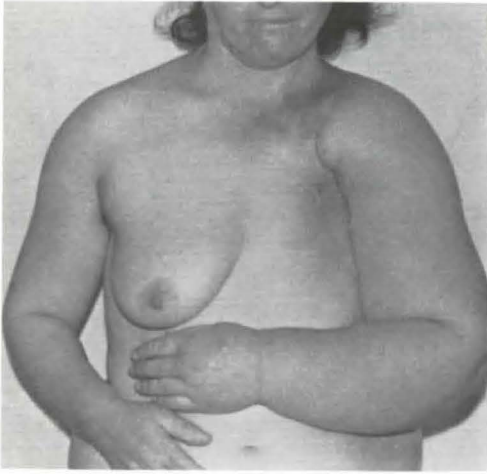


Fig. 2A

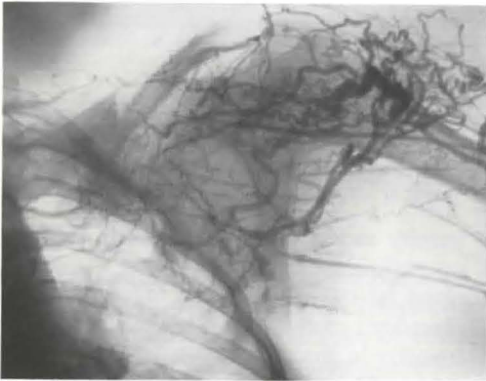


Fig. 2B

Fig. 2 Female patient, M., 53 years. The late radiation fibrosis of skin of the thorax combined with the severe edema of the left upper extremity (A). Postoperative teletherapy at a total absorbed dose of 46 Gy per field was performed for carcinoma of the breast.

B) At angiographic examination the obstruction of axillary and subclavian veins with subcompensated blood drainage through collaterals was seen.

C) Lymphogram of the same patient. Note the decompensation of the lymph circulation

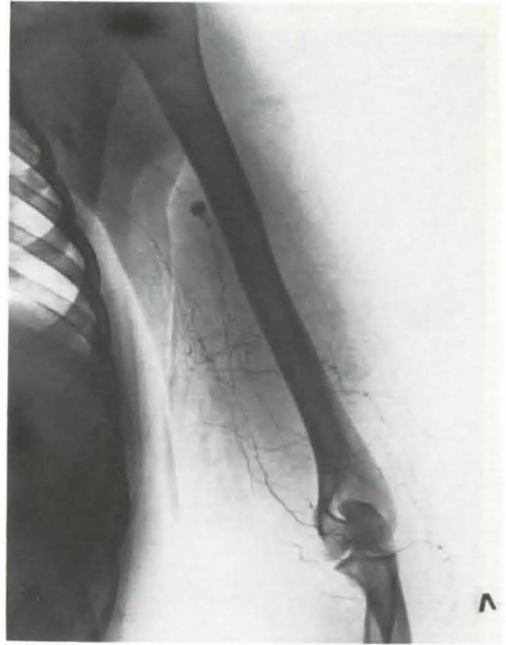

Fig. 2C

Results and Discussion

In all 96 patients with limb edemas the radiation damage of vessels was combined with the radiation fibrosis of skin and subcutaneous fatty tissues. The radiation fibrosis area of tissues is represented externally as hypo- and hyperpigmentation of skin with the zones of teleangiectases. The severity of the changes depends directly on time elapsed after radiation therapy.

The analysis of phlebographic and lymphographic findings has shown that in 50 patients (52.2%) the limb edema developed due to radiation injury of the lymphatic system only, in 33 patients (34.3%) the combined lesion of blood and the lymphatic vessels was observed (Fig. 2) and 13 (13.5%) patients revealed an isolated damage of magistral veins. In the latter case the alterations in irradiated areas of the lymphatic system also occurred, but the lymph drainage was compensated on the whole.

The method of treatment was chosen in dependency on the results of lymphophlebogra-

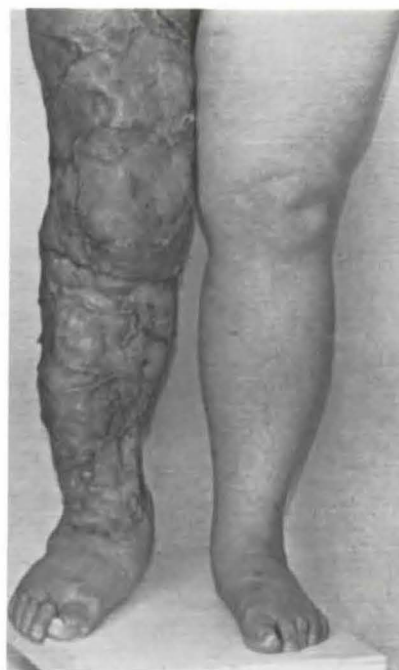
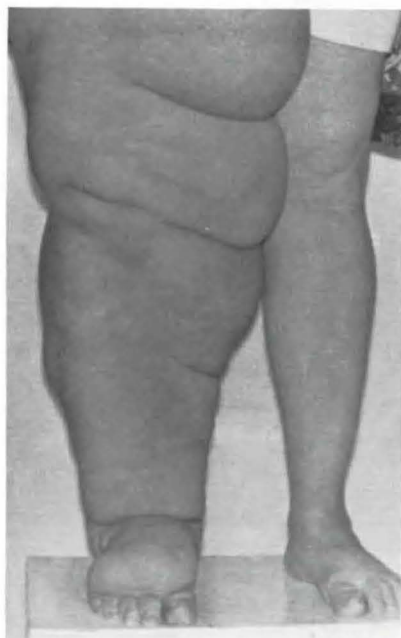
Fig. 3A

Fig. 3B

Fig. 3 Female patient, P., 48 years. A) Severe elephantiasis of the right lower extremity. Combined gamma-therapy for carcinoma of uterine cervix with the total dose on the ilio-inguinal field of 52 Gy. B) The appearance after the total excision of hypertrophied tissues with free split skin graft. Complete recovery

phy. In patients with limb edemas due to radiation damage of the lymphatic system only we distinguished two types of lymph circulation disorders:

- 1) elephantiasis and
- 2) chronic lymphedema.

Clinically, limb elephantiasis revealed persistent dense edema with appreciable thickening and induration of skin and subcutaneous fatty tissue; the skin was soldered with the underlying tissues and xeroderma, desquamation and sweating were observed. The anamnesis of these patients includes recurrent erysipelatos inflammations and consequently enlarged circumference of the limb. Lymphographic investigation often failed due to lymphatic obstruction.

We observed 10 patients with secondary radiation-induced elephantiasis of extremity. In 5 patients with involvement of lower ex-

trermity and in 1 patient of upper extremity, we performed the total excision of hypertrophied fat tissue and fascia, followed by replacement of the split skin graft to the extremity. In the other patients, the partial excision of hypertrophied tissues and fascia was performed. In all patients immediate and long-term results were considered to be good (Fig. 3). The chronic lymphedema was manifested clinically in an increased limb volume. The edema was dense but not constant: If the extremity was elevated, a decrease could be observed and, in some patients, a translocation from the distal to the proximal sections. The skin had normal colour, the venous pattern was expressed and there was no trophic disorder. In the anamnesis of these patients, erysipelatos inflammations were absent. Lymphography revealed partial or total block on the level of the inguinal or axillary lymphatic center with signs of sub- and decompensation of lymphatic circulation.

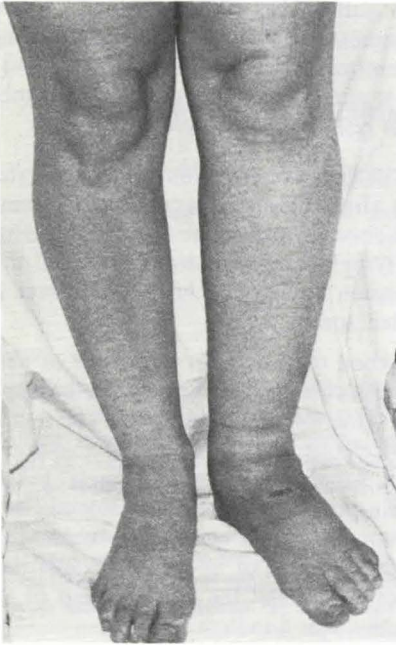

Fig. 4A

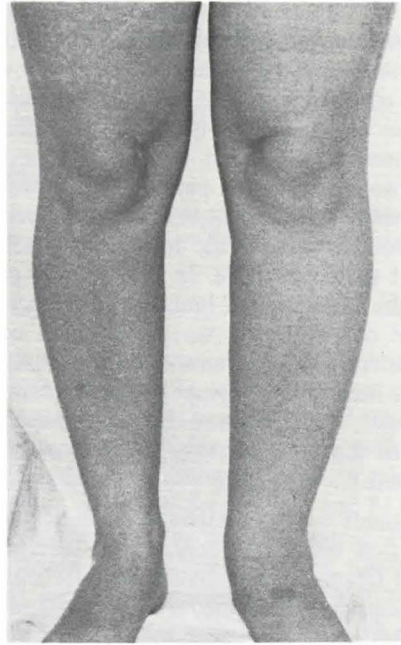


Fig. 4B

Fig. 4 Female patient, K., 25 years. Bilateral lymphostasis of the lower extremities. Combined therapy for carcinoma of the cervix uteri, stage II. A) Appearance of the patient before application of lymphovenous anastomoses. The difference of the circumference of the medial third of the skin is 5 cm. B) The same patient on the 10th day after performance of surgical lymphovenous anastomoses. The difference of the circumference of the medial third of the skin is 3 cm

Surgical treatment of chronic lymphedema consisted in formation of direct lymphovenous anastomosis, distal to the site of obstruction. Lymphovenous anastomoses have been performed in 30 patients with late radiation damages of the skin and soft tissues, followed by decompensation of the lymph circulation. In 7 patients, lymphovenous anastomosis was applied to restore lymph circulation, even if there were angiographic symptoms of subcompensation of venous drainage. Lymphographic results determined the type of anastomosis: lymph node or lymphatic with vein. In the latter case, the shunts of 3–4 lymphatics to 1 vein were performed under favorable anatomic-topographic conditions. Lymphovenous anastomosis was performed under microscopic control (Zeiss, GDR) using sutures 8/0 and 10/0. Surgical details are described below. To control blood coagulation

before the operation, vasodilators, proteolytic enzymes and anticoagulants are used. During operation, intravenous injection of low-molecular dextrans is made and repeated on the 3rd–5th and 7th day. Surgical intervention was immediately followed by a light massage of the limb for acceleration of lymph flow through the anastomosis. On the operating-table the elastic bandage is applied and the extremity is elevated. Exercise therapy is started the second day. The patients are usually up on the second to third day. Coagulative control on the 3rd–5th and 7th day excluded in most cases the use of heparin in the postoperative period. Only in cases of expressive tendency to hypercoagulation heparin was applied in doses of 5000 units every 4 hours during 3 days, which was followed by anticoagulants of indirect action.

In 20 (66.7 %) of 30 patients with surgical lymphovenous anastomoses immediate results were found to be good. An average reduction of limb circumference of 5–6 cm and the disappearance of feeling of burden and tension were observed on the 2nd–3rd day. The best results were obtained in patients with intact venous drainage. In patients with subcompensated blood circulation the decrease of edema was not so considerable. In 10 (33.3 %) patients the reduction of limb circumference was not observed after the performance of surgical lymphovenous anastomosis. In these patients however, the lymphedema was not progressive, which allowed us to evaluate the results of the surgical treatment as favorable (Fig. 4a, b).

The patients with decompensated blood and lymph flow underwent conservative therapy. For the treatment of radiation induced fibrosis of skin and subcutaneous fatty tissue, daily applications of 20–50 % solution of dimethylsulfoxide are used in combination with dexasone within 20–25 days. This resulted in softening of the fibrosis and reduction of the inflammatory skin reaction. Good results are achieved by electrophoresis with proteolytic enzymes and heparin and by blockades of fibrotic zones with a solution of novocain with dexasone. The improvement of microcirculation plays an important role in complex conservative treatment. For this purpose, the lumbar paranephrologic blockade by A. V. Vyshnervski is performed, with application of a compress with Vyshnervski's ointment on the limb for 7 days and the use of vasodilators, proteolytic enzymes and intravenous injections of a low-molecular dextran. Taking into account the results of coagulograms, anticoagulants of indirect action are used during 6–12 months, under control of prothrombin time. Massage, elastic bandaging of limb and exercise therapy are applied. The favorable results of conservative treat-

ment manifested in stabilization of the limb size; decrease of feeling of burden, swelling and numbness were observed in 48 (50 %) patients and in 3 (3.1 %) patients the limb edemas disappeared completely.

Thus, the genesis of the limb edema at late periods after radiation therapy of malignant tumors consists in the direct radiation damage of the lymphatics and blood vessels and their compression by fibrous changes of tissues in irradiated zones.

The method of choice for treatment of patients with chronic lymphedema is the application of lymphovenous shunts and for treatment of elephantiasis, the radical excision of the skin, subcutaneous fat and fascia, followed by a skin plasty. In cases of combined edemas the treatment should be conservative and directed on the decrease of intensity of radiation fibrosis of tissues and the improvement of the coagulative blood indices.

References

- 1 *Bardychev, M.S.*: Reconstructive plastic surgery in radiation damages of lymphatic system. *Grekov-Vestnik chirurgii*. 119: 8 (1977) 90–93
- 2 *Clodius, L., J. Uhlschmid, J. Smahel*: Microsurgery and lymphatics. In: *Microsurgery*. Ed. by A. Daniller et al., St. Louis 1976
- 3 *Kirpatovski, I.D., E.D. Smirnova*: Fundamentals of the microsurgical technique. Moscow 1978
- 4 *Makhov, N.I.*: A new method for treatment of elephantiasis by means of transplantation of lymphatic trunks of thigh into the vena saphena magna. *Chirurgia* 12 (1950) 69–70
- 5 *Nielubowicz, J., W. Olszewski*: Experimental lymphovenous anastomosis. *Brit. J. Surg.* 55 (1968) 440–451
- 6 *Petrovski, B.V., V.S. Krylov, N.O. Milanov, G.A. Stepanov*: Direct lymphovenous anastomosis with the use of microsurgical technique in secondary lymphedema of the limbs. *Klinicheskaya kirurgiya* 1 (1978) 4–8
- 7 *Rajevski, B.*: Doses of irradiation and their influence on the organism. Moscow, 1959
- 8 *Vishnervski, A.A.*: Selected works on surgery and borderlands. Moscow 1 (1970) 109–111

Dr. A.F. Tsyb, Research Institute for Medical Radiology, Academy of Medical Sciences of the USSR, Obninsk, Kaluga Region, ul. Korolyova, 4, USSR