

The Effect of Cardiac Lymphostasis on the Microcirculation of the Heart

Effect of cardiac lymphoedema on the development of an arteriovenous shunt circulation

F. Solti, Gy. Ungváry, P. Gloviczki, M. Sebestyén, E. Tátrai, G. Töreky

Institute of Vascular Surgery, National Institute of Labour and Work Hygiene Budapest, Hungary

Summary

The effect of cardiac lymphostasis on the microcirculation of the heart was studied in 18 dogs. By ligation of the main lymph trunks and regional lymph nodes of the heart, cardiac lymphoedema — lymphogenic cardiomyopathy — was induced in 9 dogs, while 9 served as control animals. For microcirculatory investigations:

- 1) gelatin Indian ink injection, 2 benzidine reaction,
- 3) PVC injection corrosion preparation was applied.

Characteristic changes were demonstrated in the microcirculation and capillary circulation of the heart in cardiac lymphostasis. In some capillaries—mainly where interstitial oedema exists — the capillary circulation decreased: inhomogeneously vessel-free spots were formed in the heart. Around the vessel-free capillaries, elongated capillaries were found including very dilated pre- and post-capillary vessel sections. Arteriovenous shunts can be revealed in the heart in consequence of lymphoedema. The pathogenesis of the microcirculatory circulation changes caused by cardiac lymphostasis was discussed.

In the course of cardiac lymphostasis, interstitial oedema, myocardial damage and fibrosis lymphatic cardiomyopathy will develop in the heart. It is remarkable that arteriovenous shunt communications have been published on the effect of lymphoedema of the limbs (Solti et al. 1971). However, how the cardiac capillary and microcirculation are altered by cardiac lymphostasis has not been investigated. The present experiments aim to establish the effect of artificial lymphatic cardiomyopathy on the cardiac microcirculation.

Experimental methods

The experiments were performed in 18 mongrel dogs of both sexes weighing 12–20 kg. In 9 dogs cardiac lymphostasis was introduced by ligation of the regional cardiac lymph nodes and the main collecting lymph trunks of the heart (mechanical insufficiency of the cardiac lymph circulation). The operation was performed in sodium barbiturate anaesthesia (0.20 g/kg i.v. infusion) with mechanical ventilation; the heart was exposed by anterolateral thoracotomy in the 3rd intercostal space. In 9 dogs thoracotomy only was performed (sham operation).

Corrosion and tissue microcirculation analyses were performed 48–72 hours after the operation at the peak of the cardiac lymphoedema. For the investigations of cardiac capillary and microcirculation, the following histomorphological methods were applied:

1. Benzidine reaction. Organ parts including the full wall thickness of the left ventricle were fixed in 10% formalin for 24 hours. Parts were cut in the frozen state to the thickness of 20, 40 and 100 μ at first parallel to the surface (1st direction) then vertically and parallel to the base of the heart (2nd direction and finally, perpendicular to both directions of intersection (3rd direction). The blood supply of both capillaries and precapillaries was determined by benzidine reaction (Romeis 1948).

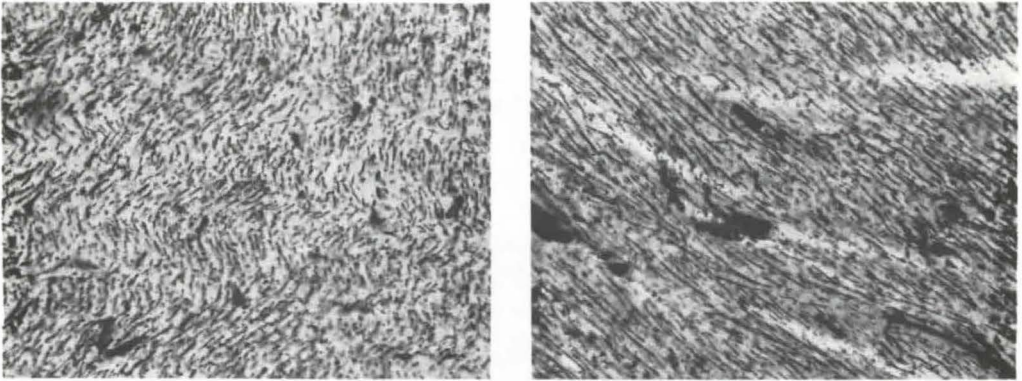


Fig. 1 Effect of cardiac lymphoedema on the capillary, pre- and post-capillary network of the heart (benzidine reaction method). The left side of the figure shows the benzidine reaction preparations made in a control animal and the right side the preparations after cardiac lymphostasis. The blood volume of the capillaries is nearly the same subsequent to the influence of cardiac lymphoedema, but the development of some elongated, dilated vessel sections can be detected.

2. Gelatin Indian ink injection. 2% gelatin Indian ink was injected into the left ventricle of the anaesthetized animal which was killed by i.v. injection of concentrated KCl solution. Specimens taken from various parts of the heart (auricles, atrial walls, ventricle walls, left ventricle, papillary muscle, atrial septum) were fixed in 8% formalin and processed as frozen sections. The sections were treated according to the method of *Spalteholz*.

3. PVC injection corrosion preparation. Prior to the sacrifice of the animal, one catheter was introduced into the aorta ascendens and another catheter into the coronary sinus through the right atrium of the anaesthetized animals. With the aid of the catheter, 5% polyvinylchloride solution was injected into the arterial and venous system of the heart. In some cases a double-plane X-ray was also taken of the excised heart. The 5% PVC solution did not penetrate through the capillaries, so that the vascular cast made after hydrochloric corrosion was suitable for the determination of the topography and arteriovenous shunts of the main arteries.

Histological examinations were performed in 6 animals. Samples were taken from different parts of the heart (auricles, ventricles, ventricular septums, papillary muscle). Fixation

was made in 8% formalin, paraffin embedding.

Haematoxylin-eosin was applied for staining and haematoxylin basic fuchsin picric acid was used for the early detection of ischaemia (*Lie et al.* 1971).

Results

Histological signs of lymphatic cardiomyopathy (interstitial oedema, myofibrillar injury, round-cell infiltration) were regularly observed by histological examination in the heart after ligation of the cardiac lymph nodes. No pathological changes could be observed in the heart of the sham-operated control dogs. The most overt lymphoedema and concomitant symptoms were observed in the epicardium. According to the benzidine reaction investigations, the blood volume of the capillaries and precapillaries showed only a slight change in the effect of cardiac lymphoedema. However, there was a characteristic difference i.e. longer, saciform dilated pre- and postcapillary vessels could be observed only in cardiac lymphoedema (see Fig. 1).

Gelatin Indian ink preparations showed that the filling of cardiac capillaries and precapillaries in control animals was complete. After



Fig. 2a

the induction of cardiac lymphostasis, large, empty vessel spots were observable in particular in the deepest layers of the myocardium (see Fig. 2).

In corrosion preparations, arteriovenous shunts were demonstrable in the heart in consequence of cardiac lymphoedema (in four cases of altogether six). No arteriovenous shunts were detected in the control group. A fact also deserving attention was that fewer coronary side branches were repleted from the main coronary branches in the post-mortem angiograms on the effect of cardiac lymphostasis.

A characteristic arteriovenous shunt induced by cardiac lymphostasis is shown in Fig. 3.

Discussion

Following ligation of the main lymph trunks and regional lymph nodes of the heart, interstitial oedema and pathological changes will appear in the cardiac tissues (Földi et al. 1954, Jacobs et al. 1976, Kline et al. 1963, Miller et al. 1963, Solti et al. 1968, Sun and Lie 1977, Ullal et al. 1972). It seems very probable that cardiac lymphostasis is involved in the pathogenesis of some heart failure (Kline et al. 1963, Miller et al. 1963). Not

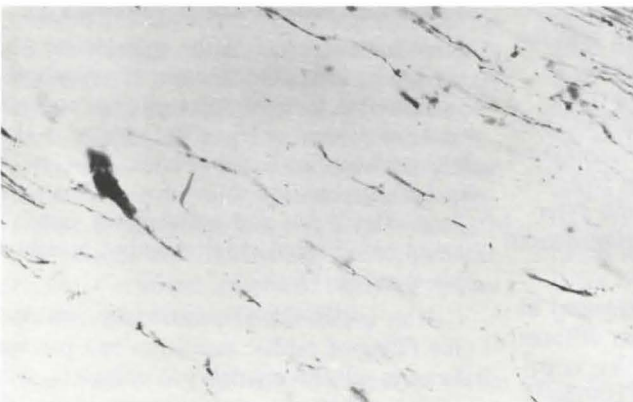

Fig. 2b

Fig. 2 Effect of cardiac lymphoedema on the microcirculation of the heart in a gelatin Indian ink preparation. On the upper side of the picture, the filling of a control dog's heart with gelatin ink is seen. Small cardiac vessels (capillaries, pre-capillaries, post-capillary venules) are well presented. On the lower side of the figure, many "empty" non-filling spots are seen in the heart. These vessel-free spots are crossed only by some, irregular capillaries and post-capillaries with calibre fluctuation.

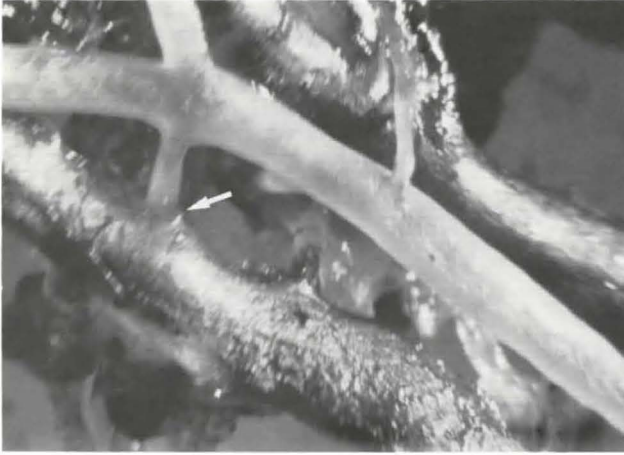

Fig. 3 Development of the arteriovenous shunt in the heart in lymphatic cardiomyopathy as seen in a PVC corrosion preparation. PVC corrosion preparation made of a dog's heart after ligation of the main lymph trunks and regional lymph nodes of the heart. There is an arteriovenous shunt and arteriovenous anastomosis marked by ↓. Yellowish-white stain was added to 5% PVC solution instilled into the arterial branch and greenish-yellow stain in the case of the venous branch.

only histological, but also structural changes and disturbance of the function of the heart can result from cardiac lymphoedema (Ullal et al. 1972). It is worthy of note that endothelial swelling, subendothelial plasma imbibition and fibrinoid necroses of the vessel wall may develop in the small coronary branches in consequence of cardiac lymphostasis (Solti et al. 1968). *Oddly* enough, the effect of the cardiac lymphostasis on the coronary circulation and cardiac microcirculation has not yet been studied. *Eliska and Eliskova* (1975) observed the development of lympho-lymphatic and lymphovenous anastomoses in mechanical insufficiency of the cardiac lymph circulation.

It is postulated that the development of lymphovenous anastomoses contributes to the decrease of the cardiac lymphoedema and the concomitant symptoms within a few weeks after the ligation of the cardiac lymph vessel.

The results of our present investigations prove that in lymphostatic cardiomyopathy – in cardiac lymphoedema – significant changes can be revealed in the capillary circulation of the heart. In the course of lymphostasis, the filling of the capillaries inhomogeneously diminishes in the heart (see Fig. 2). The nutritive capillary circulation decreases in the area in question. In some vascular areas, long capillaries with concomitant dilated pre- and post-capillary vessels can be detected in cardiac

lymphostasis. In addition to the lack of capillary filling, it indicates an increased flux from the surrounding intact vessel area which is of compensatory character. The most important and characteristic alterations of the coronary circulation are the developments of arteriovenous communications, arteriovenous shunts in the insufficiency of cardiac lymph circulation. The above mentioned microcirculatory changes occurring in cardiac lymphoedema are similar to those observed in limb lymphoedema (Solti et al. 1971).

The question arises as to the pathomechanism of the changes of coronary microcirculation occurring in lymphatic cardiomyopathy. Although the bases and mechanism of the regulation of the coronary microcirculation are not known exactly as yet, it is very probable that the following factors play an important role in the microcirculatory changes as a result of lymphatic cardiomyopathy.

1. In consequence of lymphostasis, interstitial oedema develops in the heart and oedema is also found around the capillaries (perivascular oedema). The accumulated tissue oedema can compress the thinwalled nutritive capillaries so that inhomogenous, empty “vessel-free” spots are seen in the heart corresponding to the interstitial oedema. The compression of some nutritive capillaries promotes the opening of arteriovenous communication between pre- and post-capillaries.

2. It can also be supposed that vessel wall injuries following cardiac lymphostasis also play an active role in the alterations in the coronary microcirculation. According to our experiments, small coronary branches fill inhomogeneously in cardiac lymphoedema. This fact also indicates that the small coronary vessels are impaired in consequence of the lymphoedema.

References

- 1 *Eliška, O., M. Eliškova*: Contribution to the solution of the question of lymphovenous anastomoses in heart of dog. *Lymphology* 8 (1975) 11
- 2 *Földi, M., Gy. Romhányi, I. Ruzsnyák, F. Solti, G. Szabó*: Über die Insuffizienz der Lymphströmung des Herzens. *Acta Med. Acad. Sci. Hung.* 6 (1954) 61
- 3 *Jacobs, G., F. Kleinschmidt, L. Benesch, W. Lenz, G. Uhlig, F. Huth*: Tierexperimentelle Untersuchungen des Kardialen Lymphgefäßsystems. *Thoraxchirurgie* 24 (1976) 453
- 4 *Kline, I.K., A.J. Miller, L.N. Katz*: Cardiac lymph flow impairment and myocardial fibrosis. Effects of chronic obstruction in dogs. *Arch. Pathol. Chicago* 75 (1963) 424
- 5 *Lie, J.T., K.E. Holley, W.R. Kampa, J.L. Titus*: New histochemical method for morphologic diagnosis of early stages of myocardial ischemia. *Mayo Clin. Proc.* 46 (1971) 319
- 6 *Miller, A.J., R. Pick, L.N. Katz*: Ventricular endomyocardial changes after impairment of cardiac lymph flow in dogs. *Brit. Heart J.*: 25 (1963) 182
- 7 *Romeis, B.*: *Mikroskopische Technik*. Oldenburg, R., München 1948, 25
- 8 *Solti, F., M. Iskum, J. Nagy, A. Hartai, B. Veress, I. Hüttner, T. Kerényi*: The effect of mechanical lymph flow insufficiency on cardiac muscle necrosis as a result of coronary ligation. *Cor Vasa* 10 (1968) 68
- 9 *Solti, F., Gy. Ungváry, A. Bálint, Z. Nagy*: The regulation of the limb circulation in lymphoedema. Development of an arteriovenous shunt circulation in experimental lymphoedema of the leg. *Angiologica* 8 (1971) 117
- 10 *Sun, S.C., J.T. Lie*: Cardiac lymphatic obstruction. *Mayo Clin. Proc.* 52 (1977) 785
- 11 *Ullal, Sh. V., T.H. Kluge, F. Gerbode*: Functional and pathological changes in the heart following chronic cardiac lymphatic obstruction. *Surgery* 71 (1972) 328
- 12 *Ungváry, Gy., J. Faller*: Vena – hepatica – Lap-pen in der Leber. *Zbl. Chir.* 88 (1963) 1885

Dr. Francis Solti, Institute of Vascular Surgery, Varósmajor Str. 68, H-1122 Budapest, Hungary