

Two Cases of Cystic Lymphangioma in the Neck Region in Adults

M. Numata, S. Asato, Sh. Hosoe, N. Itoh, Sh. Hayashi

Summary

Two cases of cystic lymphangioma which developed in the neck region of adults are reported. The first case was a 46 year old housewife who noticed a swelling on her right neck region. The tumor was a unilocular cystic benign tumor covered with thin capsule and removed from the surrounding tissue. The second case was a 19-year old male who noticed sudden swelling on his left side of the neck following a traffic accident. The swelling was a multilocular benign cyst which contained yellowish serous liquid, as in case 1. The cyst was removed successfully. The two cases had a favourable post-operative course and there have been no signs of recurrence. Histologically the cysts contained one layer of endothelial cells and an accumulation of lymphocytes.

Cystic lymphangiomas are usually found in children between 1 to 2 years old and rarely occur in adults. The two patients described here are exceptions to this pattern.

Case I: A 46 year old housewife had a swelling on her right neck, which she noticed while bathing in March, 1979. The skin from the right shoulder up to the neck was swollen and upon touching it she detected a soft cyst in the swollen region, not accompanied by pain or reddening. Three days later she visited the Department of Surgery at Shinshu University. The tumor was aspirated and 10 ml of a light yellow serous liquid was removed. She returned to the hospital when the swelling increased in size in June 1979. On examination the neck region appeared swollen and the healthy skin was cracked. Examination of the affected area revealed a tumor below the surface of the skin about the size of a fist; it was soft and there were ridges and valleys on

the surface. The boundaries with the surrounding tissue were relatively indistinct. On puncturing the cyst, a light yellow liquid was obtained which had lower total protein and albumin concentration than that in the blood serum.

After puncturing the cyst, cystography was performed which showed the picture of an unilocular cyst (Fig. 1). Also from the right brachial artery, retrograde angiography was performed which showed that the tumor was poor in blood vessels (Fig. 2). These results confirmed the diagnosis of an unilocular cystic lymphangioma and on June 17, under general anesthesia, it was excised.

Findings at operation: A transverse incision was made on the central portion of the tumor. The right sternocleidomastoid muscle was stretched and flattened. It was easy to isolate and remove the tumor together with its capsule from the surrounding tissues. The size of the excised tumor was 8 cm x 6 cm x 6 cm, and the lumen contained a light yellow serous fluid mixed lymphocytes, and the capsule consisted of one layer of endothelial cells. An accumulation of lymphocytes and/or lymphotic follicular structures was observed in the interstices of the wall of the cyst. Thus the diagnosis of cystic lymphangioma was reconfirmed (Fig. 3). The patient remains asymptomatic after one year.

Case II: A 19-year old male had swelling on his left side of the neck. He noticed shortly after an accident that a swelling from the neck to the left clavicle had developed. On the following day he was admitted to our hospital.

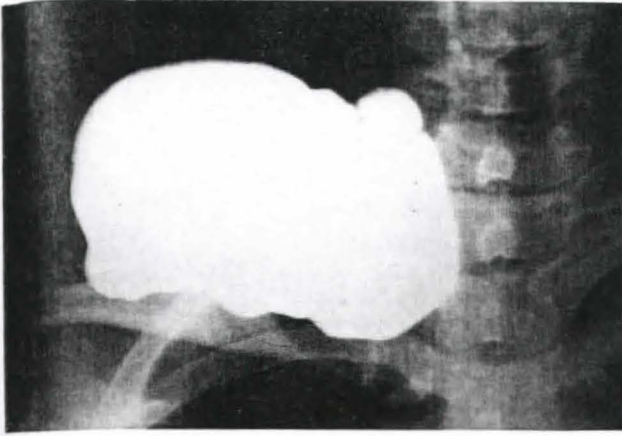


Fig. 1 Cystography reveals an unilocular cyst

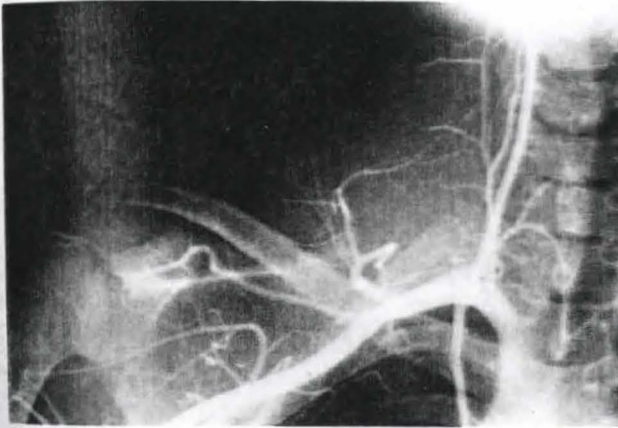


Fig. 2 Retrograde brachial arteriography reveals an avascular tumor

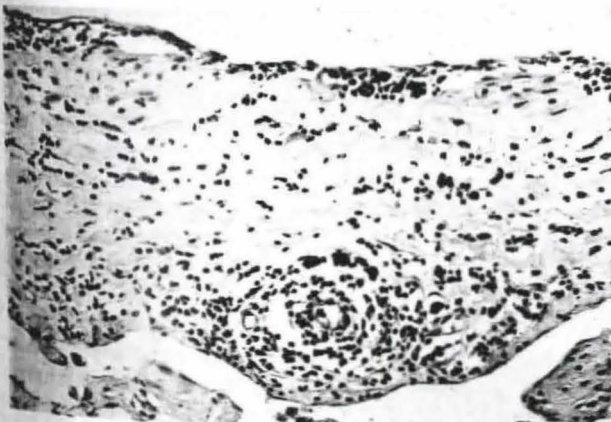


Fig. 3 The histological features of the tumors. The lumen of the cyst contained a light yellow serous fluid, mixed lymphocytes, and the capsule consisted of one layer of endothelial cells. An accumulation of lymphocytes and/or lymphatic follicular structure was observed in the interstices of the wall

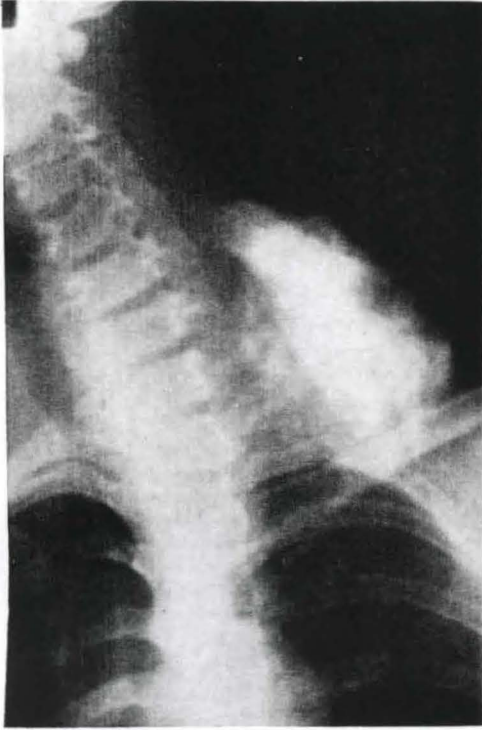


Fig. 4 Cystography filled only a part of the tumor

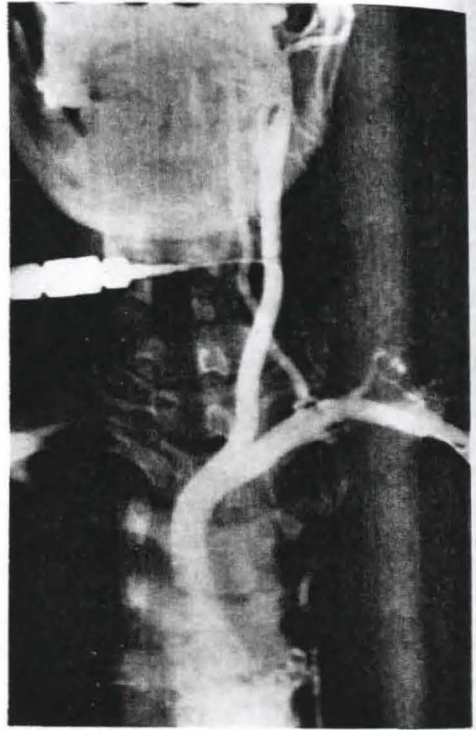


Fig. 5 Retrograde arteriography from the carotid artery showed no relation between the blood vessels and the tumor

A swelling was observed from the neck extending to the supraclavicular fossa, it was covered with normal skin. The tumor was fluctuant. The surface of this tumor was ridged and the boundaries unclear. A puncture of the swollen area was performed and yellow serous fluid mixed with blood was extracted. The chemical analysis of the fluid extracted by puncture was similar to case I in that the concentrations of total protein and albumin were lower than the blood serum.

Cystography after direct puncture revealed only part of the cyst (Fig. 4). Retrograde arteriography conducted from the carotid artery showed no direct relation between the blood vessels and the tumor (Fig. 5). At operation on May 13, under general anesthesia the tumor was removed in one lump. It

measured 10 x 6 x 8 cm and was covered with a thin membrane. Since the cross section showed various inner partitions it was considered multilocular. The cyst was filled with a light yellow transparent serous liquid. The results of histological study showed that the wall of the cyst was covered with a flat layer of endothelial cells. Due to the formation of many partitions it was diagnosed as a multilocular cystic lymphangioma (Fig. 6). Since there was no hypoplasia or thickening of the interior walls of the cyst, it was conjectured that this cyst was not one of long duration. The post-operative course proved favourable and until the present, one year after the operation, there have been no signs of recurrence.

Discussion

It is generally thought that cystic lymphangioma is due to some congenital disorder since about 90% of all cases are babies and children under 2 years of age (1). The etiology of cystic lymphangioma is believed to be due to the development of primitive lymph sacs within the jugular, retroperitoneal and bilateral posterior sacs of the embryo up to eight weeks. Some of these lymph sacs separate and are reported to form cysts (2, 3, 4, 5). During the embryonic period the jugular sac is the first to develop and since it is also the largest one it is usually the source of cystic lymphangioma in the neck (6). Concerning the sites favorable to the development of these cysts there is no dispute; the neck and the abdominal cavity predominate. Diagnosis of these cysts is fairly easy when they lie close to the surface. Characteristically the soft cysts are fluctuating and transparent. And there is mobility between them and the surrounding skin; they are painless and the boundaries are relatively distinct. The surface is rippled and the surface of the projecting portions is smooth and soft. Diagnosis is more difficult if the cyst is complicated by infection or hemorrhage or if it is located in the peritoneal cavity or a deeper area. *Van Cauwelaert et al.* (8) reports a case of transparent tumor in the peritoneal cavity which progressively enlarged from a cystic lymphangioma in which lymphography confirmed the diagnosis.

Ferguson and Frigoletto et al. (9, 10) using ultrasonography report they were able to diagnose cystic hygromas. In the case of the neck region it is important to distinguish such diseases from hemangioma, cervical cyst, teratogenous blastoma, lipoma etc. In case 2 where the cyst was accompanied by an external injury it must also be differentiated from hematoma (11, 12). For differential diagnosis it is necessary to directly puncture the cyst and perform cystography. However, *Katsuma et al.* (6) reported that one should not treat infantile hygroma by drainage. In order to prevent infection and for fear of injuring the surrounding tissue, one should avoid puncturing as far as possible.

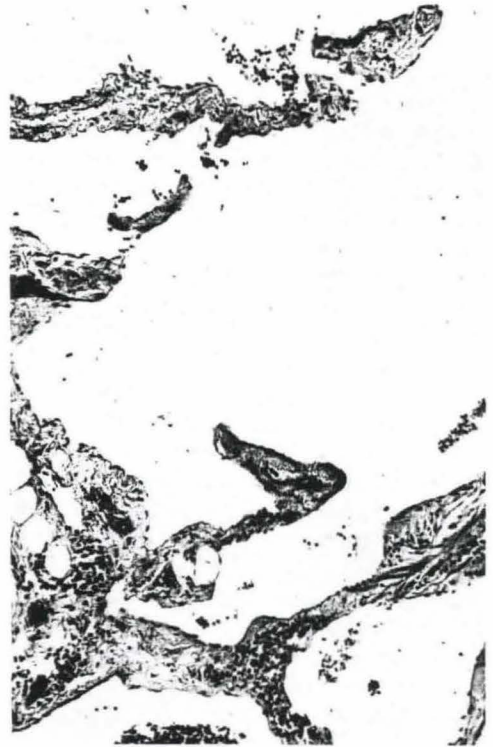

Fig. 6 Histological features of the tumor. The cyst was filled with a light yellow transparent serous liquid and covered with a flat layer of endothelial cells

Lymphangioma is classified as follows (13):

1. Lymphangioma simplex, 2. lymphangioma cavernosum, 3. lymphangioma cysticum. *Saito et al.* proposed the characteristics of lymphangioma cysticum as follows (7): It contains various sizes of cysts. The internat surface is flat and covered with epithelium. Within the cyst there is serous light yellow, transparent liquid. Histologically, the wall of the cyst is covered with a thin flat layer of endothelium. There is an accumulation of lymphocytes within the cavity. Also there is a collection of lymphocytes in the capsule.

The disease is relatively rare in adults. *Matsumoto et al.* (14) report a case of this disease occurring in the right axilla of a 16-year old girl. *Shimizu et al.* (15) reported a lymphangio-

ma on the right neck in a 24-year old woman. During a 20-year period, of 18 cases of lymphangioma, only two occurred in adults. Miller et al. (16) report the case of a 63-year old patient who suddenly developed large cystic lymphangioma and commented on the cause that residual tissue of the primitive lymph sacs which did not develop during childhood still have some mechanisms that permit rapid hypoplastic development. But it is still not clear what causes these residual cells to suddenly undergo hyperplastic development; various reasons given include infection of the upper respiratory tract (7), lymphatic stenosis or obliteration, increase in venous pressure. However, Narusawa et al. (17) report the case of a 13-year old boy who developed lymphangioma in the right axilla and the reason for the sudden growth of the tumor was due to the stimulus of a persistent external injury. The second case in our report developed lymphangioma after a traffic accident and it must be considered that this disease developed due to external injury or to temporary rise in venous pressure. However, the relation between lymphangioma and external injury still has many unresolved points. Although a persistent mechanical stimulus may indeed be a factor, it cannot be said to be an absolute requirement and it is necessary to carry out further studies on the occurrence of these tumors in adults. Concerning the treatment of this disease, it is considered advantageous to completely excise the tumor including the surrounding tissue. Stromberg et al. (18) state that in treating lymphangioma it is necessary to first completely excise it rather than using irradiation or coagulant therapies. However, in the case of excision it goes without saying that it is necessary to minimize as much as possible injury to the surrounding tissues. Since this type of tumor is soft with a thin tunic and is often multilocular with a varying etiology as reported, it is difficult to excise it completely and formerly recurrences were quite frequent. Recently treatment with bleomycin has been reported (19, 20) as being effective. However, complete excision remains the treatment of choice and the only absolutely adequate treatment. If it

is impossible to completely excise the lesion the first time then these supportive therapies may be used or a second attempt at complete excision should be considered.

References

- 1 Gross, R.E.: The Surgery of Infancy and Childhood. W.B. Saunders, Philadelphia, 1964
- 2 Sabin, F.R.: On the origin of the lymphatic system from the veins and the development of the lymph hearts and thoracic duct in the pigs. Amer. J. Anat. 1 (1901) 367
- 3 Sabin, F.R.: The lymphatic system in human embryos with a consideration of the morphology of the system as a whole. Amer. J. Anat. 9 (1909) 43-91
- 4 Dowd, C.N.: Hygroma cysticum colli, its structure and etiology. Ann Surg. 58 (1913) 112-132
- 5 Goetsch, E.: Hygroma colli cysticum and hygroma axillare. Arch. Surg. 36 (1938) 394-479
- 6 Katsumata, K., J. Yokohama, M. Endo, T. Denda: Cystic hygroma (Cystic lymphangioma) Surg. Diag. Treat. (Tokyo) 13 (1971) 1054-1060
- 7 Saito, S.: Lymphangioma. Surg. Diag. Treat. (Tokyo) 15 (1973) 277-282
- 8 Van Cauwelaert and Gruwez J.A.: Experience with lymphangioma. Lymphology 11 (1978) 43-48
- 9 Ferguson, M.M., M. England, D.G. Macdonald, K.F. Moos: Ultrasonography in the diagnosis of a cystic hygroma. Int. J. Oral Surg. 6 (1977) 229-232
- 10 Frigoletto, F.D., J.C. Birnholz, S.G. Driscoll, H.J. Finberg: Ultrasound diagnosis of cystic hygroma. Am. J. Obstet. Gynecol. 136 (1980) 962-964
- 11 Galofre, M.: Results of surgical treatment of cystic hygroma. Surg. Gynecol. Obstet. 115 (1962) 319-327
- 12 Woodring, A.T.: Cervical cystic hygroma, a review of the literature and report of an unusual case. Ann. Otolaryng. 77 (1968) 978-983
- 13 Landing, B.H., S. Farber: Tumors of the Cardiovascular system. In Atlas of Tumor Pathology Sect. III. Fasc. 7. Armed Force Institute of Pathology, Washington D.C., 1956
- 14 Matsumoto, H., Y. Nakamura, T. Chin: Cystic lymphangioma observed in the armpit of an adult woman. Surg. Diag. Treat. (Tokyo) 17 (1975) 1381-1383
- 15 Shimizu, T., M. Iwabuchi, Y. Yamagishi: A case of cystic lymphangioma observed on the neck of an adult woman. Surg. Diag. Treat. (Tokyo) 20 (1978) 204-206
- 16 Miller, J.M., T.C. Faboac: Cystic Hygroma colli in an adult. John Hopkins Med. J. 134 (1974) 233-236

- 17 *Narusawa, T., T. Soeno, T. Abe*: A case of cystic hygroma in the right armpit. *Geka*, (Tokyo) 35 (1973) 80-82
- 18 *Stromberg, B.V., P.M. Weeks, R.C. Wray*: Treatment of cystic hygroma. *Southern Medical Journal* 69 (1976) 1333-1335
- 19 *Kira, J.*: On the effect of bleomycin in treating children for cervical cysts, especially lymphangioma. *Pediatric External Medicine: Internal Medicine* (Tokyo) 8 (1976) 270-285
- 20 *Yura, J., T. Hashimoto, N. Tsuruga, K. Shibata*: Bleomycin treatment for cystic hygroma in children. *Arch. Jap. Chir.* 46 (1977) 607-614

*Dr. Minoru Numata, Department of Surgery, Shinshu University Medical School,
3-1-1 Asahi-Cho, Matsumoto, Naganoken 390, Japan*