

Hepatic Oil Embolization Following Lymphangiography A Report of 12 Cases

Jean N. Bruneton M.D.¹, Alain Le Treut M.D.², Michel Abbes M.D.¹,
Jean P. Occelli M.D.¹, Danièle Aubanel M.D.¹

¹Centre Antoine Lacassagne, 36 Voie Romaine, 06054 Nice Cédex, France

²Fondation Bergonie, 180 rue de Saint-Génès, 33076 Bordeaux Cédex, France

Summary

The authors report on 12 personal observations of lymphoportal fistulas, which represented 0.24% of their series of lymphographies. This rare complication of lymphography has no clinical or biological liver manifestations. Review of 71 cases in the literature confirmed that hepatic oil embolization only occurs when there are lymphatic masses, with or without associated thrombosis of the inferior vena cava.

Hepatic oil embolization is a rare complication of lymphography (1, 6, 11, 16, 17) representing only 0.19% of the cases reported by Chavez (7,8). Based on the 12 personal observations seen during more than 5.000 lymphographies practiced at the Fondation Bergonie in Bordeaux and the Centre Antoine Lacassagne in Nice, the characteristics of this infrequent complication and its pathological significance were reviewed.

Patients and Methods

Twelve cases of hepatic oil embolization following the use of Lipiodol during lymphography were observed among the more than 5.000 such examinations practiced; none of the patients presented any associated clinical indications of this complication. In the six cases for which biological liver function tests (alkaline phosphatase, transaminases) were conducted after discovery of the hepatic oil embolism, the results were always normal.

These 12 patients (9 women, 3 men) ranged in age from 35 to 77 years (mean 58 years). Primary cancers included: cervix uteri (4 cases), ovary (3 cases), testis (1 case), pancreas (1 case), histiocytofibrosarcoma of the left iliac fossa (1 case) and non-Hodgkin lymphoma (2 cases). A bilateral pedal approach was used for all lymphographies, which were obtained after appearance of uni- or bilateral hydronephrosis during intravenous urography or echography (6 cases), an abdominal mass (3 cases), edema of the lower members (1 case), appearance of a second cancerous localization (1 case of cancer of the right then the left testicle), or a drop in the patient's general condition (1 case).

The presence of metastatic adenopathies was confirmed in four cases by anatomopathological examination. In one patient with direct diffusion to the liver, without visualization of lymphatic vessels, a second lymphography obtained two months later following laparotomy and radiotherapy. Cavography was practiced in four cases and a CT scan was obtained three days after lymphography for another patient.

Death following lymphography occurred in less than six months for six patients, in less than one year for four patients, and after more than one year for two patients (1 non-Hodgkin lymphoma, 1 ovarian cancer).

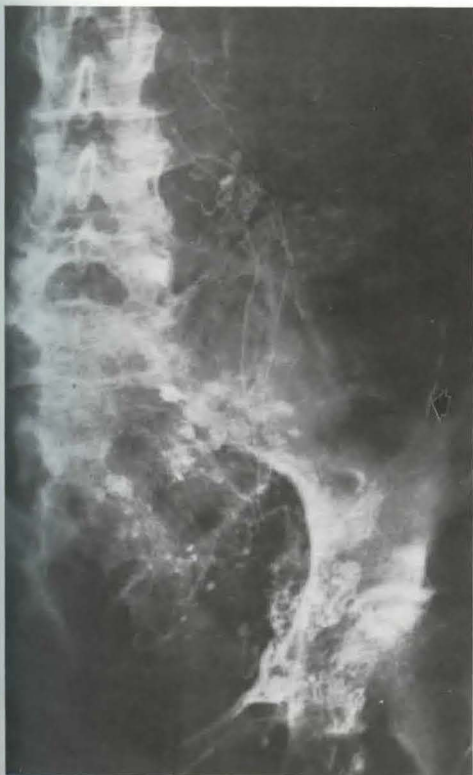

Fig. 1 Malignant lymphoma: opacification of the sigmoid wall (arrow) in relation with left iliac adenopathies diagnosed by ultrasound

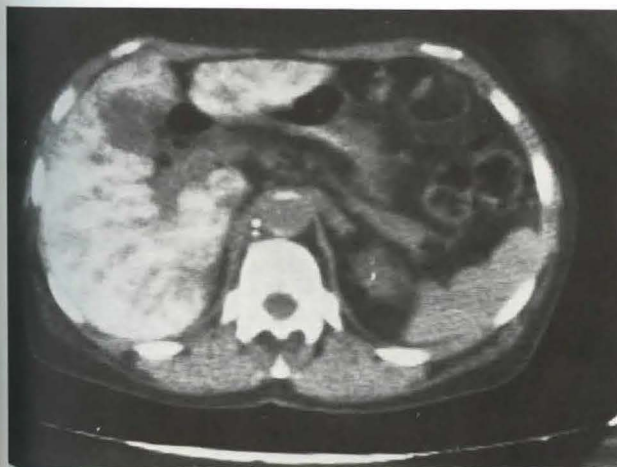


Fig. 2 CT scan of a woman with cancer of the uterus: Lipiodol opacification of the liver in connection with large lymphatic masses creating a lymphoportal fistula

Results

Ten of the 12 patients with a hepatic oil embolism also exhibited lumbo-aortic obstruction and pathological lymph nodes. One patient had direct diffusion to the liver without any lymph node opacification, but Lipiodol was observed in the mesenteric vein. In another case, there was left iliac involvement and opacification of the sigmoid wall (Fig. 1). The thoracic canal was visible in seven cases; no cases of pulmonary embolism were seen. The patient with direct diffusion of Lipiodol to the liver underwent surgery and radiotherapy; a second lymphography obtained two months later revealed partial obstruction and visualized a normal thoracic canal; no hepatic embolism was seen. The results obtained for the four cavographies were all pathological: three cases of thrombosis and 1 case of extrinsic compression. In the one case of CT, the scan confirmed lymph node involvement and clearly revealed a hepatic embolism, whereas the film obtained the same day gave only barely visible images (Fig. 2).

Discussion

Discovery of a hepatic oil embolism during lymphography is a rare occurrence, and represented only 0.24% of cases in our series, a frequency comparable to that of Chavez (7, 8). This asymptomatic condition does not appear to cause any biological disorders. Of

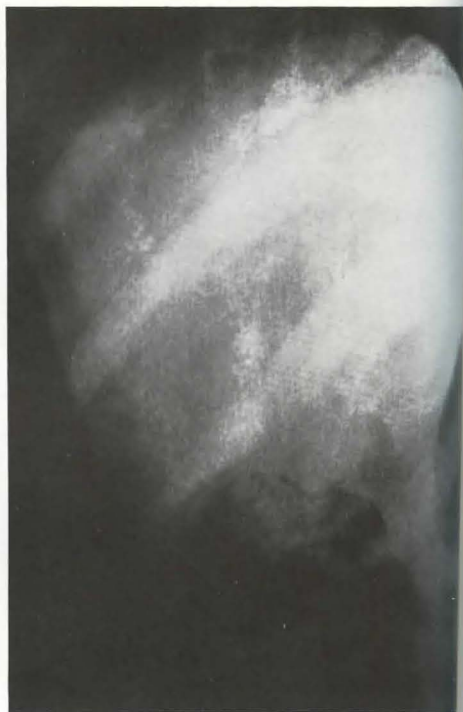

Fig. 3a and 3b Modification in the appearance of a hepatic oil embolism in a patient over a 24 hour interval.

Fig. 3a Fine arborizing pattern

Fig. 3b Granular pattern 24 hours later

the 37 cases studied by Chavez (7, 8), 36 corresponded to malignant tumors and one to a filariasis. In addition to our 12 personal observations and the 31 cases reported by Lechner (18), we reviewed another 40 cases (2, 3, 4, 5, 7, 9, 10, 12, 13, 14, 15, 19, 20, 21, 22, 23, 24, 25, 26).

From an etiological viewpoint, the primary malignant localizations of the 71 literature cases were as follows: testis (25 cases), uterus (21 cases), lymphoma (11 cases), colon (7 cases), kidney (3 cases), retroperitoneal sarcoma (2 cases), neuroblastoma (1 case), prostate (1 case). However, this complication of lymphography was also seen in connection with certain non-cancerous affections: filariasis (7, 8), tuberculosis (2) and retroperitoneal fibrosis (21).

From a radiological standpoint, lymphography revealed malignant lymph node involvement of a lumbo-aortic (65 cases reviewed) or

pelvic (2 case) localization (9, 24). No lymphatic opacification was visible in one case and only a hepatic embolism was seen (20). In the few rare cases of direct passage into the liver without lymph node opacification, a lymphatic mass leading to a large fistula was always discovered. In our case, radiotherapy closed this communication which had not been visible during surgery.

Images varied as a function of fistula size and the amount of Lipiodol embolized towards the liver. In the presence of relatively large amounts of intrahepatic Lipiodol, the fine arborizing pattern seen corresponded to the portal vessels. A granular pattern was observed with small amounts of contrast medium or fine fistulas. However, a granular pattern could be observed several days after an arborizing pattern prior to complete disappearance from x-rays (Fig. 3a and 3b).

The thoracic canal was rarely visible (3, 1

and observations of pulmonary embolisms remain rare (15). Thanks to their sensitivity, CT scans should allow more accurate and especially more frequent detection of this anomaly during the course of voluminous lumbo-aortic lymph node affections.

The existence of lympho-venous communications was demonstrated over 15 years ago (7, 8, 14). Hepatic oil embolization following lymphography necessitates a large obstruction although complete lymph node occlusion is not always required since the thoracic canal was visible in two of the cases reviewed (3, 15). While thrombosis of the vena cava (which *Lechner* (18) found in 42% of cases) increases the risk of Lipiodol passage towards the portal vein, it seem to be solely an adjuvant factor. Discovery of a hepatic oil embolism during lymphography always warrants attention since even in those cases where lymph nodes are not opacified (a highly rare occurrence) such a discovery is always associated with a nodal affection. Indeed, this phenomenon was never observed in connection with a normal lymphography.

References

- 1 *Abbes, M.*: La visualisation des anastomoses lymphatico-veineuses par la lymphographie. A propos de 12 observations. *Presse Med* 74 (1966) 1379-1384
- 2 *Akisada, M., A. Tasaka, S. Lin, J. Hachiya.*: Three cases of hepatic oil embolism. Its clinical aspects and pathogenesis. *Nippon Acta Radiol* 28 (1969) 1656-1671
- 3 *Arvay, N., J.D. Picard.*: La lymphographie. Etude radiologique et clinique des voies lymphatiques normales et pathologiques. *Masson Ed, Paris* (1963), pp 187-191
- 4 *Besson, J.J., G. Delaneau.*: Hepatographie lipiodolée au cours d'une lymphographie. *J Radiol* 53 (1972) 25-28
- 5 *Bodie, J.F., D.S. Linton.*: Hepatic oil embolization as a complication of lymphangiography. *Radiology* 99 (1971) 317-318
- 6 *Chassard, J.L., A. Jenn, J.P. Gerard et al.*: Les complications graves de la lymphographie au Lipiodol ultra-fluide. A propos de 9 observations. *Ann Radiol* 20 (1977) 193-201
- 7 *Chavez, C.M., L.G. Berrong, C.G. Evers.*: Hepatic oil embolism lymphangiography. Role of the systemicportal lymphaticovenous anastomosis. *Am J Surg* 110 (1965) 456-460
- 8 *Chavez, C.M., J.D. Picard, D. Davis.*: Liver opacification following lymphangiography: pathogenesis and clinical significance. *Surgery* 63 (1968) 564 to 570
- 9 *Chudacek, Z., M. Halouskova.*: Lymphovenöse Verbindungen zwischen den Lymphgefäßen des Beckens und dem Pfortadersystem. *Fortsch Röntgenstr* 105 (1966) 227-229
- 10 *Delavault, G., C. Gasquet, X. Morand et al.*: Les hépatographies au cours des lymphographies. A propos d'un cas. *J Radiol* 55 (1974) 916
- 11 *Desprez-Curely, J.P., V. Bismuth, A. Laugier, J. Descamps.*: Accidents et incidents de la lymphographie. *Ann Radiol* 5 (1962) 577-588
- 12 *Georgi, M.*: Kontrastanfärbung der Leber. Eine seltene Komplikation während der Lymphographie. *Fortsch Röntgenstr* 106 (1967) 853-858
- 13 *Gilly, G., V. Taenzer.*: Kontrastmittelspeicherung in der Leber nach Lymphographie. *Fortsch Röntgenstr* 106 (1967) 888-890
- 14 *Gray, S.H., R.A. Cohen.*: Lymphatico venous anastomosis involving the portal system. Report of a case with metastatic carcinoma of vagina. *Am Surg* 32 (1966) 410-417
- 15 *Hecht, H., W. Berdon, D. Baker.*: Hepatic oil embolization following lymphangiography in a child with neuroblastoma. *AJR* 104 (1968) 860 to 864
- 16 *Herman, P.G., D.L. Benninghoff, S. Schwartz.*: A physiologic approach to lymph flow in lymphography. *AJR* 91 (1964) 1207-1215
- 17 *Koehler, P.R.*: Complications of lymphography. *Lymphography* 1 (1968) 117-120
- 18 *Lechner, G., P. Riedl, O. Zechner.*: Zum Mechanismus der Kontrastmitteldarstellung der Leber nach Lymphographie. *Fortsch Röntgenstr* 125 (1976) 355-357
- 19 *Leger, L., R. Buchet, C. Bitry-Boely, M. Pre-mont.*: Introduction à l'étude de la lymphographie hépatique. *Presse Med.* 69 (1961) 1981 to 1982
- 20 *Markovits, P., J. Grellet, R. Blache.*: A propos des hépatographies observées au cours des lymphographies. *Ann Radiol* 8 (1965) 535-546
- 21 *Ngan, H.*: Hepatic oil embolism following lymphography. *Br J Radiol* 51 (1978) 788-792
- 22 *Perez-Tamayo, R., J.R. Thorbury, R.J. Atkinson.*: „Second-look“ lymphography. *AJR* 90 (1963) 1078-1086
- 23 *Picard, J.D., J. Grellet.*: Les lymphatiques in Radiologie cardio-vasculaire. *Masson Ed, Paris* (1980) pp 646-650
- 24 *Pujol, H., J.L. Lamarque, H. Balmes.*: Hépatomégalie au Lipiodol ultra-fluide au cours d'une lymphographie. *J Radiol* 45 (1964) 366-367
- 25 *Retik, A.B., A.D. Perlmutter, J.H. Harrison.*: Communication between lymphatics and veins involving the portal circulation. *Am J Surg* 109 (1965) 201-205
- 26 *Schulman, A., S. Fataar, I. Tidbury.*: Lymphographic opacification of liver and spleen. *Br J Radiol* 51 (1978) 389-391
- 27 *Wallace, S., L. Jackson, G.D. Dodd, R.R. Greening.*: Lymphatic dynamics in certain abnormal states. *AJR* 91 (1964) 1187-1206