

## Ultrastructural and Electrophysiologic Changes of Experimental Acute Cardiac Lymphostasis

P. Gloviczki, M.D., F. Solti, M.D., L. Szlavay, M.D., and H. Jellinek, M.D.

Clinic of Cardiovascular Surgery and the Second Department of Pathology, Semmelweis Medical University School, Budapest, Hungary

### Summary

Experimental impairment of cardiac lymph flow in dogs produced histologic and electrophysiologic changes in the heart. Interstitial edema, lipid swelling of myofibrils, dilatation of lymph vessels, and fibrinoid degeneration of small coronary arteries occurred in and near the sinus node and the atrioventricular conduction system. On electrical stimulation of the heart, significant shortening of the atrial and ventricular effective refractory periods, increases in the sinus node recovery time and in the atrioventricular conduction time, and ventricular extrasystoles and ventricular fibrillation were observed. Many of these EKG changes are similar to those observed in sick sinus syndrome in man. An attempt was made to create dynamic lymphatic insufficiency by rapid electrical stimulation of the heart. EKG abnormalities observed in these cases could be prevented by intravenous injection of calcium dobesilate.

Although it is over 300 years since *Rudbeck* described the subpericardial lymphatics (1), the functions of the cardiac lymphatic system are not yet fully understood. Experimental interruption of cardiac lymph flow by ligation of the lymphatics and the lymph nodes of the heart has resulted in disorder of the cardiac microcirculation accompanied by interstitial edema, myocardial damage, and electrocardiographic changes such as transient bradycardia, extrasystoles, and anomalies of repolarization — the condition known as acute lymphostatic cardiomyopathy (2-5). Whether however, the cardiac arrhythmia is in fact caused by the mechanical impairment to cardiac lymph flow remains to be demonstrated.

In previous experiments, *Solti et al.* (5) reported on a hypothesis that rapid electrical

stimulation of the heart might cause a dynamic insufficiency of the cardiac lymph system, since ultrastructural studies in these animals, besides nonspecific focal myocardial necrosis and interstitial edema, revealed dilated lymphatics, as well. Though this remains a hypothesis and repeated studies must be performed to confirm these findings, the authors also observed EKG changes similar to those found in acute cardiac lymphostasis.

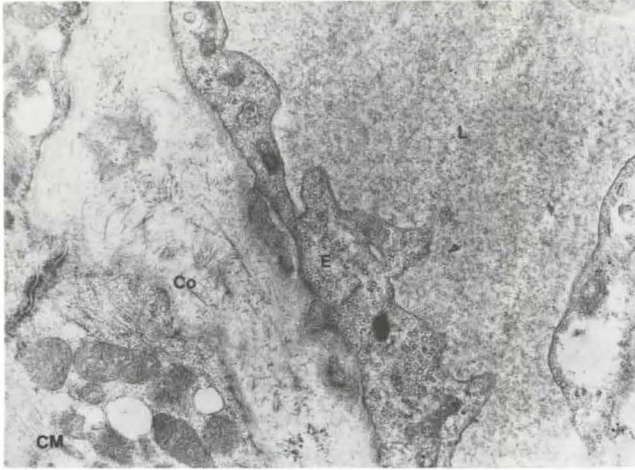
The purpose of the research now reported was to identify, in animal experiments, the morbid histologic changes associated with lymphostatic cardiomyopathy and the effects of these changes on the formation and conduction of the cardiac impulse and the pacemaker function of the sinus node.

To prevent cardiac arrhythmias observed after rapid electrical stimulation of the heart, a preliminary study of the effect of calcium dobesilate<sup>1</sup> was also performed. This drug is claimed to improve microcirculation, decreasing interstitial edema (7, 8).

### Methods

In 26 mongrel dogs of both sexes, anesthetized with intravenous pentobarbital and ventilated mechanically with room air by a Harvard respirator and a cuffed endotracheal tube, a thoracotomy was performed via the fourth left intercostal space. The heart was stimulated electrically by two unipolar electrodes attached to the epicardial surfaces of the right atrium and right ventricle using a Medtronic 5837 impulse generator and a Medtronic 5325 programmable

<sup>1</sup> DOXIUM®, OM Laboratories, Geneva, Switzerland



**Fig. 1** Dog heart 24 hours after ligation of cardiac lymph nodes. Lymph vessels dilated and their endothelial cells edematous. Despite edema of the subendothelial space, collagen fibers are still visible. L = lumen of lymph vessel. E = endothelium of lymph vessel. CM = cardiac muscle. Co = collagen fibers (x 24 000)

electrical stimulator. Patent Blue dye was injected subepicardially in multiple sites to visualize the major lymph vessels and lymph nodes of the heart. The cardiac and pretracheal nodes were ligated several times after meticulous dissection together with all of the visible afferent and efferent lymph ducts. Lymph drainage towards the right lymphatic duct was especially carefully followed and ligated. The left thoracic duct was also ligated at the upper thorax.

The sinus-node recovery time (SNRT) was determined by rapid electrical stimulation of the right atrium. For corrector measurements of sinus node pacemaker function, the corrected sinus-node recovery time (CSNRT), that is, the SNRT – the sinus cycle length (9), was also calculated.

The arrhythmic property of the heart was investigated by measuring the atrial and ventricular effective refractory periods (AERP and VERP) by programmable coupled stimulation.

The atrioventricular and intraventricular conduction times were monitored by repeated electrocardiographic measurement of the P-Q distance and the length of the QRS complex. To detect latent conduction disorder, rapid electrical stimulation (160 to 240 per minute) of the right atrium was also performed.

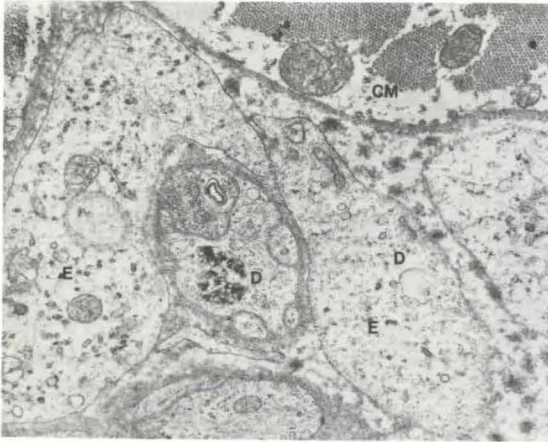
The electrical stimulation thresholds of the right atrium and right ventricle were monitored at regular intervals by means of the impulse generator.

All electrophysiologic investigations were done before and immediately after lymph node ligation and at a second thoracotomy performed between 3 and 6 days after the first. The animals were then killed and specimens of cardiac tissue taken for examination by light and electron microscopy.

Cardiac lymph node ligation was done in an additional six dogs not submitted to electrophysiologic studies. Cardiac tissue for histologic examination was taken from all these animals before ligation, from two of them immediately after ligation, from two 24 hours after ligation and from two 48 hours after ligation.

Cardiac overdrive to a heart rate of over 180 beats per minute was induced by electrical stimulation in six mongrel dogs, three of which had received 50 to 75 mg/kg of calcium dobesilate per kg by intravenous injection in one bolus. Electrocardiographic records were made 4 hours after in all of the animals.

Statistical analysis of the experimental data was by the Student's one-sample *t* test.



**Fig. 2** Dog heart 24 hours after cardiac lymph node ligation. Fibrinoid degeneration of a small coronary artery, narrowing of its lumen, and edematous swelling of its endothelial cells. E = endothelial cells, CM = cardiac muscle, D = degeneration (x 24 000)

## Results

### Histologic studies

Changes in the myocardium and in the small coronary arteries after ligation of the cardiac lymph nodes were seen under light and electron microscopy. Interstitial edema and dilatation of lymph vessels accompanied by edema of their lining endothelial cells, fibrinoid degeneration in the wall of small coronary arteries, although visible immediately after ligation, were most striking 24 hours later. Swelling of myofibrils with lipid droplets attached to the mitochondria was noted in specimens taken 24 to 48 hours after the creation of lymphostasis. These changes were present in the sinus node, the atrioventricular conduction system, and adjacent areas (Figs. 1–4).

### Electrophysiologic studies

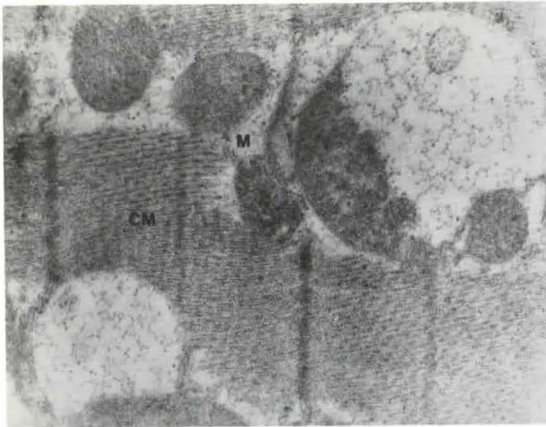
Significant shortening of the AERP and the VERP (Fig. 5) indicated increase in the irritability and the arrhythmic property of the atria and ventricles and prolongation of the stimulation period of the heart. There was significant prolongation of the CSNRT (by almost 30%). Prolongation of the atrioventricular conduction time (P–Q) suggested slowing of impulse conduction and elevation of the heart's electrical stimulus threshold. The appearance of sinoatrial block and latent atrioventricular block (Fig. 6) indicated dis-

ordered conduction, and the development of extrasystoles indicated the arrhythmic property of the heart (Fig. 7). The wandering of the P-wave and the development of escape rhythm (junctional coronary sinus rhythm) pointed to disturbance in impulse formation at the sinus node.

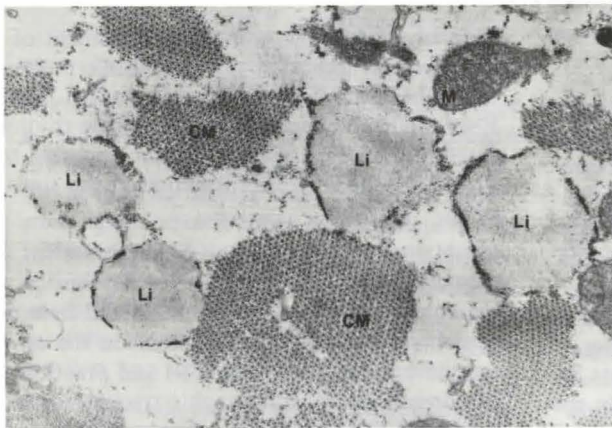
Rapid electrical stimulation of the heart for 4 hours showed abnormalities of rhythm including bursts of tachyarrhythmia and heterotopic and ventricular extrasystoles in the untreated animals (Figs. 8 and 9) and practically normal electrocardiographic tracings in the animals that had received calcium dobesilate (Fig. 10).

### Discussion

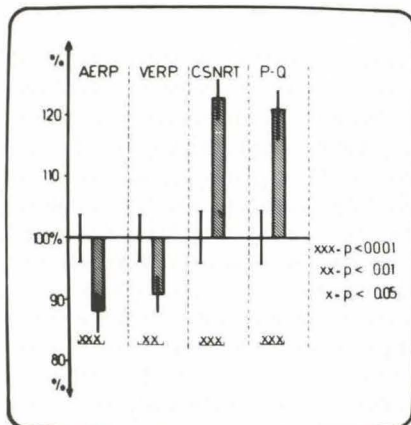
Experimental interruption of the cardiac lymph vessels caused much controversy in recent years, especially because of differences in opinions concerning the drainage pathways of the cardiac lymph system. The right lymphatic duct is the main collecting channel of the canine cardiac lymph, however, connecting channels towards the thoracic duct were described, as well (10). Both left and right coronary lymphatics should be interrupted and the cardiac, tracheobronchial and posterior mediastinal lymph nodes should be ligated several times. Lymph drainage from the sinoatrial node leads partly to



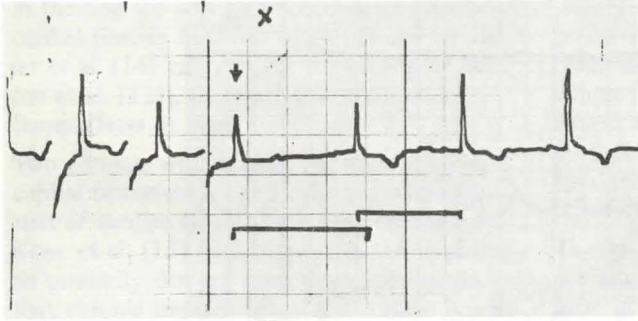
**Fig. 3** Dog heart 48 hours after cardiac lymph node ligation. Edema between the cardiac myofibrils. CM = cardiac muscle. M = mitochondrion (x 36 000)



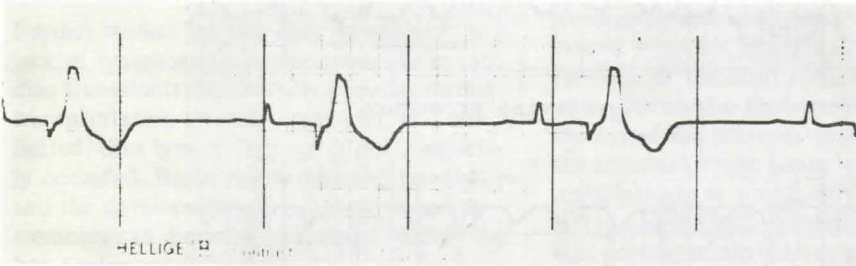
**Fig. 4** Dog heart 48 hours after cardiac lymph node ligation. Lipid droplets next to myofibrils. CM = cardiac muscle. M = mitochondrion. Li = lipid droplets (x 36 000)




**Fig. 5** Effect of ligation of cardiac lymph nodes in dog on the A.E.R.P. (atrial effective refractory period), V.E.R.P. (ventricular effective refractory period), C.S.N.R.T. (corrected sinus-node recovery time), and P-Q (atrioventricular conduction time). Changes are expressed as percentages of the base value. Note shortening of A.E.R.P. and V.E.R.P., prolongation (by almost 30%) of C.S.N.R.T., and prolongation of the P-Q interval



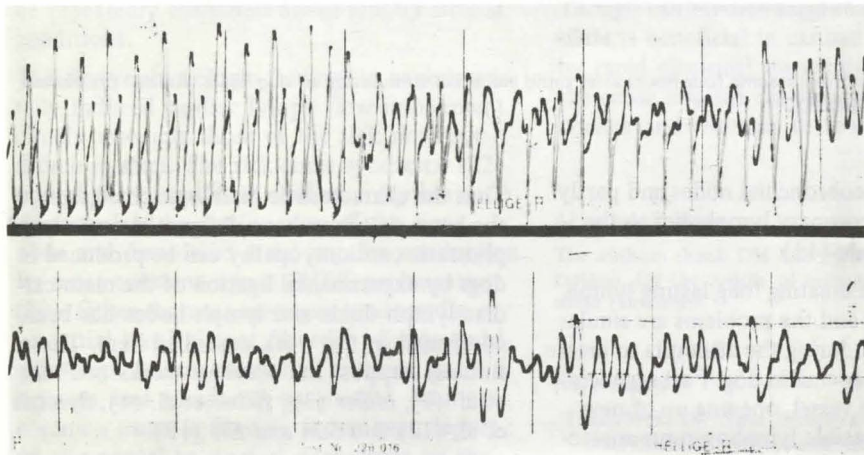
**Fig. 6** Increase in sinus-node recovery time after ligation of cardiac lymph nodes in dog. At the conclusion of electrical stimulation of the heart (↓) the first P wave appears late. Einthoven bipolar extremity lead II. Paper speed = 25mm per second



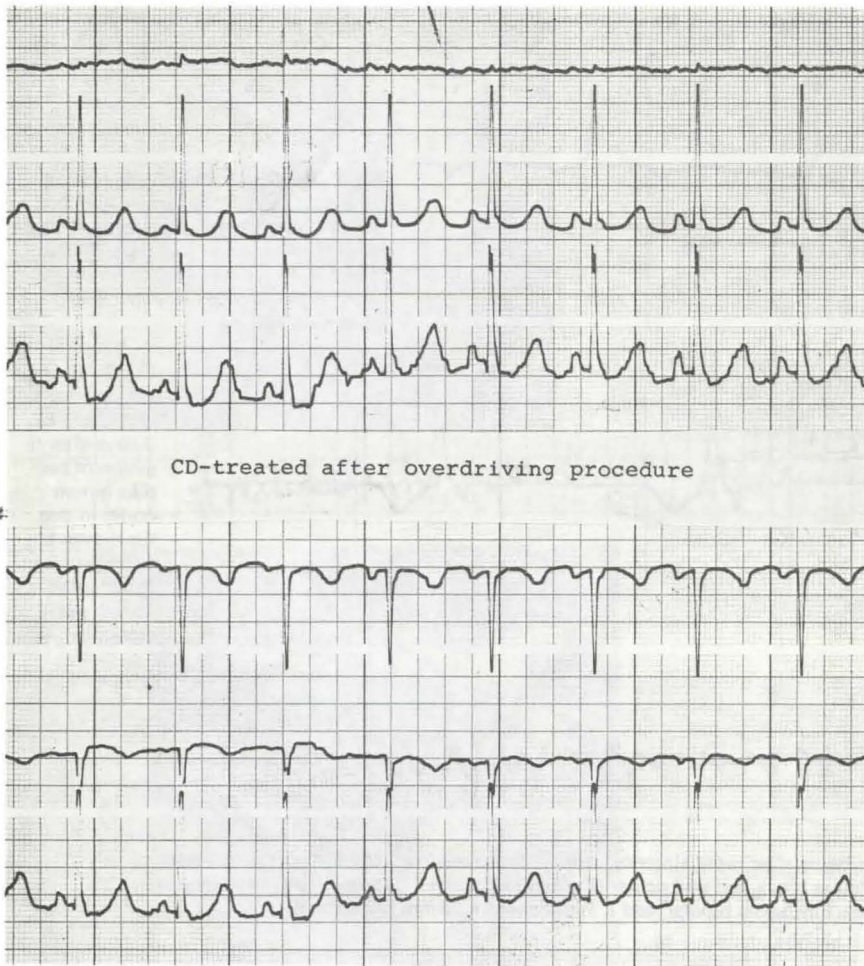
**Fig. 7** Bigeminal ventricular extrasystoles 3 days after ligation of cardiac lymph nodes in dog. Einthoven bipolar lead II. Paper speed = 25mm per second



**Fig. 8** Tracing four hours after rapid electrical stimulation (overdrive) of dog heart. Untreated animal. Atrioventricular block and ventricular fibrillation. External pacing (↓) was necessary to restore sinus rhythm. Einthoven bipolar lead I. Paper speed = 25mm per second



**Fig. 9** Tracing four hours after rapid electrical stimulation of dog heart. Untreated animal. Ventricular extrasystoles and ventricular fibrillation. Einthoven bipolar lead I. Paper speed = 25mm per second



**Fig. 10** Practically normal tracing four hours after rapid electrical stimulation of dog heart. Animal pretreated with calcium dobesilate (CD)

the inferior tracheobronchial nodes and partly through the left coronary lymphatics to the cardiac lymph node (11).

The difficulties in creating long-lasting lymph stasis are obvious and the problems are similar to those observed during the attempts to create extremital lymphedema in dog. Fast regeneration of the lymph vessel, opening up of new collaterals and possible lymphovenous anastomoses successfully contribute to diminish lymph stasis.

That the characteristic histologic changes in the heart that have been designated acute lymphostatic cardiomyopathy can be produced in dogs by experimental ligation of the main cardiac lymph ducts and lymph nodes has been confirmed in the work described here. These findings support the previous works of *Foldi et al.* (2), *Miller* (3), *Kline et al.* (4), *Symbas et al.* (12) and *Sun and Lie* (13).

Although the morbid histologic effects of chronic obstruction to cardiac lymph flow

in the dog are also well documented [endocardial fibrosis by *Kline* et al. (4) and by *Miller* et al. (14) and valvular thickening by *Symbas* et al. (12)], there are few accounts of these effects in man.

Two patients with marked ventricular endocardial fibroelastosis and evidence of obstruction of cardiac lymphatic vessels reported by *Kline* et al. (15) lend support to the hypothesis primarily derived from dog experiments, that chronic impairment of the cardiac lymph flow leads to endocardial fibroelastosis.

Further studies are necessary to explain the lack of lymphostatic cardiomyopathy in cardiac transplants; however, lymphatics during transplantation are only transected and not ligated, thus lymph drainage is not completely occluded. Rapid regeneration of lymphatics and the development of lymphovenous anastomoses can diminish lymphatic stasis in the late postoperative period.

The electrophysiologic changes found in acute cardiac lymphostasis in our experiments point to the close relationship between the cardiac lymph system and the conduction system of the heart (16–18). EKG changes in acute cardiac lymphedema were described by *Földi* et al. (2), *Rusznayk* et al. (19) and *Jacobs* et al. (20), as well. However, we agree with *Miller* (21) that canine EKG changes should be interpreted with much caution and results should be repeatedly evaluated under strictly similar conditions.

The electrophysiologic findings in experimentally induced cardiac lymph flow impairment closely resemble those of the sick sinus syndrome in man. The sick sinus syndrome (22), one of the commonest cardiac arrhythmias, is characterized by dysfunction of the sinus node and disordered atrial impulse conduction. Its most constant sign is SNRT prolongation (22). Other features are sinus bradycardia, sinoatrial block, latent disorder of atrioventricular conduction, premature systoles, extrasystoles, and wandering pacemaker. Its most common cause is fibrosis. It has been reported as a sequel to surgical procedures on the heart (5, 23–26) in which the risk of trauma and obstruction to lymph vessels is also

evident. These vessels may be occluded by ligation and interstitial edema resulting from tissue injury at perfusion may interfere with lymph flow. Sick sinus syndrome with prolonged SNRT appeared during the immediate postoperative period in all of the 26 patients operated on by *Solti* et al. (26) for atrial septal defect, and persisted in 10 of the patients.

Though there is no evidence that lymphatic occlusion alone causes sick sinus syndrome in man, in the majority of reported cases the sinus node artery was intact in iatrogenic sick sinus syndrome and edema and/or hematoma caused reversible changes in the pacemaker function of the heart (26). *Rossi* (27) reported a patient who died from atrioventricular block and the necropsy revealed sclerosis of the atrioventricular node; lymph vessels showing dilatation or proliferative lymphangitis were observed within the fibrous strands. It was postulated that the cause of the damage to the conducting system and of the heart block in this case was chronic proliferative lymphangitis.

Further studies are necessary to prove the role and importance of the cardiac lymph system in the electrophysiologic changes observed by *Solti* et al. (6) after rapid electrical stimulation of the heart. It is noteworthy that in our preliminary study arrhythmic changes could be prevented by calcium dobesilate.

Though our studies suggest that calcium dobesilate is beneficial in cardiac arrhythmias caused by rapid electrical stimulation of the heart, the cause and the mechanism of action is still unclear and warrants further investigation.

#### Acknowledgement

The authors thank OM Laboratories, Geneva, Switzerland, for the supply of samples of calcium dobesilate (Doxium).

#### References

- 1 *Rudbeck, O.*: Nova exercitatio anatomica, exhibens ductus hepaticos aquosos et vasa glandularum serosa, nunc primum inventa, aenisque figuris delineata. Vasteras, 1653, E. Lauringerus. (English translation in Bull Hist Med 11 (1942) 304)

- 2 *Földi, M., G. Romhányi, I. Ruzsnyák, F. Solti, G. Szabó*: Über die Insuffizienz der Lymphströmung im Herzen. *Acta Med. Acad. Sci. Hung.* 6 (1954)
- 3 *Miller, A.J.*: The lymphatics of the heart. *Arch. Int. Med.* 112 (1963) 501
- 4 *Kline I.K., A.J. Miller, I.N. Katz*: Cardiac lymph flow impairment and myocardial fibrosis. *Arch. Pathol. (Chicago)* 75 (1963) 424
- 5 *Solti, F., M. Iskum, J. Nagy, A. Hartai, B. Veress, I. Hüttner, T. Kerényi T.*: The effect of mechanical lymph flow insufficiency on cardiac muscle necrosis as a result of coronary ligation. *Cor Vasa* 10 (1968) 68
- 6 *Solti, F., L. Szlavy, P. Gloviczki, H. Jellinek*: The development of cardiac lymphostasis after long lasting tachycardia. Abstracts, 8th International Congress of Lymphology. Belanger, R., J.W. Davidson (editors), Sept 20–25, 1981, Montreal, Canada, p. 204
- 7 *Kappert, A.*: Zur medikamentösen Beeinflussung gestörter Kapillarfunktionen. *Zeitschrift für Therapie* 2 (1974) 71
- 8 *Soltész, L., A. Kádár, P. Gloviczki, L. Tóth*: New possibilities in the treatment of chronic venous insufficiency. Clinical and ultrastructural studies with calcium dobesilate (Doxium). Proceedings of the VIth World Congress of Phlebology, Oct. 10–15, 1977, Buenos Aires, Argentina, p. 29
- 9 *Narula, O.S., P. Samet, R.P. Javier*: Significance of the sinus-node recovery time. *Circulation* 45 (1972) 140
- 10 *Ullal S.R., T.H. Kluge, W.J. Kerth, F. Gerbode*: Anatomical studies on lymph drainage of the heart in dogs. *Ann. Surg.* 175 (1972) 305
- 11 *Eliska, O., M. Elisková*: Lymph drainage of sinoatrial node in man and dog. *Acta Anat.* 96 (1976) 418
- 12 *Symbas P.N., R.C. Schlant, M.B. Gravanis*: Total interruption of the cardiac lymphatics: functional and pathologic effects. *Surg. Forum* 19 (1968) 169
- 13 *Sun S.C., J.T. Lie*: Cardiac lymphatic obstruction. Ultrastructure of acute-phase myocardial injury in dogs. *Mayo Clin. Proc.* 52 (1977) 785
- 14 *Miller, A.J., R. Pick, I.N. Katz*: Ventricular and myocardial changes after impairment of cardiac lymph flow in dogs. *Br. Heart J.* 25 (1963) 182
- 15 *Kline, I.K., A.J. Miller, R. Pick, I.N. Katz*: The relationship between human endocardial fibroelastosis and obstruction of the cardiac lymphatics. *Circulation* 30 (1964) 728
- 16 *Eberth C.J., A. Belajeff*: Über die Lymphgefäße des Herzens. *Virchows Arch. Pathol. Anat.* 37 (1966) 124
- 17 *Curran, E.J.*: A constant bursa in relation with the bundle of His; with studies of the auricular connections of the bundle. *Anat. Rec.* 3 (1909) 618
- 18 *Uhley, H.N., S.E. Leeds, M.A. Sung*: The subendocardial lymphatics of the canine heart. A possible role of the lymphatics in the genesis of conduction disturbances and arrhythmias. *Am. J. Cardiol.* 29 (1972) 367
- 19 *Ruzsnyák, I., M. Földi, G. Szabó*: Lymphatics and lymph circulation. Pergamon Press, N.Y. 1961
- 20 *Jacobs, G.M., F. Kleinschmidt, L. Benesch, W. Lenz, G. Uhlig, F. Huth*: Tierexperimentelle Untersuchungen des kardialen Lymphgefäßsystems. *Thoraxchirurgie* 24 (1976) 453
- 21 *Miller, J.*: Lymphatics of the Heart. New York, Raven Press (1982) p. 271
- 22 *Ferrer, M.I.*: The sick sinus syndrome in atrial disease. *JAMA* 206 (1968) 645
- 23 *Tung, K.S.K., T.N. James, D.B. Effler, L.J. McCormack*: Injury of the sinus node in open-heart operations. *J. Thorac. Cardiovasc. Surg.* 53 (1967) 814
- 24 *Brouillard, R.B., J.L. Bedynek, M.D. Cheitlin, U. D'Ambrosio*: Tachybrady syndrome following open heart surgery. *Chest* 63 (1973) 442
- 25 *Solti, F., Z. Szabó, E. Czakó, Rényi-Vámos, T. Gyöngy, E. Moravcsik*: A "sick sinus syndrome" (beteg sinus csomó) tünetei, elkülönítő körjelzése és terápiája. *Orv. Hetil.* 117 (1976) 1394
- 26 *Solti, F., Z. Szabó, E. Bodor, F. Rényi-Vámos, Jr.*: Changes in the pacemaker function of the sinus node after closure of atrial septal defect. Temporary and stable iatrogenic sick sinus syndrome. *Cor Vasa* 21 (1979) 242
- 27 *Rossi, L.*: Case of cardiac lymphangitis with atrioventricular block. *Br. Med. J.* 2 (1965) 32

*Peter Gloviczki, M.D., Mayo Clinic, Rochester, Minnesota 55905, USA*