

## Immunoarchitecture of the Human Spleen

Th.M. Grogan, M.D., C.S. Jolley, M.T. (ASCP), C.S. Rangel, H.T.L. (ASCP)

Department of Pathology, University of Arizona, Arizona Health Sciences Center, Tucson, Arizona

### Summary

New immunochemical staining techniques reveal key topographic aspects of splenic immune function. Distinct compartmentalization of B and T cells and lymphocytic subtypes within the white and red pulp of the human spleen provide a morphologic basis for division of labor in the immune response.

### Introduction

The human spleen functions as an immunologic filter of the bloodstream. Although its importance in immune function has long been recognized and measured, details of splenic immunoreactivity remain elusive in part because topographic analysis of splenic immunologic features has heretofore not been possible. Previously, red and white pulp cells were admixed in cell suspension assays that disrupted architecture. The advent of tissue section immunologic assessment with hybridoma-derived monoclonal antibodies, a biotin-avidin conjugating system and peroxidase labelling, now makes possible topographic study of immunologic function and delineation of the immunoarchitecture of lymphoreticular organs (1, 2). The present study applies these newer techniques and reagents to examine B and T lymphocytes and histiocytes within the splenic white and red pulp to determine if immunologic compartmentalization occurs as in lymph nodes and the thymus.

### Methods

Six spleens were removed during staging laparotomies for lymphoma. In each instance neo-

plastic involvement of the spleen was absent by both gross and microscopic inspection indicating normal immunoreactive spleens, although we cannot exclude minor pathologic alterations. Resected specimens were snap frozen in OCT compound (Ames Company Division of Miles Laboratory, Elkhart, Indiana) and stored at  $-70^{\circ}\text{C}$ .

Tissue section analysis was performed using biotin-avidin conjugation and horseradish peroxidase labelling with diaminobenzidine tetrahydrochloride as the detection agent (1, 3). Briefly, cryostat sections of splenic tissues were fixed in acetone at  $4^{\circ}\text{C}$  for 10 minutes, air-dried at room temperature, and then hydrated in PBS at pH 7.4 for 10 minutes. Following this wash, mouse monoclonal antibody to human cell surface antigen was applied (Table).

After a second PBS wash, a second stage reagent, biotin conjugated  $\text{F(ab')}_2$  goat anti-mouse IgG (Tago, Incorporated) was added followed by 15 minute incubation and a 3 minute PBS wash. The cryostat section was next incubated with avidin D conjugated with horseradish peroxidase (Vector Laboratories, Inc.). After another 15 minute incubation period, the section was further washed twice with PBS. Next, each section was incubated with diaminobenzidine tetrahydrochloride (DAB) solution consisting of three mg of DAB per ml of PBS along with 0.010 ml of 30%  $\text{H}_2\text{O}_2$ . After the 5 minute incubation in DAB solution, sections were washed in PBS for 3 minutes and rinsed in distilled water. Slides were incubated in a copper sulfate solution

**Table** Hybridoma-derived monoclonal antibodies\*

Monoclonal antibody	Hybridoma clone	Specificity	Abbreviation	Concentration
Leu 1	L17F12	Mature T-cells	PAN-T	2 µg/ml
Leu 2a	SK1	Suppressor-cytotoxic T-cells	Ts/c	2 µg/ml
Leu 3a	SK3	Helper-inducer-T cells	Th	2 µg/ml
Leu 5	ATM 1.1	Sheep RBC Receptor-bearing (E <sub>R</sub> ) T-cells	E <sub>R</sub>	2 µg/ml
Leu 7	HNK-1	Natural killer cells	NK	2 µg/ml
Anti-HLA-DR	L243	HLA-DR antigen β-lymphocytes, monocytes/histocytes, activated T-cells	Ia	1 µg/ml
Anti-kappa	163-42	kappa-immunoglobulin light chains, cytoplasmic and surface	IgK	0.5 µg/ml
Anti-lambda	1-155-2	lambda-immunoglobulin light chains, cytoplasmic and surface	Igλ	0.5 µg/ml

\*Obtained from Becton-Dickinson, Oxnard, Calif.

for 5 minutes, rinsed with PBS, dipped in distilled water and counter-stained with methylene blue for 5 minutes, followed by a brief 100% ethanol dip, two changes of xylene and coverslipped with permount.

Alpha-naphthyl butyrate esterase activity indicative of the presence of monocytic/histiocytic cells was detected on cryostat sections as previously described (4).

### Results and Discussion

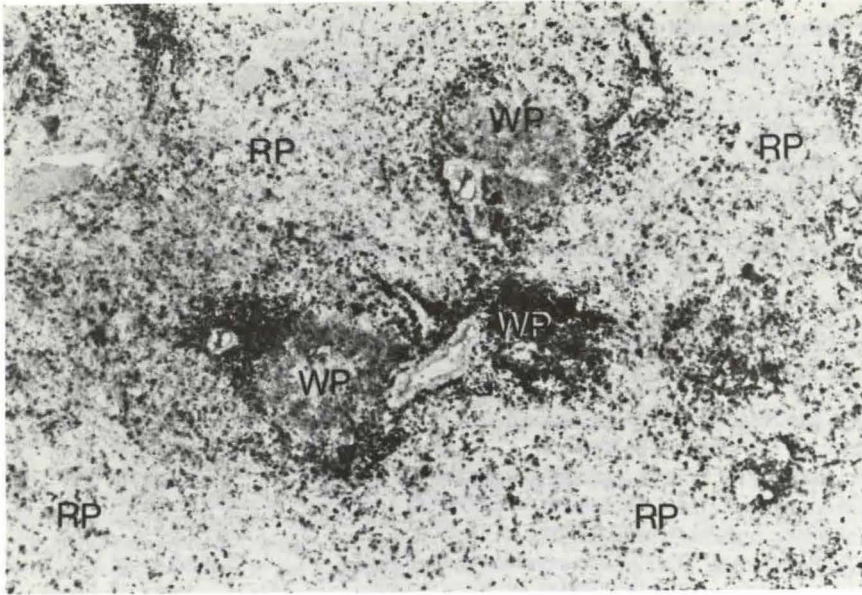
As displayed in the figures, distinct antigenic staining patterns are clearly identifiable in the splenic tissue sections using monoclonal antibodies with the biotin-avidin horseradish peroxidase technique. Our findings indicate that compartmentalization of the B and T cells occurs within the white pulp. Although B and T cell areas are largely separate, some overlap of these zones exists with spillover of B and T cells into the red pulp.

#### A Localization of mature T cells:

Figures 1 and 2 demonstrate the distribution of mature T cells. Figure 1 emphasizes at low

magnification, the preponderance of mature T cells in the white pulp and the spillover into the red pulp. At higher magnification in Fig. 2, T cells are identified by a darkly stained periphery in contrast to T antigen negative cells without peripheral surface staining. A light counterstain of methylene blue indicates in gray tones the non-staining cellular components seen predominantly in the germinal center and in the red pulp. As indicated, an occasional extremely dark irregular cell with natural peroxidase activity is visible particularly in the red pulp. Figure 3 delineates graphically the microanatomic features of this same cryostat section of splenic white pulp depicting the anatomic terms traditionally applied to the compartments of the white pulp (2, 5). Figs. 1-3 considered together illustrate the utility of the tissue sections mode of immunologic assessment and the sharp details of immunarchitecture discernible by this approach.

The staining pattern in Figures 1 and 2 demonstrate a predominance of mature dark staining T-cells in the periarteriolar lymphoid sheath (PALS). This pattern signifies that mature T cells are largely compartmentalized in the PALS.



**Fig. 1** Localization of mature T cells using Leu 1 antibody. Darkly stained mature T cells predominate in the white pulp (WP) and spill over into the red pulp (RP). Magnification 25 x

They also appear in the adjacent marginal zone (MZ) and mantle of the germinal center. A few are found scattered within the germinal center and the red pulp. Thus, while substantial compartmentalization of mature, splenic T cells may exist in the PALS and MZ zones, there is intimate contact of T cells with B cells in the germinal centers and with macrophages in the red pulp.

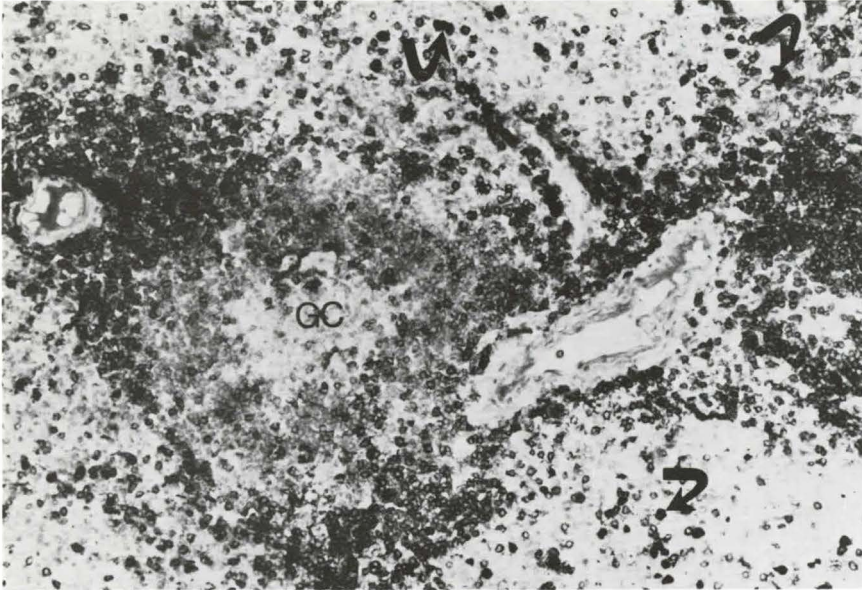
Mitoses identified in the PALS region of most spleens examined indicate T cell proliferation in this zone. Previously T cells in the PALS were thought to represent T cells migrating from the bloodstream and "homing" to the spleen (2, 5). The observed mitoses, however, suggest that T cell clonal expansion may also occur in this region substantiating local proliferation as well as systemic migration.

In all six spleens the T cells in the marginal zone do not display mitoses. Mature T cells in this region presumably migrate from the PALS zones of clonal expansion or enter directly from the circulation. The prominence

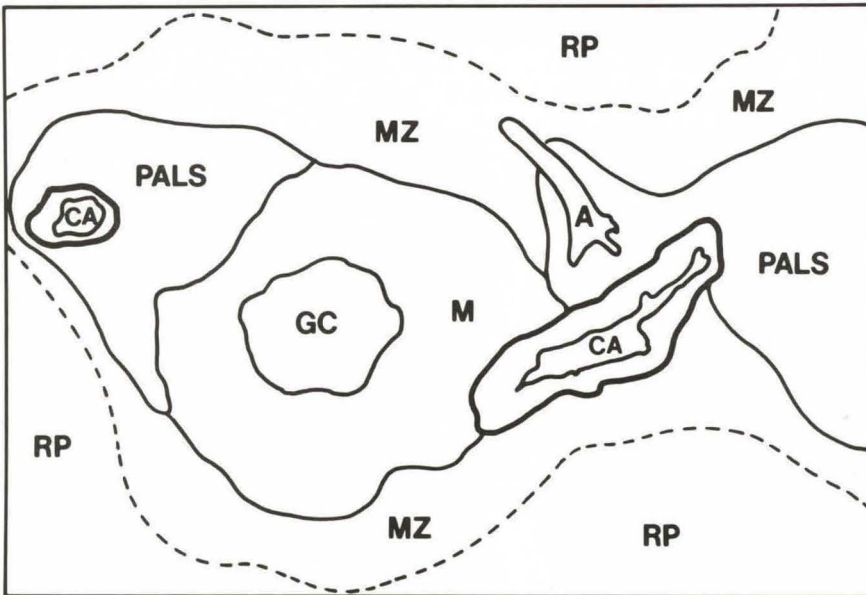
of mature T cells in the marginal zone is of interest because many splenic arterioles seem to terminate here (Figs. 2 and 3), and this is also the site where antigen trapping takes place (2, 5, 6). Some evidence suggests that antigen does not remain in the marginal zone but is transferred to the germinal center where its presence in dendritic reticulum cells stimulates B cell development (5-7). It is possible that some antigen is transported to the PALS region to stimulate T cell clonal expansion. Although this immunochemical technique cannot precisely delineate the sequence of events in antigen trapping and subsequent T & B cell clonal expansion, further application to in vivo animal studies may pinpoint the sequential white pulp response (lymphocytopoiesis).

#### *B. Localization of T versus B cells:*

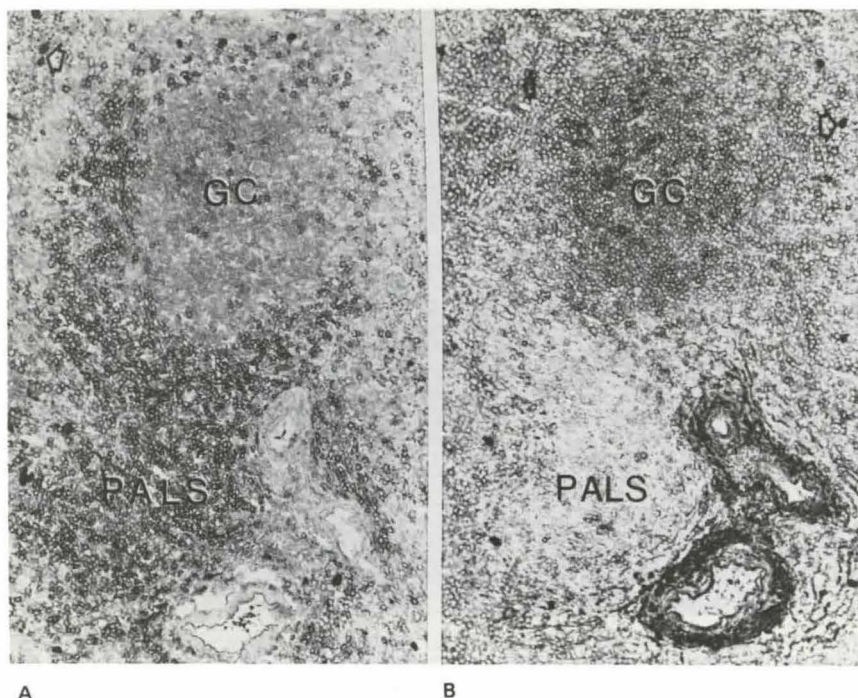
Using the tissue section method of immunologic assessment, sections can be examined for T & B cell antigens sequentially. The staining pattern in Fig. 4 demonstrates T & B compartment-



**Fig. 2** Localization of mature T cells using Leu 1 antibody. Darkly stained T cells predominate in the periarteriolar regions and are scarce in the germinal center (GC). The arrows indicate dark irregular cells with natural peroxidase activity. Magnification 250 x



**Fig. 3** Microanatomic compartments of the white pulp. The anatomic features of the white pulp in Fig. 2 are delineated. PALS = periarteriolar lymphoid sheath; CA = central arteriole; GC = germinal center; MZ = marginal zone; M = mantle; A = arteriole; RP = red pulp

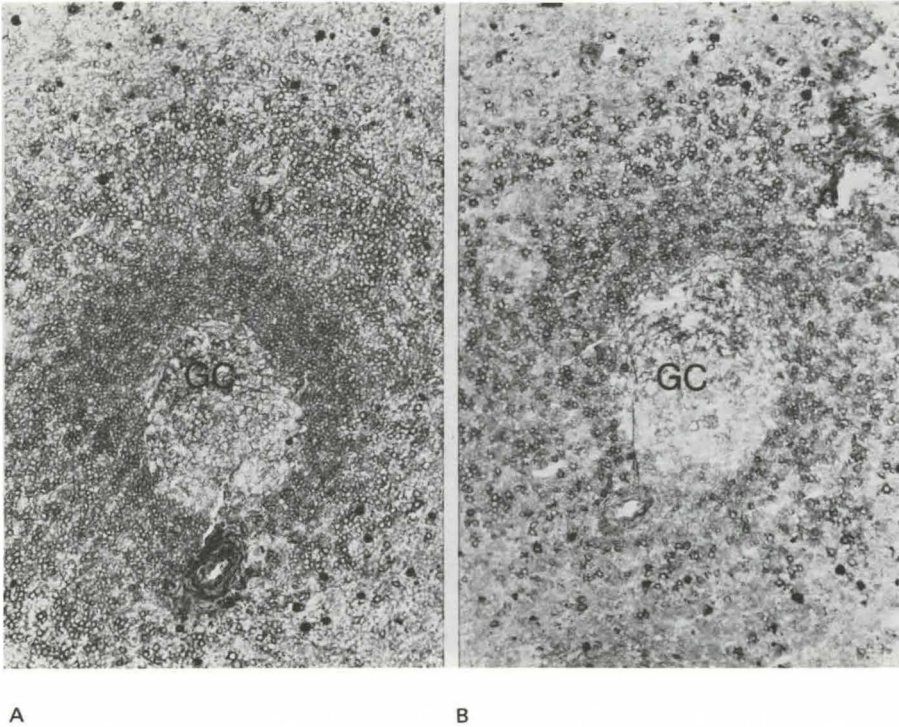


**Fig. 4** T versus B cells: (A (left): Localization of T cells with sheep red blood cell receptor using Leu 5 antibody. These cells are predominant in the PALS and MZ. Magnification 100 x. B (right): Localization of B cells using anti-kappa antibody on serial section of the same white pulp region. These cells are predominant in the GC, M, MZ and adjacent RP. Magnification 100x. Arrows indicate cells with natural peroxidase activity

talization in one particular white pulp site. In Fig. 4A the antibody directed at mature T cells discloses prominence of T cells in the periarteriolar lymphoid sheath and mantle zone with rare cells in the germinal center and red pulp. This particular monoclonal antibody (Leu 5) detects T cells with the sheep red blood cell receptor (E rosette receptor). These cells correspond closely to those measured by standard cell suspension rosetting. In Fig. 4B the antibody detects surface and cytoplasmic immunoglobulin-bearing cells. This staining pattern confirms that surface immunoglobulin-bearing cells are located primarily in the germinal center, mantle of the germinal center, marginal zone and immediately adjacent red pulp with few, if any, in the PALS. It is likely that these B cells home to the mantle zone and the mantle of the germinal center from the vasculature (2, 5, 6). Follow-

ing antigen trapping and transfer to the germinal center, there is clonal expansion of B cells within the germinal center where abundant mitoses are noted (2, 5-7).

The findings in Figure 4 substantiate striking compartmentalization of B and T cells in the white pulp of the spleen. T cells occur mainly in the PALS and MZ but they are also admixed with B cells in the mantle region of the germinal center and within the substance of the germinal center itself. The occasional T cell noted in the germinal center corresponds with our findings and that of others in lymph nodes (8). T cells, therefore, appear to play a fundamental role in B cell proliferation and germinal center formation (2). The overlap of T and B cell zones in the white pulp of the spleen probably reflect the complex functional interaction of B and T cells in this region.



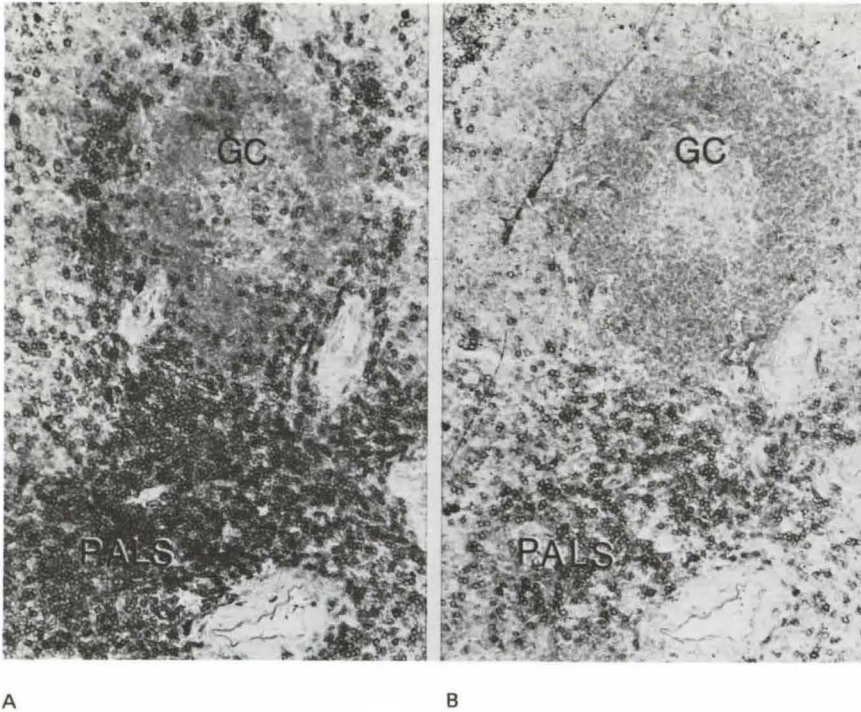
**Fig. 5** Immunoglobulin-bearing cells: A (left): Localization of kappa light chain-bearing cells using anti-kappa antibody. B (right): Localization of lambda light chain-bearing cells using anti-lambda antibody. Note that kappa outnumber lambda bearing cells and some GC cells are immunoglobulin negative. Magnification 60 x

*C. Localization of immunoglobulin-bearing cells:*

Figures 5A and B demonstrate an abundance of surface and/or cytoplasmic immunoglobulin-bearing cells of both kappa and lambda light-chain types in the white pulp. In each case a polyclonal pattern of both kappa and lambda light-chain expression is apparent. Kappa-bearing cells, as illustrated, consistently outnumber lambda-bearing cells as previously described in reactive lymph nodes (9). The immunoglobulin-bearing cells are located primarily in the mantle of the germinal center, in the marginal zone and in the adjacent red pulp with a few visible in the PALS. Note that the germinal center demonstrates mainly "intracellular" deposition of immunoglobulin but with minimal cellular surface immunoglobulin apparent, corresponding with earlier observations in

lymph nodes that the predominant germinal center cell is surface immunoglobulin negative and immature B cell antigen positive (9). The majority of these germinal center cells represent less mature B cells (9). Figure 5 illustrates that this phenomenon is "zonal" with most surface immunoglobulin positive cells clustered at one end of the germinal center, probably reflecting zonal maturation within the germinal center (9).

Abundant mitoses are noted in the germinal centers indicating frequent clonal expansion of B cells. Throughout the B cell zone, large transformed immunoblasts are noted along with differentiated plasma cells. Plasma cells are densest at the edge of the germinal center suggesting frequent B cell differentiation in this zone. In one spleen, plasma cells are also prominent in the splenic red pulp. Thus, all the known proliferative, transforming, and



**Fig. 6** Subset T cells. A (left): Localization of T helper cells using Leu 3a antibody. B (right): Localization of T suppressor/cytotoxic cells using Leu 2a antibody. T helper cells outnumber T suppressor/cytotoxic cells in the PALS and MZ. Magnification 100 x

differentiating stages of B cell ontogeny are represented in the reactive B cell zones of the splenic white pulp.

#### *D. Localization of subset T cells:*

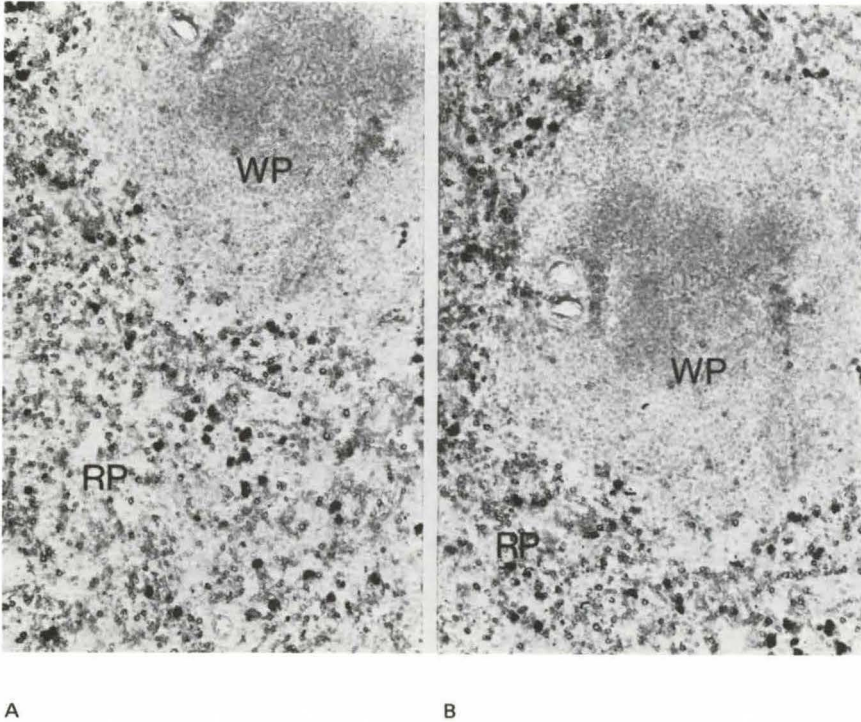
As depicted in Figs. 6 and 7, monoclonal antibodies to T cell subsets demonstrate the distribution of subset cells in the white pulp. The Leu 3a identifies T helper cells (Fig. 6A), and the Leu 2a identifies T suppressor/cytotoxic cells (Fig. 6B). The assessment of subset T antigens in Figure 6 was performed on serial sections, allowing determination of the distribution and number of subset T cells in a single white pulp location.

The staining pattern in Fig. 6A indicates the majority of cells in the PALS and MZ are T helper cells with only a scattering of these cells in secondary germinal centers and red pulp. Compared to Fig. 6B, T helper cells are

the predominant functional T cell subset in the splenic white pulp, a finding observed in all six cases studied. As illustrated T helper cells generally exceed T suppressor/cytotoxic cells by a substantial ratio estimated in excess of 4 to 1 as we and others have observed in reactive lymph nodes (8).

Fig. 6 demonstrates the occurrence of T helper cells in germinal centers. Full B cell development requires the presence of T helper cells (2), and this close proximity of B and T helper cells in germinal centers probably facilitates their functional interaction.

The distribution of T suppressor/cytotoxic cells is shown in 6B. In the white pulp, these cells predominate in the PALS but are absent in the germinal center. As mentioned previously, there are considerably fewer T suppressor/cytotoxic cells than T helper cells in this region. While T suppressor/cytotoxic cells are a



**Fig. 7** T suppressor/cytotoxic cells are scattered throughout the red pulp. Antibody Leu 2a. Magnification 60 x, 100 x

minority component in the white pulp, they are the predominant T cell component in the red pulp (Fig. 7), where their distribution corresponds closely to that of histiocytes, monocytes and natural killer (NK) cells (Figs. 8 and 9).

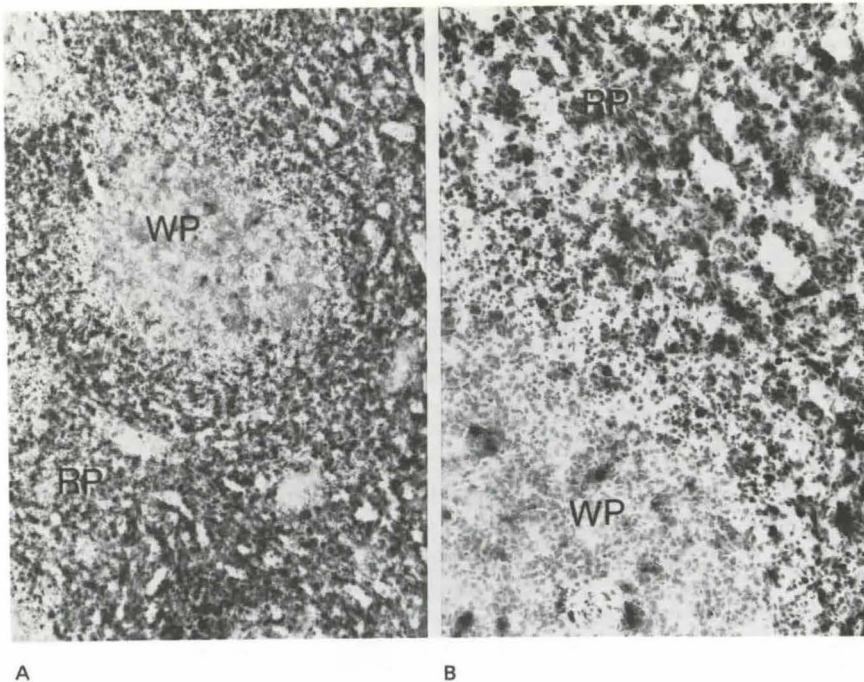
Previously, immune function in the red pulp was linked primarily to phagocytic, pitting or culling functions and in turn to monocytic/histiocytic activity (6). Our findings suggest that T suppressor/cytotoxic cells may operate in conjunction with histiocytes to effect the cytotoxic and phagocytic function of the red pulp. NK cells are also noted in close association so that a triumvirate of natural killer, T suppressor/cytotoxic and histiocytic cells may collaborate in red pulp functions.

#### *E. Localization of monocytes and histiocytes:*

Tissue section assessment of monocytic/histo-

cytic enzyme activity shown in Figs. 8A and B demonstrates the prominence of monocytic/histiocytic cells in the red pulp. These cells are visible both within cords and lining sinuses. While an occasional histiocyte is also seen in germinal centers and marginal zones, the staining pattern confirms that the predominant phagocytic activity of the spleen is in the red pulp. Some of the monocytic/histiocytic enzyme positive cells in the germinal center and marginal zone probably are antigen presenting cells. In one case, special enzyme inhibition studies using sodium fluoride indicate that monocytes are particularly prominent in the marginal zone region while histiocytes are more prominent in the cords and sinuses. The finding of the more immature monocytic elements in the marginal zone, which is rich in terminal arterioles (Fig. 2 and 3), may signify that these cells are either recent arrivals from the bloodstream or are pivotal in antigen trapping at this site.





**Fig. 8** Monocytic and histiocytic cells are abundant in the red pulp. Magnification A (25 x), B (100 x) Butyrate esterase stain

As previously mentioned, the more mature histiocytes predominate in the red pulp cords and exhibit a distribution similar to T suppressor/cytotoxic cells. However, they more conspicuously line the sinuses while T suppressor cells are more restricted to the cords.

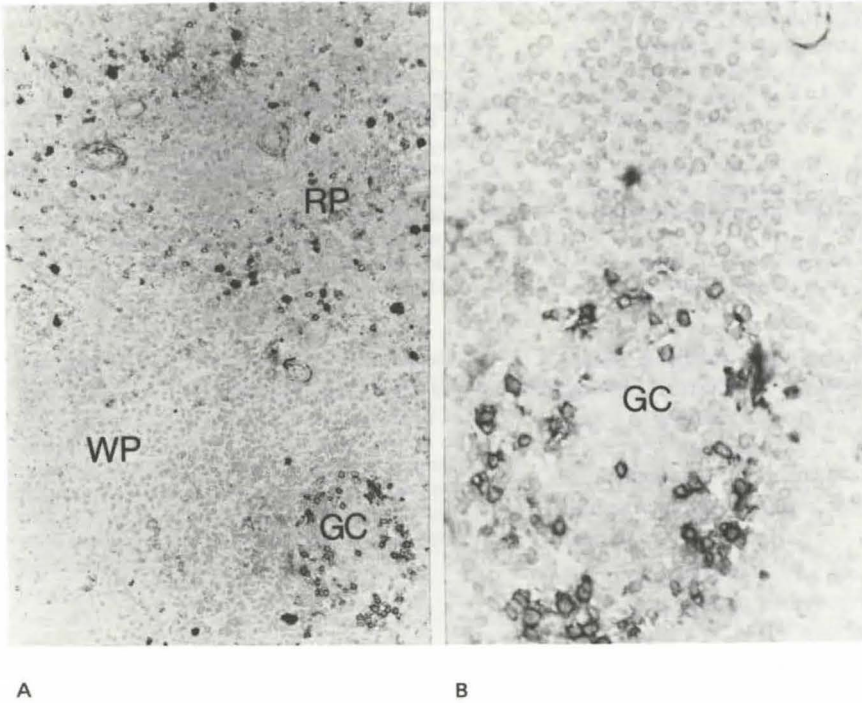
#### *F. Localization of natural killer cells:*

The monoclonal antibody directed at natural killer cells (NK cells) indicates they are found in two splenic locations: 1) scattered about the red pulp and 2) conspicuously restricted to the germinal centers in the white pulp (Fig. 9). The latter pattern corresponds to the NK restriction in germinal centers that we have observed in reactive lymph nodes and tonsils. NK cells occur in substantially fewer numbers than T suppressor/cytotoxic cells and histiocytes in the red pulp. Thus, while NK cells may function in a triad with T suppressor/cytotoxic and histiocyte cells, they constitute a minority component in the normal function of the spleen.

Historically, the spleen has been regarded as a central site of NK cell activity (10). Specific antibodies to NK cells and T suppressor/cytotoxic cells now distinguish between these overlapping cytotoxic functional cells. In the present study these antibodies indicate a great predominance of T suppressor cells over true NK cells in the red pulp, suggesting that cytotoxic and cytolytic functions of the spleen relate more to T suppressor/cytotoxic cells than to NK cells. Whether this is also true in pathologic conditions is unknown.

#### *IV. Conclusion*

The tissue section method described here represents a new and exciting way of assessing the immunoreactivity of the spleen. Using snap frozen tissue sections, hybridoma-derived monoclonal antibodies and biotin-avidin methods of conjugation along with peroxidase labelling, the B and T cell zones of the spleen can be fully delineated. T cells predominate in the periarteriolar lymphoid sheaths and B cells in the germinal centers and mantle region.



**Fig. 9** Natural Killer (NK) cells, A (left) are scattered in the red pulp and within germinal centers. Antibody Leu 7. Magnification 25x. B (right):Detail of NK cells in a germinal center. Magnification 250 x

There is nonetheless considerable overlap of these lymphocytes in the mantle zone as well as spillover of both into the adjacent red pulp.

Among lymphoid subsets, T helper cells strikingly predominate over T suppressor/cytotoxic cells in the white pulp. Some T helper cells reside in germinal centers indicating a close relationship between B clonal expansion and T helper cell activity. While T suppressor/cytotoxic cells are a minority T cell component in the white pulp, they are the predominant T cell component in the red pulp where they are closely admixed with NK cells and monocytic/histiocytic cells. This close proximity suggests that they function as a triad in effecting the culling and pitting functions of the spleen.

Collectively, our findings demonstrate the anatomic compartmentalization of lymphoid and histiocytic cells in the spleen. Although the complex overlapping patterns in both

the red and white pulp remain unexplained, the tissue section mode of analysis is likely to prove useful in further delineating the fascinating details of the immunoarchitecture of the spleen in normal and diseased states.

### References

- 1 Warnke, R., R. Levy: Detection of T and B cell antigens with hybridoma monoclonal antibodies: a biotin-avidin-horseradish peroxidase method. *J. Histochem. and Cytochem.* 28 (1980) 771-776
- 2 Weissman, I.L., R. Warnke, E.C. Butcher, R. Rouse, R. Levy: The lymphoid system, its normal architecture and the potential for understanding the system through the study of lymphoproliferative diseases. *Hum. Pathol.* 9 (1978) 25-33
- 3 Wood, T., R. Warnke: Suppression of endogenous avidin-binding activity in tissues and its relevance to biotin-avidin detection systems. *J. Histochem. Cytochem.* 29 (1981) 1196-1204
- 4 Yam, L.T., C.A. Li, W.H. Crosby: Cytochemical identification of monocytes and granulocytes. *Am. J. Clin. Pathol.* 55 (1971) 283-290
- 5 Weiss, L.: The Spleen. In *The Blood Cells and*

- Hematopoietic Tissues. Chapter 15, pp. 545–573. McGraw-Hill, New York, N.Y. 1977
- 6 Crosby, W.H.: Structure and Function of the Spleen. In Hematology. Chapter 9, pp. 74–81. Eds.: Williams, W.J., E. Beutler, A.J. Ersleu, R.W. Rundles, 2nd Ed., McGraw-Hill, New York, 1977
- 7 Langevoort, H.L.: The histophysiology of the antibody response. I. Histogenesis of the plasma cell reaction in rabbit spleen. Lab. Invest. 12 (1963) 106–116
- 8 Poppema, S., A.K. Bhan, E.L. Reinherz, R.T. McCluskey, S.F. Schlossman: Distribution of T cell subsets in human lymph nodes. J. Exp. Med. 153 (1981) 30–41
- 9 Stein, H., A. Bonk, G. Tolksdorf et al.: Immunohistologic analysis of the organization of normal lymphoid tissue and non-Hodgkin's lymphomas. J. Histochem. Cytochem. 28 (1980) 746–760
- 10 Gupta, S., C. Tan: Subpopulations of human T lymphocytes. XIV. Abnormality of T-cell locomotion and of distribution of subpopulations of T and B lymphocytes in peripheral blood and spleen from children with untreated Hodgkin's disease. Clin. Immunol. and Immunopathol. 15 (1980) 133–143

*Th.M. Grogan, M.D., C.S. Jolley, M.T., C.S. Rangel, H.T.L., Department of Pathology, University of Arizona, Arizona Health Sciences Center, Tucson, Arizona 85724*