

## Accidental Visualization of Mesenteric Lymph Nodes by Bipedal Lymphography

L. Bastholt, M.D., P. Pfeiffer, M.D.

Department of Oncology and Radiotherapy, Odense University Hospital, Odense, Denmark

### Summary

A case is presented of mesenteric lymph nodes filling accidentally by bipedal lymphography. The radiographs were interpreted erroneously as pathologic; consequently the patient was treated with chemotherapy and radiotherapy. The correct diagnosis was made later by explorative laparotomy.

Since *Kinmonth* in 1952 (7) introduced his method for bipedal lymphography (BL), many studies have been made concerning the diagnostic value as well as sensitivity and specificity (5).

An abnormal distribution of a contrast agent after BL is well known from experiments in dogs having their thoracic duct ligated (6). Similar abnormalities were seen in patients with obstruction of the lymphatics, e.g. caused by tumor, or other abnormal conditions such as protein-losing enteropathies and chylothorax (1, 2, 3).

Filling of mesenteric lymph nodes by BL has never been described in healthy persons, although the existence of lymphatico-lymphatic anastomoses has been postulated (1, 4, 8, 9, 10).

### Case Report

A sixty-one year old man was admitted to lymphography for staging purposes after removal of the right testis because of a pure seminoma. BL was performed with an oily contrast medium (Duroliopaque®, Guerbet), 10 ml on each side. Filling of the cisterna chyli in the angiographic phase was seen. In the nodular phase numerous lymph nodes were seen within a large area laterally and anteriorly to the aorta. The nodes were numerous and

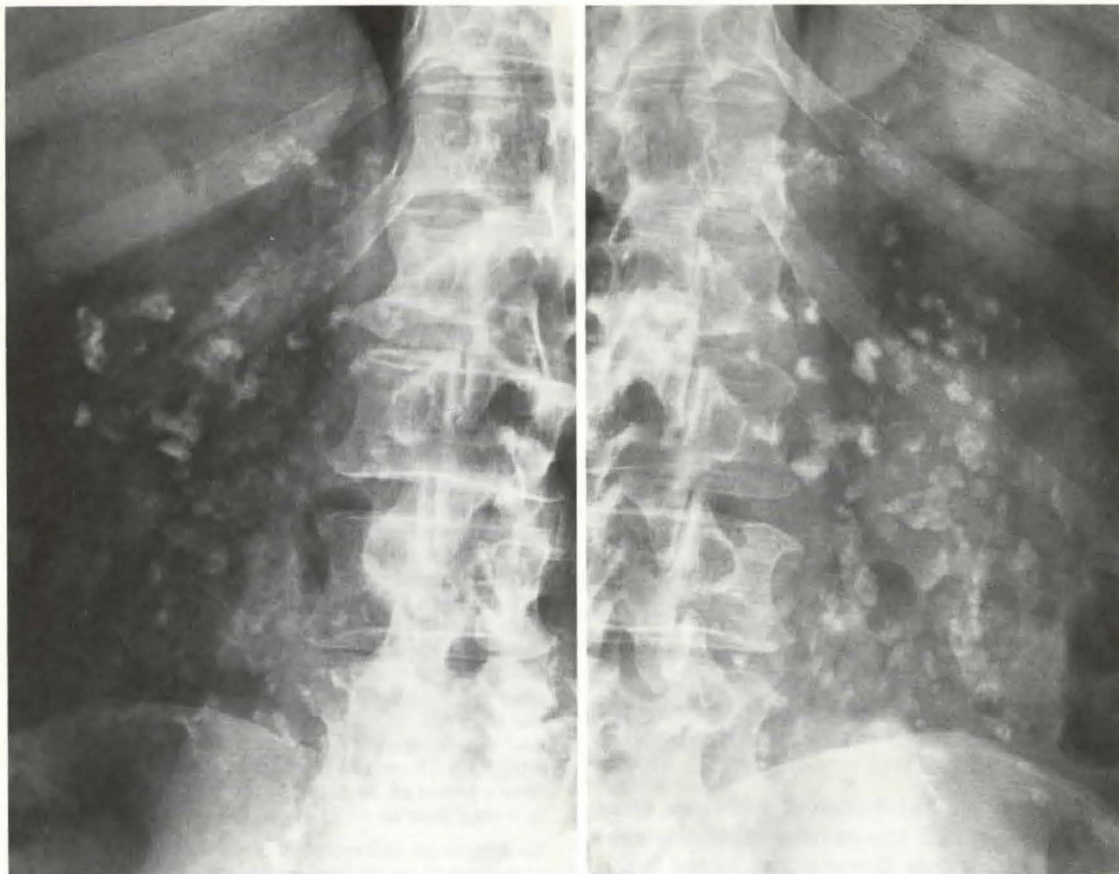
small with no filling defects (Fig. 1 and 2). No tumor was palpable. Laboratory analyses including urea, creatinine, alpha-fetoprotein, HCG, and parameters concerning liver function were normal. Chest x-ray, intravenous pyelogram, and renography were normal, too. With the purpose of reducing the size of the lymph nodes for later radiotherapy, treatment with cyclophosphamide, vincristine, methotrexate, and 5-fluorouracil was instituted. Repeated abdominal films 24 days later showed no regression of the "tumor". The chemotherapy was changed to cis-platinum, bleomycin, and vinblastine. This combination was given twice within four weeks, but still no regression was observed. Therefore radiotherapy was applied to the "tumor region" by parallel opposing fields, measuring 13 x 18 cm and involving the right kidney. Over a period of 34 days 23 treatments were given to a total dose of 40.25 Gy in the "tumor".

Since repeated abdominal films showed no regression of the lymph nodes, explorative laparotomy was performed. No signs of tumor or pathologic lymph nodes were found. Histologic examination of a mesenteric lymph node revealed changes after lymphography, but no signs of malignancy or specific inflammation. Within a two year observation period the patient was without sign of recurrence of his testicular seminoma. Isotope renography showed reduced size of the right kidney, but with normal function. Urea and creatinine were normal.

### Discussion

Where BL is used as a way of staging malignant diseases the possibility of atypical filling of the lymph system should be kept in mind when unusual radiographic films are obtained.

In the case presented the interpretation of BL resulted in unnecessary treatment with chemotherapy and radiotherapy on a large abdominal field (13 x 18 cm), including the right kidney. The reason for filling of the mesenteric lymph



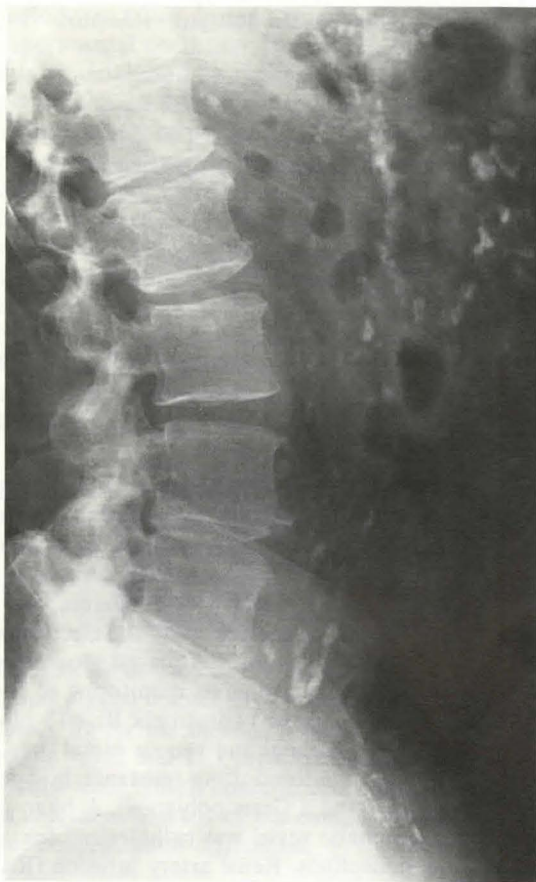**Fig. 1a and 1b** Lymphogram at 24 hours showing filling of presumably pathologic lymph nodes, anteriorly and laterally to the aorta

nodes can not be established, but presumably it has taken place through a lymphatico-lymphatic anastomosis or through an abnormal reflux from the cisterna chyli.

When the clinical picture and lymphography are not concordant, or when the lymphography is inconclusive because of inadequate filling of the lymph nodes or extraordinary appearance, then computed tomography and/or ultrasound investigation should be performed.

#### References

- 1 *Beltz, L., P. Thurn*: Diagnose and Differentialdiagnose des Lymphangiogramms bei retroperitonealen Tumormetastasen. *Fortschr. Röntgenstr.* 107 (1967) 1: 1–14
- 2 *Beltz, L., Ch. Linzbach, M. Thelen, D. Hermanutz*: Lymphographische Metastaskriterien im Lymphangiogramm – Diagnose und Differentialdiagnose. *Radiologica Diagn.* 13 (1972) 640–649
- 3 *Benninghoff, D.L., M.R. Camiel, T. Takashima*: Clinical and experimental studies of Chylous Reflux. *Progress in Lymphology II* (1968) 269–271
- 4 *Bruna, J.*: Types of Collateral Lymphatic Circulation. *Lymphology* 7 (1974) 61–68
- 5 *Dunnick, N.R., N. Javadpour*: Value of CT and Lymphography: Distinguishing Retroperitoneal Metastases from Nonseminomatous Testicular Tumors. *Amer. J. Roentgen* 136 (1981) 6: 1093–1099
- 6 *Ishida, O., Y. Taji, H. Uchida, S. Sone*: Lymphatico-venous Anastomoses – Experimental Study. *Progress in Lymphology II* (1968): 85–87



**Fig. 2** Same as Fig. 1 shown in the lateral view

- 7 *Kinmonth, J.B.*: Lymphangiography in Man. Method of outlining lymphatic trunks at operation. *Clin. Sci.* 11 (1952) 13–20
- 8 *Moulopoulos, S.D., L.P. Anthopoulos*: Collateral Lymphatic Circulation. *Angiology* 16 (1965) 580–583
- 9 *Threefoot, S.A., W.T. Kent, B.F. Hatchett*: Lymphaticovenous and Lymphaticolymphatic Communications demonstrated by Plastic Corrosion Models of Rats and by Post-mortem Lymphangiography in Man. *J. Lab. and Clin. Med.* 61 (1963) 9–15
- 10 *Welin, S., S. Johanson*: Lymphography, in *Encyclopedia of Medical Radiology (VIII)*, L. Diethelm. Springer Verlag, Berlin 1968

*Dr. Lars Bastholt, Kragemosen 58, 5250 Odense SV, Denmark*