

INDIRECT LYMPHOGRAPHY OF THE BREAST WITH IOTASUL: A VANISHING HOPE?

R. Musumeci, J.D. Tesoro-Tess, A. Costa, and U. Veronesi

Instituto Nazionale per lo Studio e la Cura dei Tumori, Milan, Italy

ABSTRACT

Using a new aqueous nonionic contrast medium (Iotasul, Schering) we attempted visualization of axillary lymph nodes in patients with breast carcinoma. Intradermal infusion into the areola consistently opacified the subareolar plexus and latero-cranial lymphatic trunk. Axillary nodes were visualized in 78.6% of patients, but only 5.7% of surgically excised nodes were partially or totally opacified. Eleven patients underwent axillary lymph node dissection and histology confirmed metastases in 4, of which only two were detected by lymphography. Breast lymphography is inadequate for routine clinical application, and radical axillary dissection remains the mainstay for documentation of nodal metastases.

The prognosis in breast cancer primarily rests on the extent of axillary metastases. Even with limited resection of the breast (e.g., quadrantectomy), radical axillary dissection has been considered necessary for accurate histologic staging of disease. Preoperative radiologic imaging of the axilla to depict regional nodes has previously been attempted with a variety of techniques including soft tissue radiography in conjunction with mammography and xeroradiography (1,2). The results, however, have been disappointing. Direct lymphography of the upper arm with oily contrast medium (3) has also been tried, but technical failures and limited opacification of axillary nodes have rendered this procedure obsolete. Because of these drawbacks, the effectiveness of preoperative imaging to detect axillary nodal involvement in breast carcinoma has been extremely limited and ax-

illary dissection deemed mandatory.

Recently, a new lymphographic contrast medium with unique characteristics has been developed (Iotasul, Schering) and tested both in animals and humans in a variety of lymphographic procedures, including breast lymphography.

The aim of our study was to determine the diagnostic value of this new contrast medium for visualization of the lymphatic drainage of the breast to regional axillary nodes.

CONTRAST MEDIUM

Iotasul (Schering) is a nonionic dimeric hexaiodinated contrast medium available as an aqueous formulation with an iodine content of 275 mg/cm³. The substance was first described by Siefert et al (4), and in experimental animals exhibits rapid renal excretion, good systemic tolerance, and excellent lymphatic visualization (3). Thus, Iotasul has been used for direct lymphography after injection into a peripheral lymphatic or lymph node, and for indirect lymphography after introduction into skin, subcutaneous tissue, muscle, parenchymatous organs and serous cavities (5). Whereas oil based contrast (e.g., lipiodol) is stored for a long time in lymph nodes and in the lymphatic network when occluded, Iotasul disappears quickly (average two hours). Moreover, lipiodol incites an intense histiocytic and giant cell foreign body reaction around primary oil-filled

pseudocysts in lymph nodes (5). By contrast, Iotasul stimulates only a mild inflammatory infiltrate which regresses by 8 days.

LYMPHATIC DRAINAGE OF THE BREAST

Mammary lymphatic drainage closely follows the venous system (6). From the subareolar plexus the major lymphatic trunk drains to axillary nodes. These nodes are divided into 3 levels in relation to the pectoralis minor muscle (first level-lateral, second-posterior, and third-medial to the muscle). At times, breast lymph drains directly to the second and third level through channels behind the pectoralis minor or between the major and minor muscles.

The main efferent lymphatics to the internal mammary chain emerge from the deep aspect and from the medial portion of the breast. They penetrate the pectoralis major muscle, accompany branches of perforating blood vessels, and at the most medial aspect of the intercostal space, turn inward sharply, penetrating intercostal muscles to enter internal mammary nodes. An alternative pathway drains to lymph nodes between the major and minor pectoralis muscle (interpectoral or Rotter's nodes) (Fig. 1).

TECHNIQUE

The technique for indirect intradermal lymphography with Iotasul has been described by Wenzel-Hora et al (7) in experimental animals and modified for humans by Schmidt et al (8). The needle must be inserted superficially (almost paralleling the skin surface) just beneath the epithelial stratum corneum. Lymph capillaries are located here and freely communicate with the interstitium. Only in this region does injected contrast medium pass from interstitium to lymph capillaries and then to lymphatic collectors.

Neither sedation nor local anesthetic are given. The patient is positioned supine on a fluoroscopic table with slight rotation

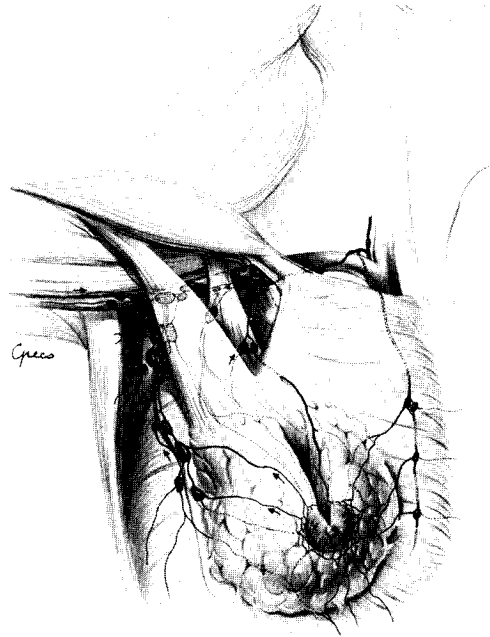

Fig. 1: Schematic drawing of the lymphatic drainage of the breast.

to the side under investigation. After disinfecting the skin of the breast, areola, and nipple, a polyethylene tube with a 30g. lymphographic needle is inserted for 5mm through the skin intradermally from the external margin of the areola toward the nipple. A plastic syringe filled with 3ml of Iotasul is then connected to the catheter. Usually 2 needles are inserted, one at 4 and the other at 8 o'clock in the circumference of the areola. The syringes are then placed in a variable pressure electric pump and "dye" infused over 10-20 minutes. Correct positioning of the needle is ascertained by subcutaneous swelling produced by dye and progressive opacification of subareolar lymphatic plexus and afferent lymphatics to axillary nodes as monitored by fluoroscopy. Radiographs in different projections are taken at regular intervals until the end of the infusion. Overly deep insertion of the needle results in an inadequate intradermal wheal in the areola and poor opacification of adjacent lymphatic network. If this misdirection occurs, the needle is

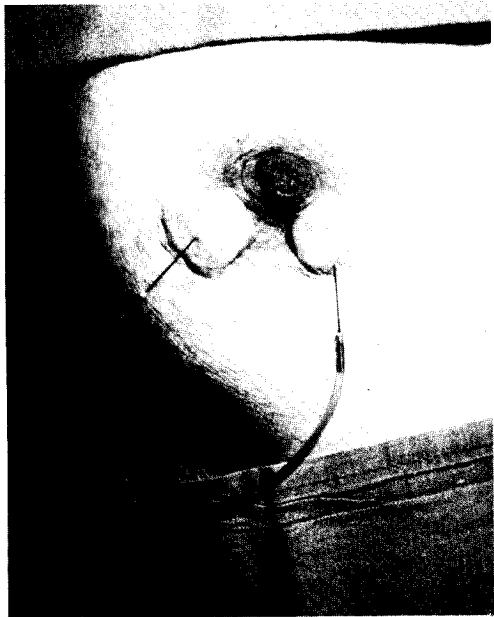


Fig. 2: Proper intradermal insertion of the needles and infusion of contrast medium produces a subcutaneous periareolar wheal.

withdrawn and reinserted to obtain a puncture more superficial and parallel to the skin (Fig. 2).

During the procedure patients feel no pain or regional discomfort; there are no adverse reactions to the contrast medium. Patients usually undergo operation (quadrantectomy or radical mastectomy plus axillary dissection) one or two days later. No reaction at either the site of infusion or in excised lymph nodes has been noted.

CASE MATERIAL

The group of patients under investigation included 14 cases with breast disease (Table 1). In one patient (#1) histologic intraoperative evaluation of the breast nodule revealed a benign fibroadenoma; in this patient axillary dissection was obviously avoided. In another patient (#8) bone metastases were present in the pelvis at time of presentation and only a "tumorectomy" was performed. In a third clinically

T₂N_{1b} patient (#12), intraoperative biopsy of enlarged neoplastic axillary nodes revealed on histologic examination combined breast carcinoma and non-Hodgkins malignant lymphoma. Formal axillary dissection was unnecessary.

The remaining 11 patients had complete axillary dissection and removal of regional lymph nodes in the range of 9-43 axillary (average 19) nodes per patient. Histologically, carcinomatous metastases were detected in 4 patients or 36.4% (2 clinically N₀ and N_{1b}).

IMAGING RESULTS

Although indirect breast lymphography after intradermal paraareolar injection of Iotasul consistently opacified the subareolar lymphatic plexus and latero-cranial lymph trunk (Fig. 3A), nodal visualization was extremely limited. Lymphatic channels running medially toward the internal mammary nodes were never visualized no matter which circumferential site of the areola was chosen. We also failed to opacify internal mammary nodes by inserting the needle in other sites (e.g., the intercostal space near the cartilaginous border of the rib, or the xiphoid process of the sternum) or by infusing Iotasul intradermally, subcutaneously, or deep into the chest muscles of the thorax and upper abdomen. Neither lymphatic nor retrosternal nodes were opacified as contrast simply diffused into adjacent soft tissue.

Axillary lymph nodes were opacified in 11/14 patients (78.6%) but the number varied from only 1 to 3. Quantitatively only 5.7% of surgically excised nodes were partially or totally opacified using this technique. The radiologic image of the opacified nodes suggested metastatic disease in two patients (#2,3) in whom metastatic carcinoma was histologically verified (Fig. 3B). Lymphographically metastatic nodes were also suggested in patient #8 but no histological evaluation was possible (Fig. 3C). In the patient with diffuse axillary involvement by malignant lymphoma (#12) two opacified nodes suggested only mild

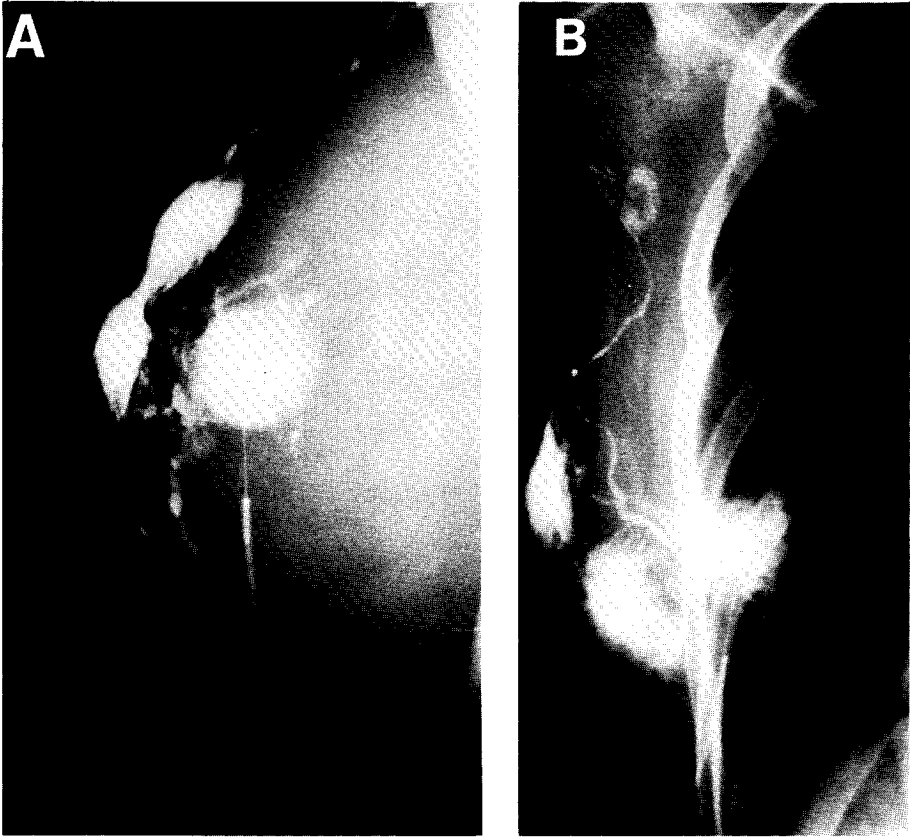
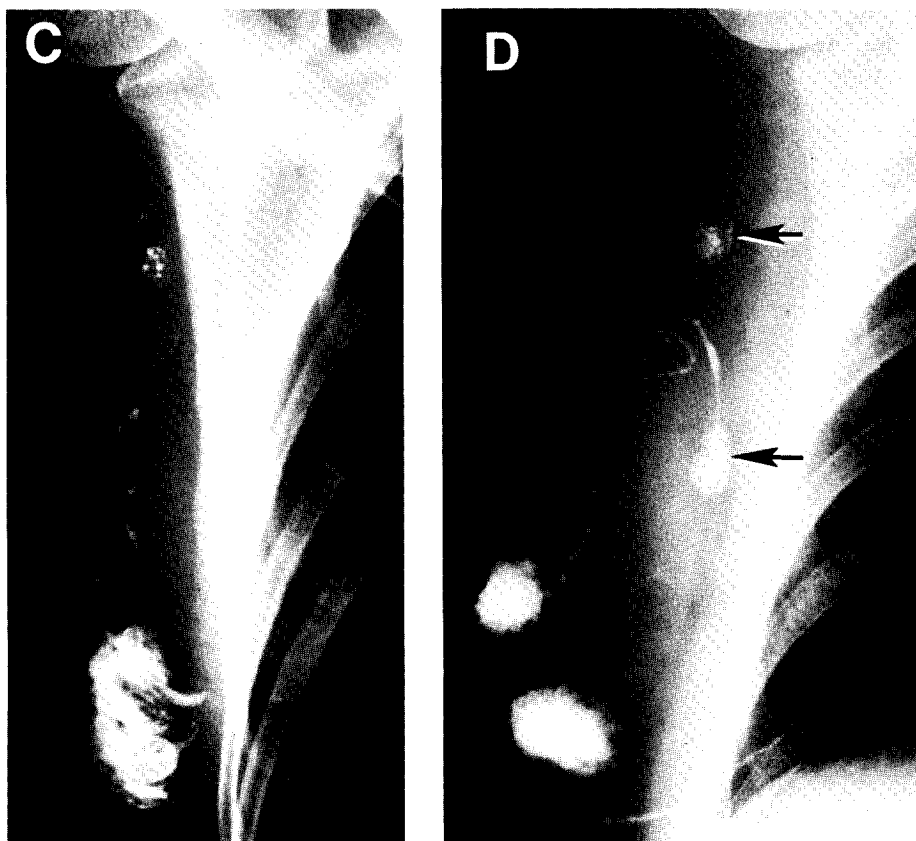


Fig. 3: A) Patient #7. Good visualization of subareolar lymphatic plexus and latero-cranial trunk. B) Patient #3. Opacification of axillary node with filling defect radiologically metastatic. At operation 3 metastatic nodes were confirmed.

Table 1
Case Presentation with Evaluation of Axillary Nodes

| Pt. # | Clinical Presentation | Surgery | | Radiology | |
|-------|---|-----------------|---------------|-------------------|--------------------|
| | | # Nodes | # Meta-stases | # Opacified Nodes | # Metastatic Nodes |
| 1 | Fibroadenoma | Not Performed | | 1 | - |
| 2 | T ₁ N ₀ M ₀ | 12 | 4 | 2 | 2 |
| 3 | " | 17 | 3 | 1 | 1 |
| 4 | " | 16 | - | 2 | - |
| 5 | " | 21 | - | 1 | - |
| 6 | T ₂ N ₀ M ₀ | 15 | - | 0 | - |
| 7 | " | 9 | - | 1 | - |
| 8 | T ₂ N ₀ M ₁ | Not Performed | | 3 | 2 |
| 9 | T ₂ N _{1a} M ₀ | 24 | - | 0 | - |
| 10 | " | 17 | - | 1 | - |
| 11 | T ₂ N _{1b} M ₀ | 14 | 2 | 2 | - |
| 12 | " | Lymphoma Non-HD | | 2 | - |
| 13 | T ₃ N _{1a} M ₀ | 28 | - | 2 | - |
| 14 | T ₃ N _{1b} M ₀ | 33 | 28 | 0 | - |



C) Patient #8. Opacification of 3 axillary nodes; two radiologically suspicious for metastasis. No axillary dissection done. D) Patient #13. Opacification of 2 hyperplastic axillary nodes (arrows); excision and histology disclosed sinus histiocytosis.

hyperplasia. In another patient with 28/33 histologically confirmed metastatic nodes (#14), breast lymphography while opacifying the subareolar plexus and draining lymphatics failed to visualize any axillary nodes. Finally in patient #13, two hyperplastic axillary nodes were suggested by radiologic imaging (Fig. 3D) and after axillary dissection histology confirmed only sinus histiocytosis.

DISCUSSION

Obtaining useful diagnostic information about the status of axillary nodes in breast cancer without surgical dissection has been an elusive goal of modern oncology. Accord-

dingly, preparation of a new contrast medium, theoretically ideal for indirect lymphographic evaluation of this region, was welcomed with great enthusiasm and hope (4,5,7).

The first published experience (7) consistently demonstrated the breast subareolar lymphatic plexus and the latero-cranial trunk, although inconsistency in visualizing axillary lymph nodes, the paucity of those visualized and the difficulty in obtaining full opacification suggested that the technique was unsatisfactory for clinical diagnosis (7).

Our experience was also discouraging. Whereas lymph nodes were visualized in a relatively high percentage of patients (78.5%), the number imaged was small (on-

ly 1-3 nodes per patient) and the intensity of opacification much too faint to assure diagnostic confidence. Indeed, when nodal metastases were extensive radiologic imaging was notoriously poor, probably because of lymph blockage by diffuse neoplastic infiltration. Thus, while a potentially useful concept, indirect lymphography with Iotasul fails to fulfill the need for routine clinical applicability, and radical axillary lymphadenectomy remains mandatory for staging and treatment of breast cancer.

REFERENCES:

1. Lamarque, JL: La mammella. Radiodiagnosi clinica. Adenopatie ascellari. (278-289) Marrapese, Roma, 1982.
2. Costa, A, L Gilardoni, C Andreoli, et al: Clinicopathological correlation of xeroradiography in determining metastatic axillary nodes involvement. Proceedings 13th International Cancer Congress 592 (1982), 106. Seattle.
3. Hulten, L, C Ahren, M Rosencrantz: Lymphangiography in carcinoma of the breast. Acta Chir. Scand. 132 (1966), 261.
4. Siefert, HM, W Mutzel, C Schobel, et al: Iotasul, a water-soluble contrast agent for direct and indirect lymphography. Lymphology 13 (1980), 150.
5. Wenzel-Hora, BI, B Kalbas, HM Siefert, et al: Iotasul, a water-soluble (non-oily) contrast medium for direct and indirect lymphography. Radiological and morphological investigations in dogs. Lymphology 14 (1981), 101.
6. Haagensen, CD: Lymphatics of the breast. From "The lymphatics in cancer". CD Haagensen, ed. (p. 300-388), Philadelphia, 1972.
7. Wenzel-Hora, BI, D Brens von Rautenfeld, HM Siefert: Direkte und indirekte lymphographie an hund. Tierarztl. prax. 10 (1982), 521.
8. Schmidt, M, V Taenzer: Indirekte mammalymphographie. Fortschr. Rontgenstr. 136 (1982), 448.