

# LYMPHSCINTIGRAPHY IN PERIPHERAL LYMPHEDEMA USING TECHNETIUM-LABELLED HUMAN SERUM ALBUMIN: NORMAL AND ABNORMAL PATTERNS

K Nawaz, M Hamad, S Sadek, M Awdeh, E Higazi, B Eklof, HM Abdel-Dayem

Departments of Nuclear Medicine (KN, SS, EH, MA, HA-D) and Surgery (MH, BE), Kuwait University and Mubarak Al-Kabeer Hospital, Ministry of Public Health, Kuwait

## ABSTRACT

Lymphoscintigraphy using Tc-99m human serum albumin (HSA) was examined in 23 patients with peripheral leg lymphedema. Each was injected intradermally with one mCi in the medial web space bilaterally. Images of the lower pelvis and both thighs were obtained within five minutes after injection using an extralarge field view camera GE 500A with low energy all purpose collimator interfaced with G.E. Star computer. These images were acquired in dynamic byte mode, 128 x 128 matrix size, every minute for 40 minutes. Delayed images for this region and of both legs were also taken at 90 minutes and time activity curves from comparable regions of interest over the inguinal area bilaterally were generated.

Three patterns emerged: 1—normal lymph flow (12 patients) characterized by symmetrical or nearly symmetrical early appearance of lymphatics (medial bands) with visualization of inguinal and pelvic lymph nodes in both early and delayed images. Time activity curves showed step ladder rise, in "pulses" every three to four minutes. 2—enhanced lymph flow pattern (6 patients) was characterized by rapid movement of radiolabelled albumin through dilated lymphatics, occasionally with subcutaneous pooling, and both larger and more numerous inguinal and pelvic nodes on the lymphedematous side. 3—obstructed lymph flow (5 patients) was characterized by subcutaneous pooling, absent lymphatics, (medial bands) and flat, time activity curve on the lymphedematous

side (only background activity) and absent inguinal and pelvic nodes. On delayed images, where lymphatic obstruction was incomplete there was delayed appearance of inguinal pelvic nodes which were fewer and smaller compared to the nonedematous side.

Intradermal injection of Tc-99m HSA is a useful technique to examine peripheral lymph dynamics in patients with chronic lymphedema of the legs. The procedure is safe, reliable, readily interpretable and may be repeated.

Peripheral lymphedema is a major disorder particularly in endemic areas from filariasis, repeated subcutaneous infection and trauma. Both nonoperative and operative management depends on intact function and patency of lymphatic and venous pathways. Contrast lymphangiography has shortcomings including need for tedious cannulation of a peripheral lymphatic with incision into the subcutaneous tissue, pulmonary oil emboli, and hypersensitivity to iodine in the infused contrast medium (1). To overcome these limitations, a growing interest has developed in radionuclide lymphoscintigraphy, and a variety of radionuclide approaches and labelled agents have been proposed (1-9). Interstitial injection of Au-198

colloid was abandoned early on because of unacceptably high absorbed radiation dose at the site of injection (10).

Among various Tc-99m labelled colloidal particles, microcolloidal antimony sulfite has shown the most satisfactory properties (2,3,6-9). However, there are two major drawbacks to use of colloidal particles: (1) Less than 35 percent of the interstitial dose is absorbed in 24 hours and (2) clearance from the injected site and trapping in draining lymph nodes depends on particle size and functional status of the reticuloendothelial system (6,9,11). Therefore, this technique does not entirely reflect lymphatic flow. Moreover, patients have to wait several hours before draining lymph nodes are visualized.

Tc-99m labelled dextran of high molecular weight (110,000), on the other hand, is a noncolloidal tracer compound, soluble in lymph fluid with molecules large enough that it is unable to penetrate the capillary membrane after interstitial injection (11-14). High molecular weight dextran, however, is not available for routine use and commercial kits for isotopical labelling are also unavailable.

Tc-99m Human Serum Albumin (HSA) has been previously evaluated for dynamic lymphoscintigraphy (15). Using intradermal injection of 5-8mCi, axillary or inguinal lymph nodes are visualized within 2-4 minutes and delayed nodal images are comparable to colloidal compounds. It has been found useful in a small group of patients with gynecologic cancer, lymphoma and other malignancies.

In the present study we used Tc-99m HSA to examine the pathophysiologic pathways of lymph in patients with unilateral or bilateral nonmalignant leg lymphedema.

## MATERIALS AND METHODS

Twenty-three patients (16 females and 7 males; age from 9 to 60 years) with leg lymphedema from a few weeks to 13 years underwent dynamic lymphoscintigraphy. Before injection the feet were thoroughly

washed with soap and water. Under aseptic conditions one mCi Tc-99m HSA was injected intradermally on the dorsum of each foot in the medial web space between the hallux and second toe. To ensure accuracy of intradermal injection tuberculin needles were used. Patients were positioned within five minutes under an extralarge field view gamma camera (G.E. 500A) interfaced with G.E. Star computer. Using low energy general purpose collimator, the field of view covered an area from the lower pelvis to the lower thighs. Data were acquired in dynamic byte mode, matrix size 128 x 128 pixels and were stored every minute for 40 minutes. Delayed images at these sites were obtain in 90 or 120 minutes after injection. All studies were stored on double density floppy discs. Data were displayed by reframing the dynamic part to have cumulative images of ten minutes each. Equal regions of interest were assigned over each inguinal region and background-corrected, smoothed-time activity curves were generated. All data including reframed images, delayed images and time activity curves were interpreted in light of the clinical findings.

## RESULTS

All studies were reviewed by three observers. Three broad categories were identified according to the appearance of Tc-99m HSA at the site of injection: draining lymphatics which visualize as a medical band along the inner aspect of the leg and thigh, number and size of inguino-pelvic lymph nodes, and time activity curves taken from the inguinal region.

### 1. NORMAL PATTERN: (12 patients, Fig. 1)

- a. early proximal migration of intradermally injected Tc-99m HSA along draining lymphatics (single or double medial bands)
- b. localization of activity in inguinal or pelvic nodes within 40 minutes
- c. on delayed images (i.e. 90 minutes) inguinal and pelvic lymph nodes were visualized bilaterally and were in general, symmetrical and equal in number and size

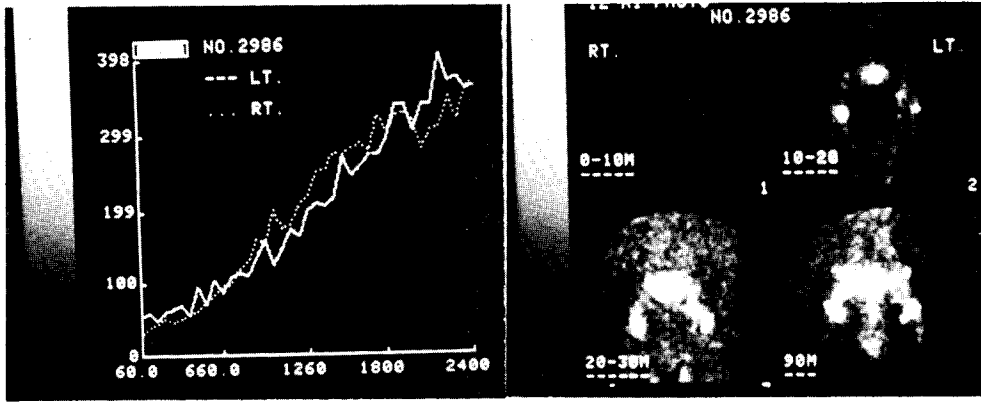


Fig. 1: Normal lymphatic pattern after injection of Tc-99m HSA into the foot. Note symmetry of leg lymphatics, visualization of inguinal pelvic lymph

d. time activity curves were similar on each side and were characterized by a step ladder pattern with rising "pulses" appearing every 3-4 minutes

Occasionally there was asymmetry in the curve pattern but the rising step ladder shape was retained.

The clinical manifestations in these twelve patients included a history of mild trauma or surgical scarring (5 patients), past history of recurring cellulitis or erysipelas (3 patients), indefinite predisposing factors

nodes and rapidly rising "pulsed" time activity curve over the inguinal region (left).

with normal contrast venograms (3 patients), history of deep vein thrombosis (1 patient).

Another patient had primary lymphedema of one year duration treated by transposition of the omentum into the upper medial portion of the thigh. Lymphoscintigraphy (Fig. 2) showed early appearance of medial bands bilaterally, pooling of lymph at the operated site and intact drainage to inguinal lymph nodes. The time generated curves were normal with slightly greater flow in the diseased limb.

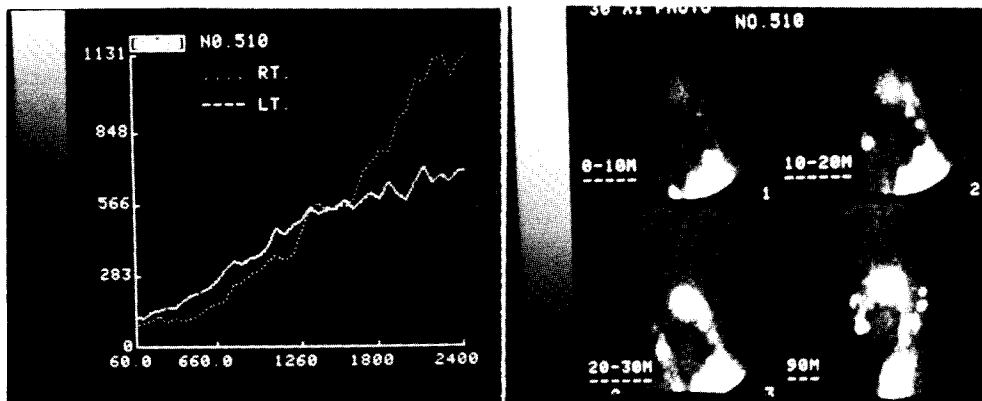


Fig. 2: Forty-year-old man with one year edema of left lower leg due to filariasis treated three months earlier by omental transposition. The pattern is close

to normal (compare with Fig. 1 and see text for details).

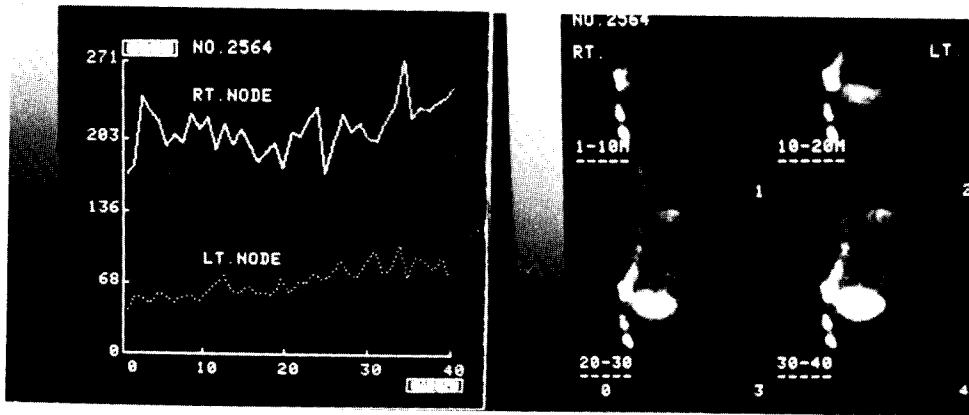


Fig. 3: Obstructive lymphatic pattern characterized by subcutaneous and interstitial pooling of contrast (lymph) on edematous side, absent medial "bands"

## 2. OBSTRUCTED PATTERN: (5 patients, Fig. 3)

- stasis or subcutaneous pooling of injected Tc-99m HSA
- absence of medial bands along the lower leg and thigh with lymphedema
- non-visualization of inguino-pelvic lymph nodes on the delayed image
- flat, time activity curves over the inguinal region without rising "pulses," and representing only background activity

Clinically, these patients were characterized by longstanding swelling of the leg (3-13 years). Three patients had

and failure to visualize inguinal lymph nodes. Time generated curves over the inguinal region (left) of the diseased leg is flat (background activity).

filariasis and two recurrent episodes of erysipelas as the cause of edema.

## 3. ENHANCED PATTERN: (6 patients, Fig. 4)

- rapid proximal flow of lymph through markedly dilated lymphatics (single or double medial bands) with occasional subcutaneous pooling along the lymphatic pathways
- increased size and number of lymph nodes on the edema side
- time activity curve over the inguinal region was much higher compared with the normal size. A continuous rise appeared, reached a peak in 10-15 minutes,




Fig. 4: Enhanced lymph flow pattern seen in diabetic patient with medina worm infection. There is fast flow of lymph proximally, dilated lymphatics, and increased size and number of inguinal lymph nodes.

The time activity curve over the inguinal region of the edematous leg is several-fold greater and faster than normal (left).

and then gradually declined.

Clinically most patients had recent erysipelas cellulitis or infection with medina worm (dracunculiasis). Some had recent trauma. Edema was of several weeks onset in three patients and of several years in the other three but duration of swelling did not affect the lymphoscintigraphic pattern.

#### *DISCUSSION:*

Study of pathophysiologic changes in peripheral lymphedema is difficult. As previously outlined use of water soluble contrast lymphangiography and Tc-99m labelled colloidal as well as high molecular weight dextran lymphoscintigraphy have limitations. Accordingly, need for a better noninvasive radionuclide test to examine lymph flow has been pressing and growing for over a decade. Lymphoscintigraphy using Tc-99m HSA for which commercial kits are available for easy labelling may fulfil this need. Dynamic imaging immediately following its intradermal injection is advised as discrepancies between the two sides are readily detected including dilatation of lymphatics and collateral pathways. Delayed pictures of the lower legs, thighs, and the inguinopelvic region are also important to demonstrate pooling of lymph from the site of injection, the number and size of regional nodes and whether complete or incomplete lymphatic obstruction exists, or whether there is enhanced flow of lymph. We recommend that reframed dynamic images, delayed images and time activity curves be interpreted in light of the clinical manifestations.

Normal peripheral lymph flow is generally symmetrical, moves in rhythmic "pulsating" waves every 3-4 minutes, and the curve's appearance is that of a rising step-ladder pattern. Injected Tc-99m HSA usually reaches the inguinal region within five minutes. Although the edematous side occasionally shows a slightly increased or

decreased flow rate the curve retains the ascending step-ladder appearance. An enhanced pattern is usually associated with greater lymph flow in patients with repeated cellulitis, erysipelas, acute filariasis or recent trauma. Increased tissue fluid and lymph production in the edematous limb increases lymph flow with dilatation of lymphatics and visualization of more than one "band" of lymphatics along the medial aspect of the lower leg and thigh. The number and size of inguinal-pelvic lymph nodes are also increased compared to the unaffected side.

Longstanding obstruction of lymphatics results in interstitial fibrosis with pooling and stasis of lymph in the subcutaneous tissue. Lymphoscintigraphy confirms markedly delayed proximal drainage of lymph in the edematous leg. It is noteworthy that in the patient with transposition of the omentum into the upper thigh for treatment of lymphedema that lymphoscintigraphy with Tc-99m HSA suggested restoration of a normal pattern.

In conclusion, lymphoscintigraphy using Tc-99m HSA is a simple, safe, and easy technique to examine leg lymph flow. The results are readily interpretable and the study can be repeated and used to evaluate the outcome of "edema-correcting" operations. Comparison with contrast lymphangiography though desirable is unwise because the latter is more invasive, carries the risk of infection, and stimulates lymphatic fibrosis.

**H.M. Abdel-Dayem, M.D.**  
**Professor and Chairman**  
**Department of Nuclear Medicine**  
**Faculty of Medicine**  
**Kuwait University**  
**P.O. Box 24923, Safat**  
**Kuwait**

## REFERENCES

1. Steckei, RJ, S Furumanski, R Dunam, et al: Radionuclide perfusion lymphangiography. An experimental technique to complement the standard ethiodol lymphangiogram. *Am J Roentgenol Rad Ther Nucl Med* 124 (1975), 600-609.
2. Ege GN: Internal mammary lymphoscintigraphy in breast carcinoma: A study of 1072 patients. *Int J Radiat Oncol Biol Phys* 2 (1977), 755-761.
3. Aspergen K, SE Styrand, BRR Person: Quantitative lymphoscintigraphy for detection of metastases to the internal mammary lymph nodes. Biokinetics of Tc-99m Sulfur colloid uptake and correlation with microscopy. *Acta Radiol Oncol* 17 (1978), 17-26.
4. Meyer CM, ML Leckitner, JR Logic, et al: Technetium-99m sulfur colloid cutaneous lymphoscintigraphy in the management of truncal melanoma. *Radiology* 131 (1979), 205-209.
5. Hultborn KA, LG Larson, HI Ragnhu: The lymph drainage from the breast to the axillary and parasternal lymph nodes studies with the aid of colloidal Au-198. *Acta Radiol* 43 (1955) 52-64.
6. Strand SE, BRR Person: Quantitative lymphoscintigraphy 1: Basic concepts for optimal uptake of radiocolloids in the parasternal lymph nodes of rabbits. *J Nucl Med* 20 (1979), 1038-1046.
7. Kaplan WD, MD Bloomer, AG Jones, et al: Mediastinal lymphoscintigraphy in ovarian cancer using intraperitoneal autologous technetium-99m erythrocytes. *Br J Radiol* 54 (1981), 126-131.
8. Ege GN, BJ Cummings: Interstitial radiocolloid iliopelvic lymphoscintigraphy: Technique, anatomy and clinical application. *Int J Radiation Oncology Biol Phys* 6 (1980), 1483-1490.
9. Kaplan WD, MA Davis, CM Rose: A comparison of two technetium-99m labelled radiopharmaceuticals for lymphoscintigraphy: Concise communication. *J Nucl Med* 20 (1979), 933-937.
10. Zum Winkel K: *Lymphologie mit Radionucliden*. Berlin, verlag Hildegard Hoffman, 1972.
11. Henze E, HR Schelbert, JC Collins, et al: Lymphoscintigraphy with Tc-99m labelled dextran. *J Nucl Med* 23 (1982), 923.
12. Rutili G, P Hagander: Transport of macromolecules in subcutaneous tissue. *Acta Universitatis Upsaliensis* 306 (1978), 1-51.
13. Bollinger A, K Jager, K Sgier et al: Fluorescence microlymphography. *Circulation* 64 (1981), 1195-2000.
14. Henze E, GD Robinson, HR Schelbert, DE Kuhl: Tc-99m dextran: A new blood pool-labeling agent for radionuclide angiocardiology. *J Nucl Med* 23 (1982), 348-353.
15. Obtake E, K Matsui, Y Kobayashi, Y Oao: Clinical evaluation of lymphoscintigraphy with Tc-99m Human serum albumin. *J. Nucl Med* 24 (1983), 41. (Abstract, Proceedings of the 30th Annual Meeting of the American Society of Nuclear Medicine).

## ACKNOWLEDGEMENT:

We would like to acknowledge technical staff at Ward 5, Mubarak Al-Kabeer Hospital, Mr. Akhtar Khan and Mrs. D.S. Kumari for typing the manuscript.