

## REEXAMINATION OF TESTICULAR LYMPHATIC DRAINAGE IN THE RAT

**A. Kazeem**

Department of Clinical Pathology, College of Medicine, University of Lagos, Lagos, Nigeria

### ABSTRACT

To clarify the route of gonadal lymph drainage in the rat we injected dilute India ink into testicular lymphatics and concomitantly replaced the entire blood volume with Ringers lactate. This technique intensified the blackness of injected lymph vessels against a background of pale, "washed out" tissues. Whereas rat testicular lymphatics may drain into regional lymph nodes, they also commonly bypass nodal tissue entirely and enter the cisterna chyli directly. This anomalous lymphatic group suggests the testis may be an immunologically privileged site.

In 1959, Engeset reported (1) that testicular lymphatics of adult rats sometimes bypass intervening lymph nodes and drain directly to the cisterna chyli. Others, however, have maintained that testicular lymph trunks uniformly first drain into one or more regional lymph nodes (2-4). To clarify this apparent discrepancy, we instilled India ink into rat testicular lymphatics along with intravascular exsanguination and replacement with Ringers lactate. This technique sharply delineates lymphatic drainage of the testicle.

### MATERIALS AND METHODS

Adult male rats, 15 from each strain of three (Dark A guoti, Lewis, Albino Swiss) were examined. Each rat was anesthetized in an ether jar supplemented by aqueous chloral hydrate (0.4ml, i.p.) ether inhalation and

atropine (0.5ml, s.c.). Both testes were exposed via laparotomy with extension on either side into the scrotal sacs. To facilitate visualization of testicular lymph trunks, India ink diluted 1:4 with distilled water was injected below the tunica magnified by a Zeiss-Microscope. Filling and migration of India ink from collecting lymph trunks were observed with microscopic enhancement. By blunt dissection, the dilated cisterna sac was seen filled with India ink particles floating freely, separate from adjacent lymph nodes. Thereafter, each rat was killed (ether overdosage) and the thoracic aorta infused with Ringers lactate and blood washed out via a catheter inserted into the right atrium. In this way, tissues and organs were flushed of blood and the resultant extreme background pallor provided a sharp contrast for India ink filled collecting lymph trunks of the testes.

### RESULTS

Although slight differences were observed among the various rat species, the patterns of lymphatic drainage were generally consistent. From  $\frac{1}{4}$  to  $\frac{1}{3}$  of collecting lymphatic trunks bypassed regional nodes and entered the cisterna chyli directly (Fig. 1). On the other hand, 40-60% of the trunks entered regional node(s) directly (Fig. 2) with the remainder bifurcating with a portion entering regional nodes or alternatively bypassing nodes to drain without interruption into the cisterna chyli (Fig. 3).

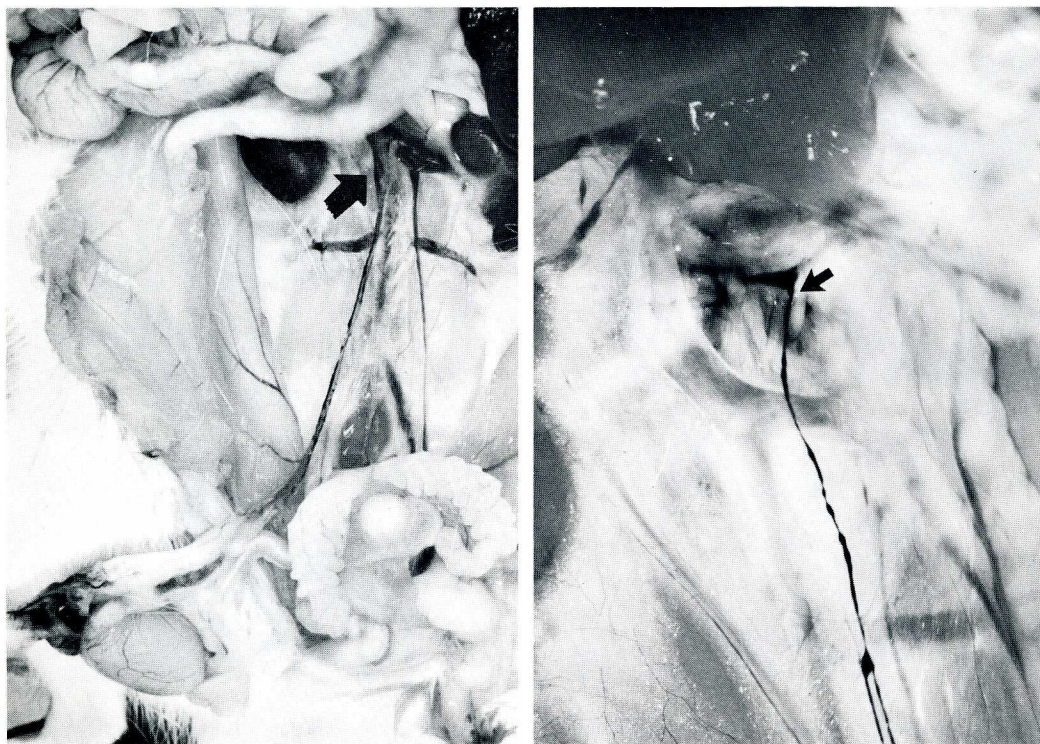

Fig. 1: a) A collecting testicular lymph trunk bypassing retroperitoneal lymph nodes and draining directly into the cysterna chyli (arrow). b) Higher power view (arrow) where the testicular collecting lymph trunk opens directly into the fluctuant cysterna chyli. This sac must be distinguished from renal hemolymph nodes that lie nearby.

## COMMENT

To resolve a long-standing controversy regarding rat testicular lymphatic drainage, we traced India ink filled testicular lymphatic trunks to the cysterna chyli after flushing the bloodstream with salt solution to intensify black contrast against a pale background. Whereas testicular collecting lymph trunks often drain into regional lymph nodes, they also commonly bypass regional nodes entirely to connect directly to the cysterna chyli. Using mercury to enhance lymphatic visualization, Engeset (1) first called attention to this unusual anatomic pattern. Mercury, however, tends to rupture tiny lymph channels and has all but been abandoned to visualize lymphatics. Tilney (2) on the other hand, maintains that rat testicular lymphatics

uniformly drain into regional nodes, a morphologic arrangement not supported by this study. Instead, lymphatic trunks either drain to the cysterna chyli bypassing regional lymph nodes, or bifurcate with some branches entering lymph nodes and others circumventing regional nodes and connecting with the cysterna chyli directly. It is noteworthy that a rat skin pedicle flap with an intact blood supply but devoid of lymphatics induces prolonged tissue allograft survival (5-7). Despite abundant lymphatic sinusoids within the connective framework of the testis (8) and the epididymis (9) these sites may prove to be immunologically privileged with early entry of transplant antigens into the bloodstream bypassing regional lymphoid tissue.

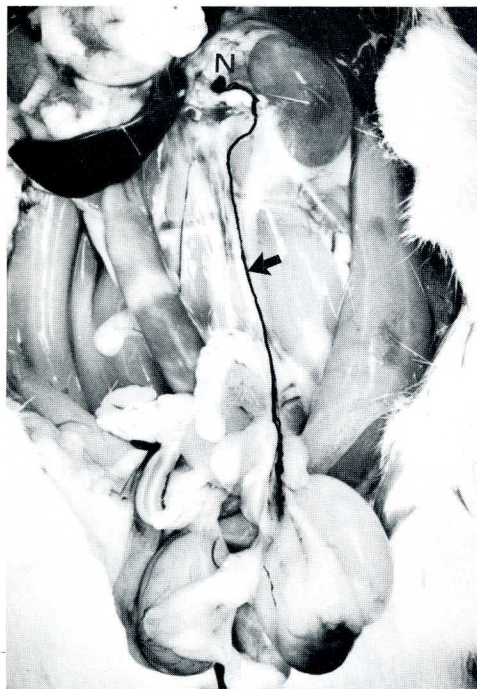

Fig. 2: A testicular collecting lymph trunk (arrow) drains cephalad and enters a renal hemolymph node (N).

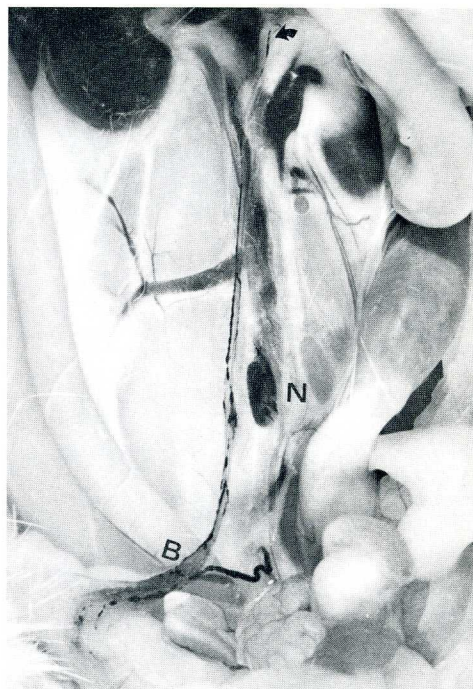


Fig. 3: Right collecting testicular trunk bifurcates at (B). One branch drains into a node (N), whereas the other runs cranially and opens into the cisterna chyli (arrow).

## REFERENCES

1. Engeset A: The role of peripheral lymph to the bloodstream. An x-ray study of the barrier theory. *J Anat* 93 (1959), 96-100.
2. Tilney NL: Patterns of lymphatic drainage in the adult laboratory rat. *J Anat* 109 (1971), 369-383.
3. Whitmore WF, RF Gittes: Afferent lymphatics. Their importance to immunologically privileged sites. *Surg Forum* 26 (1975), 338-340.
4. McCullough DL: Experimental lymphangiography. Experience with direct medium injection into the parenchyma of the rat testis and prostate. *Invest Urol* 13 (1975), 211-219.
5. Tilney WC, JL Gowans: The sensitization of rats by allografts transplanted to alymphatic pedicles of skin. *J Exp Med* 133 (1971), 951-962.
6. Merriam JC, NL Tilney: A humoral component in prolongation of alymphatic skin allografts in rats. *Surg Forum* 27 (1976), 336.
7. Tilney NL, WL Ford: Host cell prolongation in response to skin allografts in alymphatic pedicles. *Cell Imm* 14 (1974), 146-150.
8. Fawcett DW, WD Neaves, MN Flores: Comparative observations on intertubular lymphatics and the organization of the interstitial tissue of the mammalian testis. *Biol Reprod* 9 (1973), 500-532.
9. Kazeem AA: The assessment of epididymal lymphatics within the concept of immunologically privileged sites. *Lymphology* 16 (1983), 168-171.

**A. Kazeem**  
**Department of Clinical Pathology**  
**College of Medicine**  
**University of Lagos**  
**P.M.B. 12003**  
**Lagos, Nigeria**