

NON-OPERATIVE THERAPY COMBINED WITH LIMITED SURGERY IN MANAGEMENT OF PERIPHERAL LYMPHEDEMA

A. Zelikovski, M. Haddad, R. Reiss

Department of Surgery B, Beilinson Medical Center, Petah Tiqva, and Tel-Aviv University Sackler School of Medicine, Israel

ABSTRACT

Vigorous intermittent pneumatic compression combined with limited surgery for huge lymphedema of the extremities is described. The goal of operation is primarily to restore the distorted lymphedematous limb to a more normal shape to facilitate continued non-operative treatment.

Operative management for peripheral lymphedema is still of limited therapeutic advantage and in general is reserved for patients in whom non-operative treatment has failed. The many operations advocated for this disorder attest to their limited value. Radical excisional procedures promote considerable damage to the skin often leaving ugly scars, while "physiologic" operations such as lymphatic-venous or lymph-nodal shunts have not as yet been shown to be of long-term benefit. Followup over many years of patients with extremity lymphedema after radical excision often demonstrates recurrence of swelling which is sometimes more difficult to treat than the original condition prior to operation.

Elasticized stockings remain the mainstay of non-operative treatment. Because many patients with lymphedema, however, have a striking abnormal configuration of the leg or arm, measuring circumferences of the limb to obtain made-to-order stockinettes is impractical and would entail purchasing a

bizarre-shaped, grotesquely contrived support hose. To circumvent this problem and facilitate non-operative treatment, sequential intermittent pneumatic compression should be applied first to reshape the limb into a more normal configuration and then, a standard-shaped stockinette worn to maintain the reduction in edema. In our experience, this sequence of events has rarely failed, and when it does it characteristically is in patients with huge and grotesque lymphedema. In these individuals only is limited excisional surgery useful to reshape the extremity into a more normal configuration and allow continuation of non-operative "compression" therapy. Such "conservative" surgery is achieved by limited but careful excision of only surplus skin and subcutaneous tissue. After these distorted zones of abnormal pressure are removed and the limb (usually leg) has acquired a more optimal configuration a reasonably shaped tight elastic hose can be applied. These high pressure elastic stockinettes then further maintain reduced lymphedema.

∴ In this report, we describe our method for limited excisional surgery in eight patients. The major indication for operation was a limb with extremely severe and grotesque edema which even after sequential pneumatic compression was still unsuitable for fitting with a normal-shaped elastic stocking.

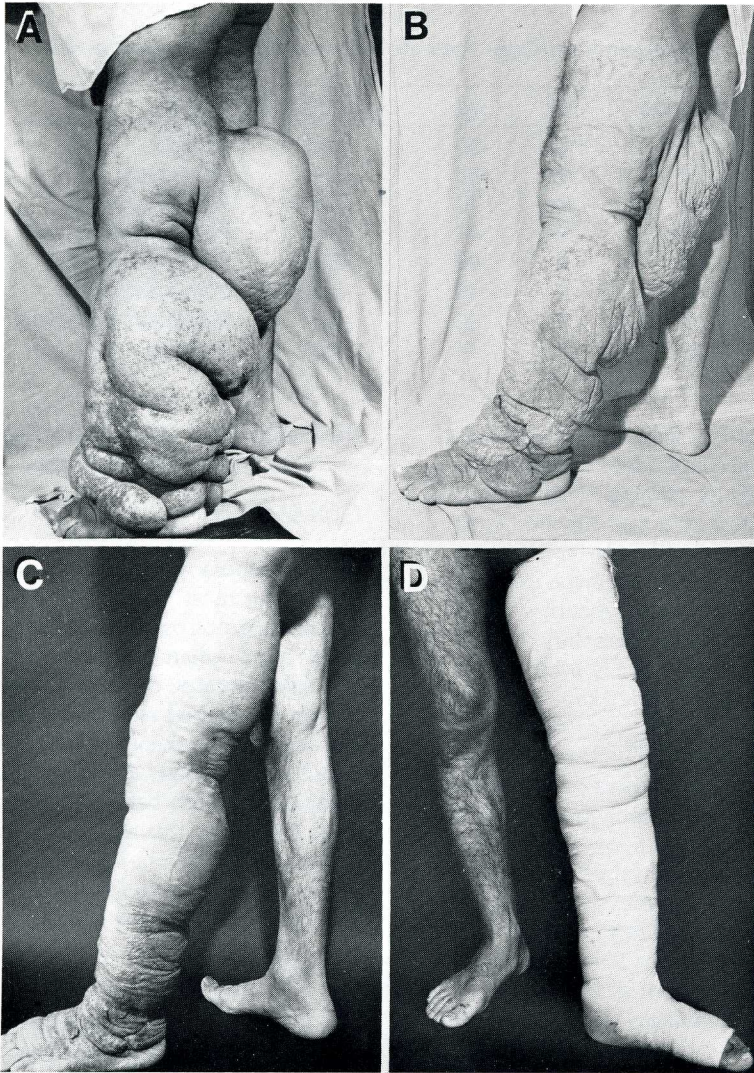


Fig. 1. (A) 50-year-old patient [Table 1, #1] with gigantic lymphedema of the leg. (B) Seven days after intermittent pneumatic compression [Lympha-press]. (C) Fourteen days after limited excision of redundant skin and subcutaneous tissue. (D) After fitting with "normal-shaped" elastic bandaging.

MATERIALS AND METHODS

1. Clinical Experience: Eight patients (4 males and 4 females) between 30 and 70 years (see Table 1) were studied.

2. Preparation of Patients: Patients were admitted to the hospital several days before operation for maximum and vigorous treatment of lymphedema by sequential pneumatic compression using the Lympha-

press device (1). Prophylactic antibiotics were also administered. Compression treatment was applied continuously until edema was evacuated and only surplus skin and subcutis remained. Reduction of weight in these patients was from 7 to 21 kg over a 3-7 day period. An example of limb reduction prior to operation is shown in Fig. 1 (A and B) (Patient number #1 from Table 1).

Table 1.
Clinical data on Eight Patients with Peripheral Lymphedema

Patient No.	Sex	Age	Limb Affected	Cause
1	M	50	leg	Trauma
2	M	30	leg	Congenital
3	M	70	leg	Post-erysipelas
4	M	45	leg	Post-erysipelas
5	F	60	arm	Post-mastectomy
6	F	48	arm	Post-mastectomy
7	F	50	leg	Post-groin dissection
8	F	47	leg	Trauma

3. Operation: A specially elevated stand constructed to accommodate the patient's lymphedematous leg allowed elevation to 45° leaving the surplus skin and subcutaneous tissue to hang loosely, thereby creating a more normal configuration of the extremity. Only redundant skin and subcutis were excised in one, or where necessary, two longitudinal incisions laterally and/or medially. Thereafter vacuum drains were inserted and the skin and subcutaneous layers closed separately. The leg was immediately bound with elastic bandages and placed into the Lympha-press sleeve and compression initiated at a low pressure (60-70mmHg). This method of intermittent sequential pressure minimized accumulation of fluid in the operative field, reduced pain, and seemingly accelerated wound healing. After 24-48 hours, dressings were changed, new tight elastic bandages were applied and the patient permitted to ambulate. Fourteen days after operation a much tighter, more normal shaped elastic stocking was now fitted without difficulty (*Fig. 1B and C*).

4. Outcome: No skin necrosis or wound infection occurred. The surplus skin and subcutaneous tissue removed weighed from 3.5 to 19 kg. Followup period was 2-5 years during which time only 2 patients (both with arm lymphedema) required additional treatment with Lympha-press. It is noteworthy, nonetheless, that these latter patients maintained a reduced arm size with elastic stockings for periods of 1-3 months. Patients with leg lymphedema, however, maintained a reduced limb size for up to five years without difficulty probably because

they fitted more easily into a high pressure normal-shaped elastic stocking.

COMMENT

Non-operative compression treatment is advised for most patients in whom lymphedema is not overly extensive. On the other hand, when "conservative" treatment has failed because of gigantic limb distortion, we opt for limited resection of the redundant skin and subcutaneous tissue. When combined with prompt, aggressive pneumatic compression both before and immediately after operation, this approach minimally traumatizes the limb, leaves no ugly scars and is much safer and more effective than more radical excisional operations.

REFERENCE

1. Zelikovski, A, M Haddad, R Reiss: Lympha-press, a new device for the treatment of lymphedema. *Lymphology* 13 (1980), 68.

A. Zelikovski, M.D.
Department of Surgery B
Beilinson Medical Center
Petah Tiqva, Israel 49 100