

VASCULAR REMODELING IN KAPOSI'S SARCOMA AND AVIAN HEMANGIOMATOSIS: RELATION TO THE VERTEBRATE LYMPHATIC SYSTEM

M. Dictor

Department of Pathology, University Hospital, Lund, Sweden

Kaposi's sarcoma (KS) is often defined as a low grade endothelial malignancy with metastatic potential, although Kaposi himself found this last point difficult to reconcile with the occurrence of bilateral lesions on the distal extremities (1). A number of observations in recent decades force a re-evaluation of the Kaposi lesion in terms of constituent cells and its relation to the vascular systems of both blood and lymph. Physicians have assumed that KS lacks an animal counterpart, but new insights suggest the relevance of natural animal models, specifically hemangiomas of fowl (2). In addition, certain characteristics of the present epidemic of KS in association with the acquired immunodeficiency syndrome (AIDS), such as the frequency of KS differing by risk group, suggest an independent infectious etiology in Kaposi's sarcoma.

Classical descriptions of the pathology of Kaposi's sarcoma regularly include dilated vascular spaces lined by elongated endothelial cells among which is a greater or lesser complement of spindle cells with vascular slits. These elements have been considered to form an amalgam of proliferating tissue possibly harboring other neoplastic mesenchymal elements in the guise of spindle cells.

Recent studies using immunohistochemistry and cell culture have reaffirmed the endothelial cell as the major proliferative constituent in KS (3-5). Prior to the AIDS epidemic, little interest was

accorded nascent lesions, which were often said to resemble granulation tissue. Large numbers of biopsies performed on macular lesions in recent years often reveal on histopathology aberrant dilated lymphatic-like channels. These can resemble granulation tissue when sclerosis supervenes, although a component of angiomatoid capillary proliferation may be present. In a histologic review of more than 110 cases of KS of the elderly, the author has seen a number of such nascent lesions, although not as frequently as in AIDS patients. The conclusion is that both clinical forms of KS have similar pathologic beginnings, and patients in the eighth decade of life (the mean age of Swedish patients with the disease) may be less likely to seek medical attention for initially unobtrusive macular lesions of the feet. Also, the rate of histologic stage progression varies among patients. Some may develop a spindle cell nodule in a matter of a few weeks, whereas others may retain the aberrant lymphatic (macular) stage for months. Recognition of the dynamic patterns of development of a single lesion replaces earlier concepts of separate "forms" of KS such as lymphangiomatous (6), angiomatous and sarcomatous (7). A four-stage scheme based on histogenesis is given in reference 8. Stage 1 involves aberrant endothelial growth and coupling between the venous circulation and lymphatic system; stage 2, the spindle cell nodule; stage 3, increased nuclear atypia in spindle cells; and stage

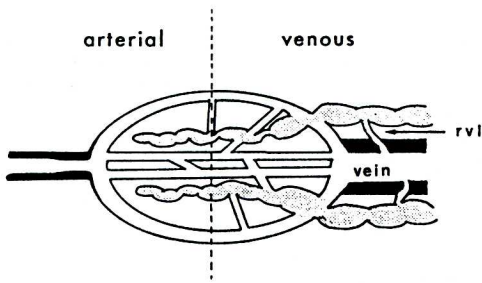


Fig. 1. Schematic representation of combinative lymphaticovenous remodeling. Shaded areas are lymphatics and lymphatic-like channels. Coupling initially involves venous capillaries and venules, although arterial capillaries may conceivably participate. Distal progression is morphologically apparent in radial venolymphatics, rvl.

4, angiosarcoma. The last stage has evolved in only 4% of our patients in Lund.

Immunohistochemistry has been used to define more precisely the endothelial cell of origin but with conflicting results. Monoclonal antibodies purported to be specific for endothelium exclusive of lymphendothelium did not react with cells in KS lesions (5), which was taken as evidence of lymphatic origin. Other monoclonal antibodies specific for blood vessel endothelium only have produced positive staining (4). The apparent contradiction stems from viewing KS as a malignant tumor arising in one or the other of two biologically separate types of endothelium, a premise with other drawbacks.

First, malignant change in lymphatic endothelium does not explain the fact that the lesions carry much blood, often out of proportion to the recognizable lymphatic component. Small areas of new capillary growth are not necessarily congruent with areas of proliferating lymphatics. Congruency would be expected if the blood vessels merely nourished "parenchymal" lymphatic endothelium, analogous to the situation in solid tumors of nonvascular type. Second, the idea of origin in blood vessels ignores the clinical and angiographic lymphaticovenous nature of KS. Finally, veins and lymphatics are biologically intimately related. Lymphatics

in man possibly arise from embryonic veins, and the genome may be assumed to ultimately control the dichotomous differentiation of endothelium, at least in the embryo.

These problems are resolved by taking into account the extensive remodeling of the blood capillary, venular and lymphatic beds during lesional development, which at the outset leads to connections between both vascular systems (Fig. 1) (8). Remodeling begins in any given site at the capillovenular level and tends to continue in the direction of blood flow in veins. This results in lesions developing along lymphatic and venous pathways such as portal zones and fibrous septa of the liver, as seen in Fig. 2.

Skin is rich in small blood vessels and lymphatics, and the broad expanse of dermis allows the spectrum of pathologic changes in KS to be observed more readily than in the crowded confines of hepatic portal zones, for example. Nevertheless, the pathogenetic events may be initiated in other sites, such as the muscularis mucosae of the gastrointestinal canal, septa and portal tracts of the liver, and marginal sinus area of lymph nodes. The first recognizable stage of cutaneous KS shows histologically the dissection of collagen bundles by jagged, aberrant lymphatic clefts. Their lymphatic nature is recognized when in the normal anatomical position around the superficial dermal venular plexus, forming so-called glomeruloid structures (Fig. 3). In addition, ultrastructural, histochemical, and immunohistochemical analysis confirm that the cells lining these clefts show features such as a partly absent basal lamina, lack of surrounding pericytes (9) and the presence of 5'-nucleotidase (1), which are more characteristic of lymphendothelium. The earliest clefts are bloodless in sections, but hemosiderin is frequently found in the lymphatic-like endothelium and adjacent fibroblasts lining collagen bundles. In a slightly later phase, glomeruloid structures diminish in size and number to be replaced by anastomosing blood-filled spaces lined by

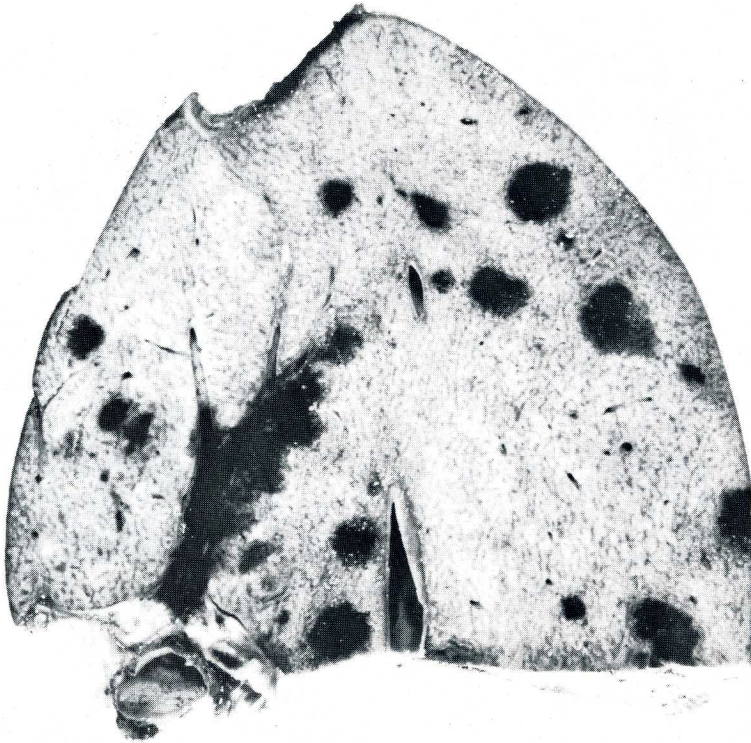


Fig. 2. Cut surface of liver shows multicentric KS with concentration about a major septum. The other foci may arise in portal tracts.

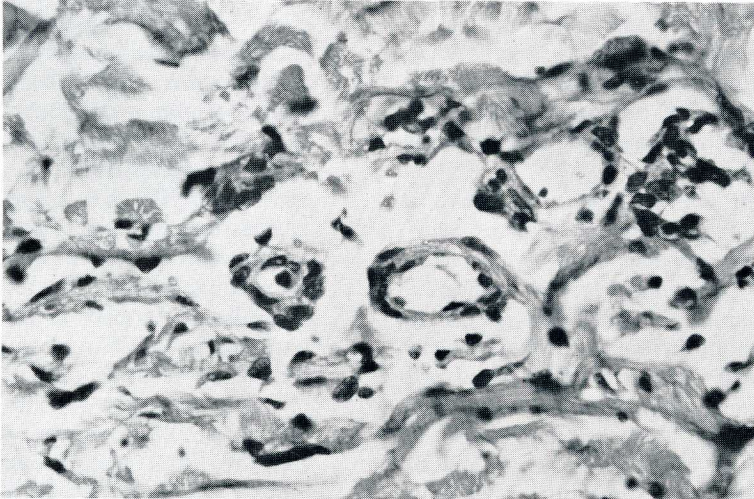


Fig. 3. Glomeruloid structure containing central blood capillary and venule within aberrant lymphatic cleft.

cells more closely resembling blood vascular endothelium. The transition between these two states is also marked by disruption of the cleft lining with

perifocal hemorrhage and sclerosis. Delineation of these stages is facilitated by examples in which the changes occur in "pure" form, but many specimens show

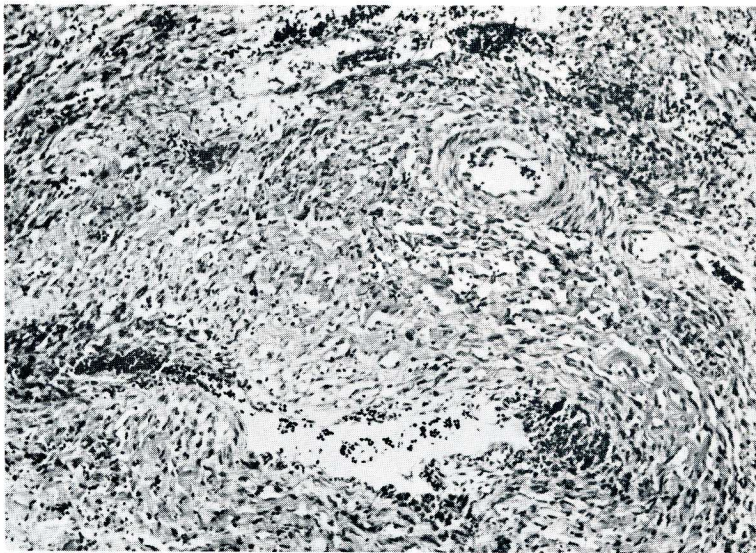


Fig. 4. Radial venolymphatics penetrate media of vein below but not adjacent artery. Note hemorrhage at top.

transitions. In general, spindle cells arise after blood flow is established between the venous side of the circulation and aberrant lymphatic channels. Spindle cells stain variably for Factor VIII-related antigen and fucosyl moieties (by *Ulex europaeus* I lectin binding) and lack Weibel-Palade bodies. These cells may represent transformed endothelial clones, and Dorfman in this symposium has suggested suitable methods for studying this question.

As the above sequence of events is repeated along progressively larger veins, radial venolymphatics become the hallmarks of lymphaticovenous union. Jagged channels histologically similar to nascent lesions in biopsies of skin penetrate the walls of veins (*Fig. 4*) affording potential linkage between both vascular systems beyond the capillovenular level. This is observed in the hilum of lymph nodes, gastrointestinal submucosa, subcutaneous and perivisceral fat and the fibrous septa of the liver, for example. Hemorrhage tends to be more prominent about these structures, conceivably due to greater pressures acting on the incompetent venolymphatics. That venular glomeruloid structures and radial venolym-

phatics account for angiographically demonstrated venolymphatic anastomoses is by inference. It is strongly suggested by careful histological, immunohistochemical, and electronmicroscopical analysis of lesional development. Independent proof might require simultaneous histographic and lymphographic/angiographic study of single lesions. Newly devised infiltrative lymphographic techniques could be applied in skin lesions (11).

Our comparison of AIDS-related and non-AIDS KS suggests that the progression upwards along the venous system may be related to the presence of an immune defect. Sections from ten autopsies performed on patients with KS but without AIDS over a 25-year period in Sweden revealed only a solitary focus of venolymphatics in one patient, and that patient had received ACTH. This compares with their presence in all of nine AIDS patients with KS at autopsy (8). The question needs more study, in particular with additional comparison of autopsy material in endemic African KS, since such cases have been reported to show structures corresponding to radial venolymphatics, though presumably outside the context of a clinical immunode-

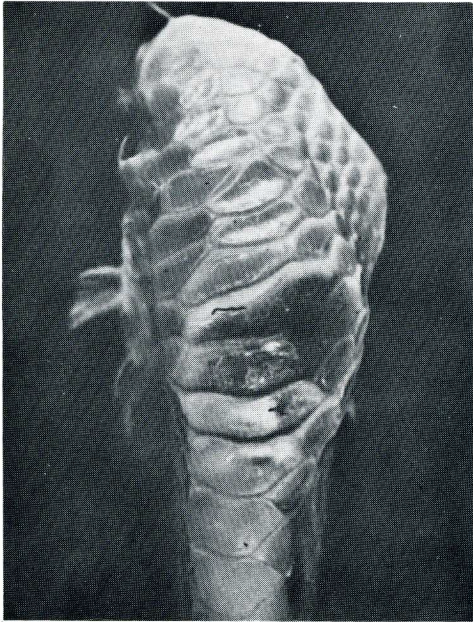


Fig. 5. Macular lesion of hemangiomas on hock of chicken. [Courtesy of Dr. B. Jarplid, reprinted from *J. Comp. Pathol.*, ref. 15.]

iciency syndrome. Debilitating diseases are often described in African KS, however, and other factors affecting immune function may be present.

Castleman's disease (angiofollicular hyperplasia), a non-malignant lymphoid lesion recently associated with KS (12), represents a disturbance in B-cell differentiation which may show systemic involvement. Data in the Swedish Cancer Registry confirm lymphoma as the most common second primary tumor in patients with KS (Dictor, M, Attewell, R: unpublished data). The possibility exists that the altered endothelial growth processes in KS are somehow related to B-lymphocyte maturation, a prospect made even more alluring by analogy to the animal model described below.

The notion that KS represents a phenomenon unique to man may need revision. We have recently drawn attention to the striking similarities between avian hemangiomas, a multicentric vascular tumor of chickens and Kaposi's sarcoma (2). Fig. 5 demonstrates an early macular lesion in the skin of a White

Leghorn fowl. The clinical features of each are given in *Table 1*. Both entities are related to lymphoma. In the case of the avian tumors, this is due to the lymphoid leukosis group of retroviruses to which belong the agents causing hemangiomas and lymphomas (13). Hemangiomas is apparently most commonly associated with visceral lymphomatosis (14,15) and shows vertical transmission. Avian leukosis viral DNA becomes integrated in the genome of endothelial tumor cells, but oncogenes possibly involved in tumorigenesis have not been definitely identified. However, recently Robinson et al. (16) described rapid induction of angiosarcomas in chickens using a leukosis virus which transduced a portion of the gene (c-erbB) responsible for epidermal growth factor receptor. It remains to be seen whether this oncogene is also involved in naturally occurring hemangiomas.

Spontaneous regression is often noted in both diseases. For fowl, this may be a result of natural immunity (13). KS appears to be modulated by immune function and in many patients with acquired immunodeficiency lesions regress as immune function improves.

Avian hemangiomas has been the focus of few pathologic studies. Yet the salient pathologic features presented in *Table 2* also correspond in a striking manner to Kaposi's sarcoma. Most importantly, both lesions initially resemble an innocuous dissecting proliferation of endothelium and evolve into sarcoma-like tumors or even frank angiosarcoma, as shown in *Fig. 6*.

It is not known whether the avian tumors involve lymphatics. However, intravenous extension has been illustrated (17), and this is typical of endemic African KS, in particular. Studies should be undertaken to map the progression of these vascular avian tumors from their inception, such as has been done in KS. This would include the use of immunohistochemistry and electron microscopy to distinguish between lymphatic and blood vascular endothelium. Lymphaticovenous connections might also be sought by

Table 1
Comparison of Clinical Features in
Kaposi's Sarcoma and Avian Hemangiomatosis

	<u>Kaposi's Sarcoma</u>	<u>Avian Hemangiomatosis</u>
Etiology	Probably virus	Retrovirus in lymphoid leukosis group
Epidemiology	Sporadic & epidemic; increased incidence in some immunodeficiency states, increased lymphoma	Sporadic & epidemic; associated with visceral lymphomatosis
Sites	Distal skin initially; multicentric, internal organs	Distal skin initially; multicentric, internal organs
Regression	Yes	Yes
Metastasis	Rare	Not documented
Malignant Progression	Yes	Yes

Table 2
Comparison of Salient Histologic Features in
Kaposi's Sarcoma and Avian Hemangiomatosis

	<u>Kaposi's Sarcoma</u>	<u>Avian Hemangiomatosis</u>
1st stage	Proliferating lymphatic & blood vessel endothelium	Proliferating endothelium
2nd stage	Spindle cell growth with slits	spindle cell growth with slits
3rd stage	Fibrosarcoma-like	Fibrosarcoma-like
Dilated spaces lined by benign endothelium	Yes	Yes
Spindle cell growth in veins	Yes	Yes

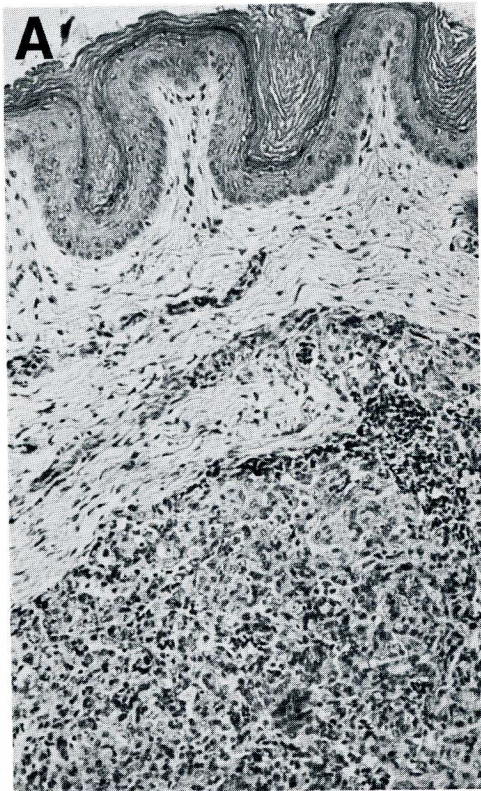


Fig. 6 (at left). (A) Closely spaced atypical endothelial cells and nucleated red cells in subcutaneous lesion in chicken. [Courtesy of Dr. B. Jarplid, reprinted from *J. Comp. Pathol.*, ref. 15.] (B) Stage 3 KS lesion with sarcomatoid atypia and loss of vascular slits.

applying angiographic techniques. With continued advances in molecular biology, the involvement of both vascular systems, if found, could eventually shed light on the genetic origins of the vertebrate lymphatic system.

ADDENDUM

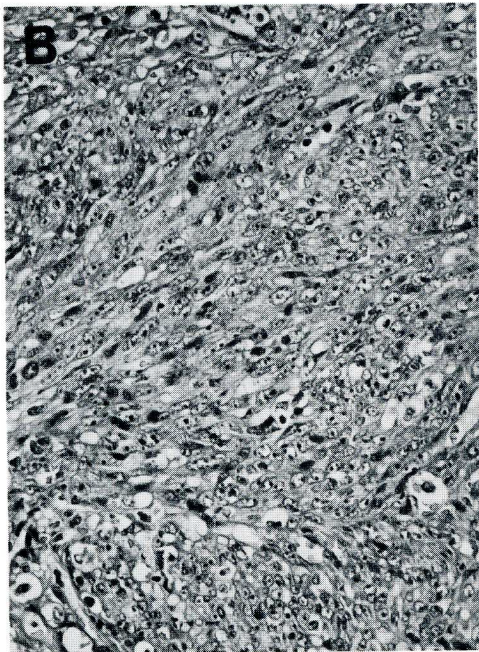
Recent transfection studies of KS have tentatively implicated rearrangements of DNA flanking an unusual oncogene which codes for a protein homologous to angiogenic factors (18,19).

ACKNOWLEDGEMENTS

This work is supported by the John och Augusta Perssons stiftelse for vetenskaplig medicinsk forskning, the Royal Physiographical Society of Lund, and the Medical Faculty of the University of Lund.

REFERENCES

1. Kaposi, M: Idiopatisches multiples pigment-sarkom der Haut. *Archiv. Dermatol. Syph.* 4 (1872), 265.
2. Dictor, M, B Jarplid: The cause of Kaposi's sarcoma: An avian retroviral analog. *J. Am. Acad. Dermatol.* (in press).
3. Gioanni, J, F Ettore, C Mazeau, et al: *In vitro* study of the cell populations in two cases of Kaposi's sarcoma. *Arch. Dermatol. Res.* 279 (1986), 26.
4. Rutgers, JL, R Wiczorek, F Bonetti, et al: The expression of endothelial cell surface antigens by AIDS-associated Kaposi's sarcoma—evidence for a vascular endothelial cell origin. *Am. J. Pathol.* 122 (1986), 493.
5. Jones, RR, J Spaul, C Spry, et al: Histogenesis of Kaposi's sarcoma in patients with and without acquired immune deficiency syndrome (AIDS). *J. Clin. Pathol.* 39 (1986), 742.
6. Ronchese, F, AB Kern: Lymphangioma-like tumors in Kaposi's sarcoma. *Arch. Dermatol.* 75 (1957), 418.



7. Kalengayi, MMR, L Kashala: Clinicopathologic features of Kaposi's sarcoma in Zaire. IARC Sci. Publ. 63 (1984), 559.
8. Dictor, M: Kaposi's sarcoma: Origin and significance of lymphaticovenous connections. Virchows Arch. (Pathol. Anat.) 409 (1986), 23.
9. McNutt, NS, V Fletcher, MA Conant: Early lesions of Kaposi's sarcoma in homosexual man—an ultrastructural comparison with other vascular proliferations in skin. Am. J. Pathol. 111 (1983), 62.
10. Beckstead, JH, GS Wood, V Fletcher: Evidence for origin of Kaposi's sarcoma from lymphatic endothelium. Am. J. Pathol. 119 (1985), 294.
11. Bollinger, A, K Jager, F Sgier, et al: Fluorescence microlymphography. Circulation 64 (1981), 1195.
12. Frizzera, G, PM Banks, G Massarelli, et al: A systemic lymphoproliferative disorder with morphologic features of Castleman's disease. Am. J. Surg. Pathol. 7 (1983), 211.
13. Burstein, H, M Gilead, U Bendheim, et al: Viral aetiology of haemangiosarcoma outbreaks among layer hens. Avian Pathol. 13 (1984), 715.
14. Fredrickson, RN, BR Burmester, W Okazaki: Transmission of virus from field cases of avian lymphomatosis. II. Development of strains by serial passage in line 151 chickens. Avian Dis. 9 (1964), 82.
15. Jarplid, B: Haemangioendotheliomas in poultry. J. Comp. Pathol. 71 (1961), 370.
16. Robinson, HL, BD Miles, SE Tracy: Avian leukosis virus-induced cancer: The induction of erythroblastosis by proviral insertions into or new transductions of c-erbB. In: *Animal Models of Retrovirus Infection and Their Relationship to AIDS*. Salzman, LA (Ed.), Academic Press, Orlando (1986), 169-192.
17. Purchase, HG, LN Payne: Leukosis/sarcoma group. In: *Disease of Poultry*. Hofstad, MS (Ed.), 8th Ed., Ames, IA, Iowa State University Press (1984), 387.
18. Delli Bovi, P, C Basilico: Isolation of a rearranged human transforming gene following transfection of K.S. DNA (NIH 3T3 transfection/molecular cloning/c-fm s protooncogene). Proc. Natl. Acad. Sci. 84 (1987), 5660-5664.
19. Delli Bovi, P, AM Curatola, FG Kern, et al: An oncogene isolated by transfection of Kaposi's sarcoma DNA encodes a growth factor that is a member of the FGF family. Cell 50 (1987), 729-737.

Michael Dictor, M.D.
Senior Pathologist
Department of Pathology
University Hospital
Solvegatan 25
221 85 Lund
SWEDEN