

## HUMAN IMMUNODEFICIENCY VIRUS-ASSOCIATED CHANGES IN GERMINAL CENTERS OF LYMPH NODES AND RELEVANCE TO IMPAIRED B-CELL FUNCTION

K. Tenner-Racz

Department of Haematology, Allgemeines Krankenhaus St. Georg, Hamburg, West Germany

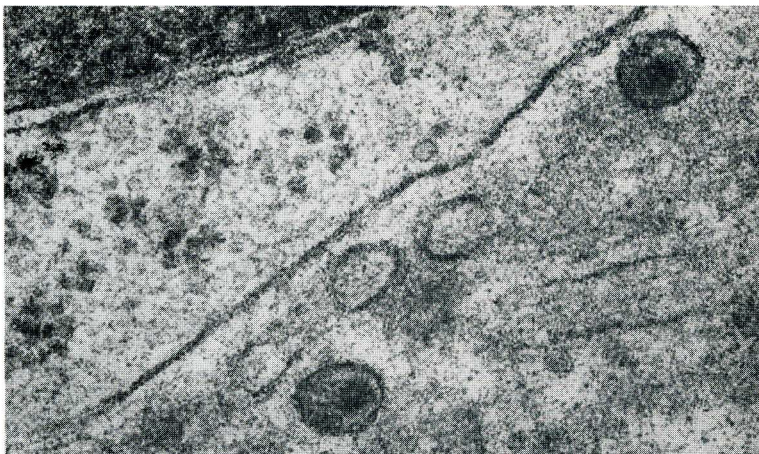The acquired immunodeficiency syndrome (AIDS) and AIDS-related conditions are characterized by a progressive loss of immunity. The spectrum of immunologic abnormalities is broad. One of the most prominent features of the disease is the functional depression and different degree of depletion of CD4<sup>+</sup> lymphocytes. The causative agent, the human immunodeficiency virus type-1 (HIV-1), possesses a highly specific tropism for cells carrying the CD4 receptor (1-4). Thus, its main targets are lymphocytes and cells of the monocyte/macrophage lineage (5-10) including follicular dendritic cells (11-14) and Langerhans cells (15,16).

Because of the central role of CD4<sup>+</sup> lymphocytes in the immune regulation, their loss and impaired function explain many immune disorders observed in HIV-1 infection. The CD4<sup>+</sup> T-cell subset was originally designated as "helper" cells because they were found to be critical to *in vitro* activation, maturation of, and antibody secretion by B-cells. Paradoxically, HIV-1 infected individuals with diminished CD4<sup>+</sup> lymphocytes show a variety of abnormalities indicating an *in vivo* B-cell activation (17-24). The patients have hyperglobulinemia; as peripheral B-cells secrete spontaneously increased levels of immunoglobulins. The mitogenic responses to T-dependent as well as T-independent

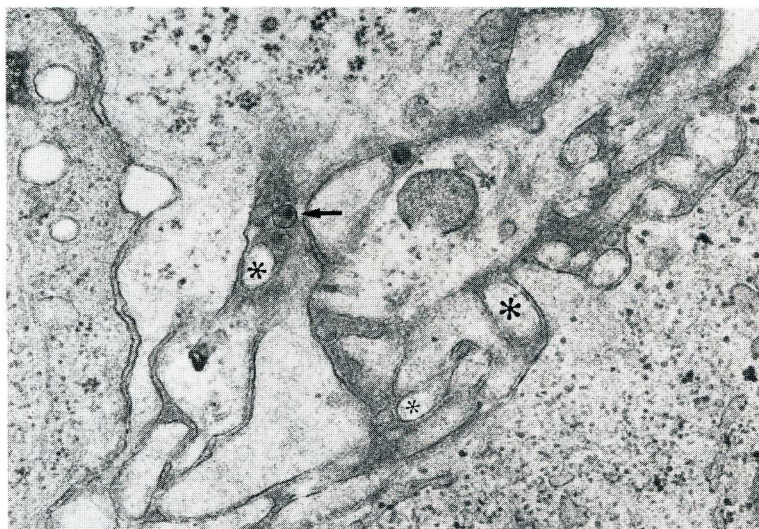mitogens are also impaired. In addition, they have an impaired ability to mount both primary and secondary humoral responses. Disturbance of CD4<sup>+</sup> lymphocytes cannot account for these abnormalities alone because impaired B-cell function has been demonstrated even in asymptomatic individuals with preserved T-cell function and counts (23).

The mechanism(s) of this B-cell imbalance is not known, although, infection with Epstein-Barr virus (EBV) or cytomegalovirus (CMV) has been proposed. However, there are data suggesting that hyperglobulinemia can be independent of EBV infection or reactivation (24), and in HIV-infected persons, cells spontaneously secreting immunoglobulins are not EBV infected (25,26). Furthermore, in pediatric or transfusion-related HIV-infection, B-cell abnormalities have been observed even in the absence of EBV or CMV infection (27,28).

Recent studies indicate that crude viral preparations of HIV-1 or live HIV are potent B-cell activators *in vitro* (29-31). It is known that the most constant finding in HIV-1-induced persistent generalized lymphadenopathy (PGL) is an exuberant activation of the B-dependent zone of the lymph node (for review, see ref. 32). The histologic manifestation of this activation is a longstanding germinal center reaction with large irregularly shaped follicles. Therefore, the analysis



*Fig. 1. Cell-free HIV-1 particles in a germinal center of a lymph node. PGL. Original magnification:  $\times 45,000$ .*



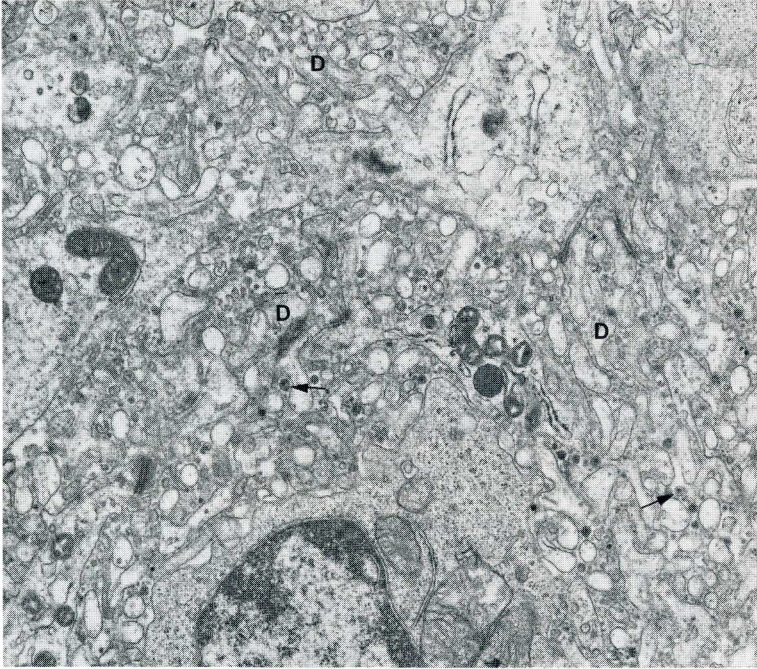
*Fig. 2. Part of a germinal center of a lymph node removed 2 weeks after seroconversion. Processes of FDC (asterisks) show no ultrastructural changes. The number of virions (arrow) is low. Original magnification:  $\times 20,000$ .*

of germinal centers (GC) in PGL can offer valuable data bearing on the pathogenesis of the disease.

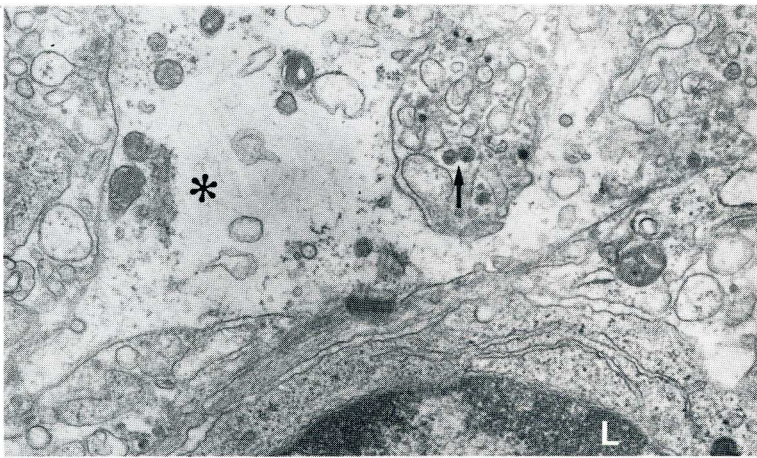
#### *Presence of HIV-1 in GC*

In 1984, Armstrong and Horne reported that GC from patients with PGL or AIDS-related Kaposi's sarcoma harbor retrovirus particles (33). Soon after, we confirmed this finding (34). The virions are located between the cell processes of

follicular dendritic cells (FDC) (Figs. 1-4). This consistent finding has led to emphasis on the diagnostic value of electron microscopic examination of lymph nodes from patients with PGL or AIDS (32,35,36). Virions can be seen in GC early in the course of infection. We examined lymph nodes obtained 2 to 6 weeks after seroconversion. At this time, GC already contained a few virions and no ultrastructural changes of FDC could be detected (Fig. 2). In contrast, GC in



*Fig. 3. Extensive proliferation of dendrites (D) of FDC. Many cell-free virions (arrows). Compare with Fig. 2. Longstanding PGL. Original magnification:  $\times 15,000$ .*



*Fig. 4. Degenerating FDC (asterisk) in longstanding lymphadenopathy. Retrovirus particles (arrow) in vicinity of degenerating FDC. Lymphocyte (L) without signs of cell damage. Original magnification:  $\times 20,000$ .*

lymph nodes with longstanding lymphadenopathy harbor many HIV. Hyperplasia (Fig. 3) and different degrees of degeneration of FDC (Fig. 4 and 5) accompany virus accumulation.

The intrafollicular accumulation of HIV-1 during the course of disease is probably due to continuous virus trapping and virus production inside the GC. Germinal centers contain a considerable

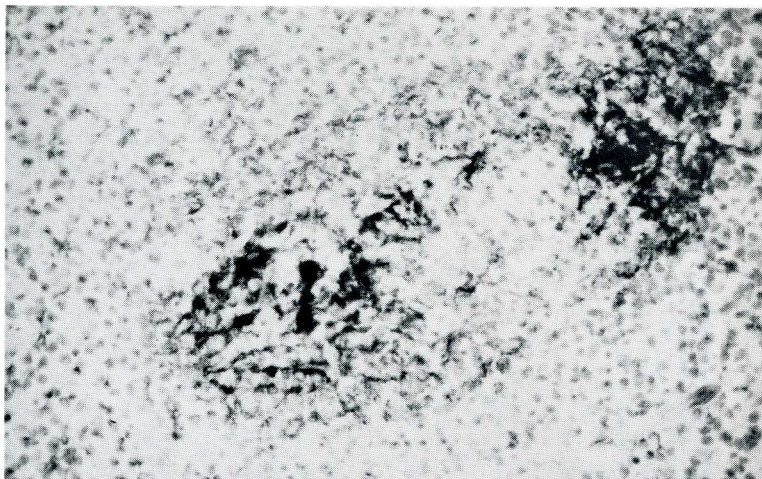


Fig. 5. Severe destruction of FDC network. Immunoperoxidase staining with monoclonal antibody to FDC. Original magnification:  $\times 100$ .

number of cells carrying the CD4 receptor. There are CD4<sup>+</sup> T-cells, the average percentage of which can be as high as 25% of the total cell population of GC. Macrophages and FDC also express the CD4 molecule at a low density (37). Therefore, it is not surprising that budding profiles on FDC (11,12,14,38), lymphocytes and macrophages (14) have been demonstrated in the GC.

Retrovirus particles persist in GC of infected individuals for long periods of time. Examining repeated biopsy specimens, we detected HIV-1 ultrastructurally both in the first and the second lymph nodes removed at up to 25 month intervals (14,39).

#### *Presence of structural proteins of HIV-1 in GC*

Further evidence for infection of GC can be achieved by immunostaining of frozen sections with monoclonal antibodies against *gag* proteins, p18, p24 (13,32,40-42) or with anti-gp160 of HIV-1 (39). Each of these viral proteins can be visualized in GC. The reaction is highly sensitive and can be used for diagnostic purposes (13,32,40,42). In our material, delicate aggregates of *gag* proteins were seen as early as 2 weeks after seroconversion (Fig. 6). In longstanding

lymphadenopathy the amount of structural proteins of HIV-1 is high and it can be detected as long as GC or remnants thereof are present (40,42). Double label studies demonstrate a close association of viral proteins with FDC (13,40,42). The FDC exhibit different degrees of destruction, and deposits of viral proteins can regularly be seen in the neighborhood of FDC destruction.

The mechanism responsible for the destruction of FDC in HIV-1 infection is probably complex. Virus replication in FDC can result in cytolysis. Cytotoxic T-cells could also have a role in this process. In PGL, CD8<sup>+</sup> lymphocytes are often arranged in groups corresponding to the FDC destruction (43). When double immunolabeling is applied, cells reacting with *gag* proteins can be seen in the centers of these clusters of CD8<sup>+</sup> T-cells (42).

#### *Presence of cells expressing HIV-1 RNA in GC*

A highly sensitive <sup>35</sup>S-labeled RNA probe of HIV-1 has been developed by Harper et al. (44,45). Results of *in situ* hybridization with this probe revealed that the majority of cells expressing viral RNA were located in the GC (39,46). Performing *in situ* hybridization on serial

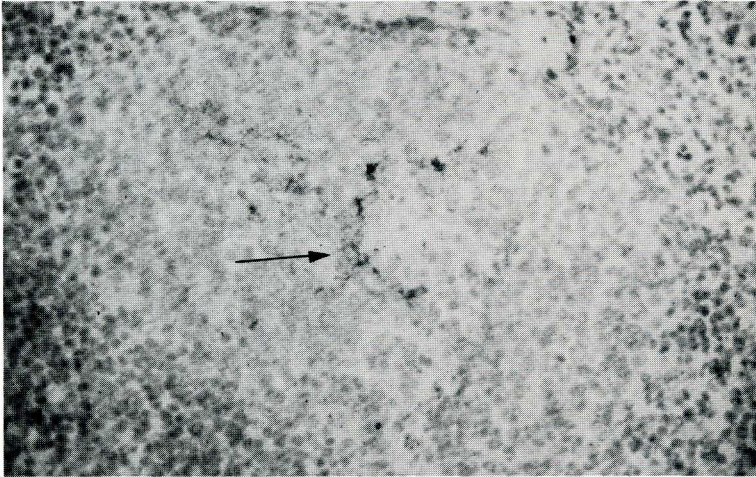


Fig. 6. Delicate deposits of p24 of HIV-1 (arrow) in a germinal center 2 weeks after seroconversion. Alkaline phosphatase anti-alkaline phosphatase immunoreaction. Original magnification:  $\times 100$ .

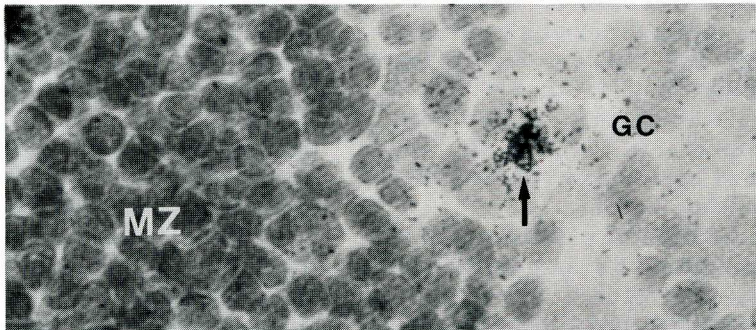


Fig. 7. Demonstration of a cell with RNA of HIV-1 (arrow) in a germinal center by in situ hybridization. Note the different diffuse grain density in germinal center (GC) and mantle zone (MZ). Original magnification:  $\times 400$ .

sections from lymph nodes, we noted that labeled cells often represented infected foci as judged by positivity in the same area of GC on subsequent cutting levels. In addition to hot spots, a relative high grain density diffusely distributed over the GC could be seen (Fig. 7). Because the background grain count over the mantle zone or lymphoid parenchyma was low and electron microscopically many free virions could be found, we assumed that the relatively high diffuse grain density is due or partly due to these virus particles.

## CONCLUSIONS

The data presented indicate that the GC of lymph nodes, and probably those of other organized lymphoid tissues, are infected by HIV-1 and represent an important virus reservoir where the causative agent can persist indefinitely. It is reasonable to assume that FDC play a central role in this process. These antigen trapping, presenting and retaining cells in performing their physiologic function capture HIV-1 early in the course of disease. Deposited on FDC, the virus

finds a sufficient number of permissive cells to infect and destroy. As the disease progresses, virus accumulation and continuous disintegration of GC occur.

HIV-1 and viral proteins held on the antigen presenting cells could act immunologically in a similar fashion as *in vitro* and be responsible for the B-cell activation and its morphologic manifestation, the exuberant follicular hyperplasia in PGL. Continuous loss of FDC could contribute to the diminished ability of HIV-1 infected patients to develop specific humoral immunity to neoantigens.

#### ACKNOWLEDGEMENTS

Part of this work was performed in collaboration with M. Dietrich, P. Kern, P. Racz (Berhard-Nocht-Institute for Tropical Medicine); S. Gartner, M. Popovic (Laboratory of Tumor Cell Biology, National Cancer Institute of Bethesda, USA); J.-C. Gluckman (Laboratoire de Biologie et Genetique deficite d'Immunitaire, Paris, France) and G. Janossy (Department of Immunology, Royal Free Hospital, London, UK).

Supported by grants from Bundesministerium fur Jugend, Familie, Frauen und Gesundheit, Bonn, and Korber-Stiftung, Hamburg.

#### REFERENCES

1. Klatzmann, D, F Barre-Sinoussi, MT Nugeyre, et al: Selective tropism of lymphadenopathy-associated virus (LAV) for helper-inducer T lymphocytes. *Science* 225 (1984), 59.
2. Klatzmann, D, E Champagne, S Chamaret, et al: T-lymphocyte T4 molecule behaves as the receptor for the AIDS retrovirus. *Nature* 312 (1984), 767.
3. Popovic, M, E Read-Connole, RC Gallo: T4 positive human neoplastic cell lines susceptible to and permissive for HTLV-III. *Lancet* ii (1984), 1472.
4. Dalgleish, AG, PCL Beverly, PR Clapham, et al: The CD4 (T4) antigen is an essential component of the receptor for the AIDS retrovirus. *Nature* 312 (1984), 763.
5. Gartner, S, P Markovits, DM Markovitz, et al: The role of mononuclear phagocytes in HTLV-III/LAV infection. *Science* 233 (1986), 215.
6. Gartner, S, P Markovits, DM Markovitz, et al: Virus isolation from and identification of HTLV-III/LAV-producing cells in brain tissue from a patient with AIDS. *JAMA* 256 (1986), 2365.
7. Ho, DD, T Rota, MS Hirsch: Infection of monocyte/macrophages by human T lymphotropic virus type III. *J. Clin. Invest.* 77 (1986), 1712.
8. Nicholson, JKA, GD Gross, CS Callaway, et al: *In vitro* infection of human monocytes with human T-lymphotropic virus type III/lymphadenopathy-associated virus (HTLV-III/LAV). *J. Immunol.* 137 (1986), 322.
9. Popovic, M, E Read-Connole, S Gartner: Biological properties of HTLV-III/LAV: A possible pathway of natural infection. *Ann. Inst. Pasteur*, 137D (1986), 413.
10. Popovic, M, E Read-Connole, S Gartner: HTLV-III/LAV infection of mononuclear phagocyte cells *in vivo* and *in vitro*. *UCLA Symp. Molec. Cell Biol. New Series* 43 (1987), 161.
11. Armstrong, JA, R Horne: Follicular dendritic cells and virus-like particles in AIDS-related lymphadenopathy. *Lancet* ii (1984), 370.
12. Armstrong, JA, RL Dawkins, R Horne: Retroviral infection of accessory cells and the immunologic paradox in AIDS. *Immunol. Today* 6 (1985), 121.
13. Tenner-Racz, K, P Racz, M Bofill, et al: HTLV-III/LAV viral antigens in lymph nodes of homosexual men with persistent generalized lymphadenopathy and AIDS. *Am. J. Pathol.* 123 (1986), 9.
14. Tenner-Racz, K, P Racz, S Gartner, et al: Ultrastructural analysis of germinal centers in lymph nodes of patients with HIV-1-induced persistent generalized lymphadenopathy: Evidence for persistence of infection. *Prog. AIDS Pathol.* 1 (1988) (*in press*).
15. Tschachler, E, V Groh, M Popovic, et al: Epidermal Langerhans cells: A target for HTLV-III/LAV infection. *Invest. Dermatol.* 88 (1987), 233.
16. Braathen, LR, G Ramirez, RDF Kunze, et al: Langerhans cells as primary target cells for HIV infection. *Lancet* ii (1987), 1094.
17. Gottlieb, MS, R Schroff, HM Schanker, et al: Pneumocystis carinii pneumonia and mucosal candidiasis in previously healthy homosexual men. Evidence of a new acquired cellular immunodeficiency. *N. Eng. J. Med.* 305 (1981), 1425.

18. Siegal, FP, C Lopez, GS Hammer, et al: Severe acquired immunodeficiency in homosexual males, manifested by chronic perianal ulcerative herpes simplex lesions. *N. Engl. J. Med.* 305 (1981), 1439.
19. Stahl, RE, AE Friedman-Kien, R Dubin, et al: Immunologic abnormalities in homosexual men: Relationship to Kaposi's sarcoma. *Amer. J. Med.* 73 (1982), 171.
20. Ammann, AJ, G Schiffman, D Abrams, et al: B-cell immunodeficiency in acquired immunodeficiency syndrome. *JAMA* 251 (1983), 1447.
21. Lane, HC, H Masur, LC Edgar, et al: Abnormalities of B-cell activation and immunoregulation in patients with the acquired immunodeficiency syndrome. *N. Engl. J. Med.* 309 (1983), 453.
22. Zolla-Pazner, S: B-cells in the pathogenesis of AIDS. *Immunol. Today* 5 (1984), 289.
23. Ballet, J-J, G Sulcebe, L-J Couderc, et al: Impaired anti-pneumococcal antibody response in patients with AIDS-related persistent generalized lymphadenopathy. *Clin. Exp. Immunol.* 88 (1987), 479.
24. Mizuma, H, S Zolla-Pazner, S Litwin, et al: Serum IgD elevation is an early marker of B cell activation during infection with the human immunodeficiency virus. *Clin. Exp. Immunol.* 68 (1987), 5.
25. Crawford, DH, I Weller, V Iliescu, et al: Epstein-Barr (EB) virus infection in homosexual men in London. *Brit. J. Vener. Dis.* 60 (1984), 258.
26. Crawford, DH, I Weller, V Iliescu: Polyclonal activation of B cells in homosexual men. *N. Engl. J. Med.* 311 (1984), 536.
27. Rubinstein, A, M Sicklick, A Gupta, et al: Acquired immunodeficiency with reversed T4/T8 ratios in infants born to promiscuous and drug-addicted mothers. *JAMA* 249 (1983), 2350.
28. Groopman, J, J Mullins, J Sullivan, et al: Virologic studies in transfusion-related AIDS. *Clin. Res.* 32 (1984), 370A.
29. Pahwa, S, R Pahwa, C Saxinger, et al: Influence of the human T-lymphotropic virus/lymphadenopathy-associated virus on functions of human lymphocytes: Evidence for immunosuppressive effects and polyclonal B-cell activation by banded viral preparations. *Proc. Nat. Acad. Sci. USA* 82 (1985), 8198.
30. Yachaoan, R, RR Redfield, S Broder: Mechanisms of B cell activation in patients with acquired immunodeficiency syndrome and related disorders. Contribution of antibody-producing cells, of Epstein-Barr virus-infected cells, and of immunoglobulin production induced by human T cell lymphotropic virus type III/lymphadenopathy associated virus. *J. Clin. Invest.* 78 (1986), 439.
31. Burkes, RL, W Abo, AM Levine, et al: Characterization of immunologic function in homosexual men with persistent generalized lymphadenopathy and acquired immune deficiency syndrome. *Cancer* 59 (1987), 731.
32. Racz, P, K Tenner-Racz, C Kahl, et al: The spectrum of morphologic changes in lymph nodes from patients with AIDS or AIDS-related complex. *Prog. Allergy* 37 (1986), 81.
33. Armstrong, JA, R Horne: Follicular dendritic cells and virus-like particles in AIDS-related lymphadenopathy. *Lancet* ii (1984), 370.
34. Tenner-Racz, K, P Racz, M Dietrich, et al: Altered follicular dendritic cells and virus-like particles in AIDS and AIDS-related lymphadenopathy. *Lancet* i (1985), 105.
35. Diebold, J, CL Marche, J Audouin, et al: Lymph node modification in patients with the acquired immunodeficiency syndrome (AIDS) or with AIDS related complex (ARC). A histological, immunohistological and ultrastructural study. *Pathol. Res. Pract.* 180 (1985), 590.
36. Warner, TF, B Crass, C Gabel, et al: Diagnosis of HTLV-III infection by ultrastructural examination of germinal centers in lymph nodes. A case report. *AIDS Res.* 2 (1986), 43.
37. Wood, GS, RR Turner, RA Shiurba, et al: Human dendritic cells and macrophages: *In situ* definition of subsets that exhibit specific and morphologic characteristics. *Am. J. Pathol.* 119 (1985), 73.
38. Cameron, PU, RL Dawkins, JA Armstrong, et al: Western blot profiles, lymph node ultrastructure and viral expression in HIV-infected patients: A correlative study. *Clin. Exp. Immunol.* 68 (1987), 465.
39. Tenner-Racz, K, P Racz, J-C Gluckman, et al: Cell-free HIV in lymph nodes of patients with persistent generalized lymphadenopathy and AIDS. *N. Engl. J. Med.* 318 (1988), 49.
40. Tenner-Racz, K, P Racz, P Kern, et al: Prognostic and diagnostic value of lymph node biopsy in AIDS and persistent generalized lymphadenopathy. In *Clinical Aspects of AIDS and AIDS-Related Complex*, Staquet, M, R Hemmer, H Baert (Eds.), Oxford University Press, Oxford, New York, Tokyo (1986), 125.
41. Baroni, CD, F Pezzella, M Mirolò, et al: Immunohistochemical demonstration of p24 HTLV-III major core protein in different cell types with lymph nodes from patients with lymphadenopathy syndrome (LAS). *Histopathology* 10 (1986), 5.
42. Tenner-Racz, K, P Racz, M Dietrich, et al: Monoclonal antibodies to human immunodeficiency virus: Their relation to the patterns of lymph nodes changes in persistent generalized lymphadenopathy and AIDS. *AIDS* 1 (1987), 95.
43. Racz, P, AC Feller, K Tenner-Racz, et al: Human lymphocyte subpopulations in lymphadenopathies in homosexual men. *Adv. Exp. Biol. Med.* 186 (1985), 1069.
44. Harper, ME, LM Marselle, RC Gallo, et al: Detection of lymphocytes expressing human T-lymphotropic virus type III in lymph nodes and peripheral blood from infected individuals by *in situ* hybridization. *Proc. Natl. Acad. Sci. USA* 83 (1986), 772.

45. Harper, ME, LM Marselle, KJ Chayt, et al: Detection of rare cells expressing HTLV-III in primary lymphoid tissue from infected individuals using a highly sensitive *in situ* hybridization method. In *Biochemical and Molecular Epidemiology of Cancer*, Harris, CC (Ed.), Alan R. Liss, New York (1986), 449.
46. Biberfeld, P, KJ Chayt, LM Marselle, et al: HTLV-III expression in infected lymph nodes and relevance to pathogenesis of lymphadenopathy. *Am. J. Pathol.* 125 (1986), 436.

**Klara Tenner-Racz, M.D.**  
**Department of Haematology**  
**Allgemeines Krankenhaus St. Georg**  
**Hamburg, WEST GERMANY**