

LYMPHOID TISSUE CHANGES IN HIV-INFECTED PATIENTS

J. Diebold, J. Audouin, A. Le Tourneau

Service Central "J. Delarue" d'Anatomie et de Cytologie Pathologique, Faculty de Medecine Broussais, Paris, France

The human T lymphotropic virus type III (HTLV III) or lymphadenopathy-associated virus (LAV), now human immunodeficiency virus (HIV), is known to infect CD4 positive T lymphocytes and cells belonging to the mononuclear phagocyte system (macrophages and follicular dendritic cells). Infection of these cells is responsible for variable morphologic changes in the lymphoid tissue. Histological, immunohistological, and ultrastructural study of lymph nodes and spleens from HIV-infected patients provides valuable information for diagnosis, prognosis, and comprehension of the disease.

The persistent generalized lymphadenopathy syndrome

Persistent generalized lymphadenopathy, one of the expressions of HIV infection, represents group III of the last classification proposed by the Centers for Disease Control of the US Department of Health and Human Services. This syndrome can be associated with different other symptoms belonging to group IV of this classification, particularly subgroup A which corresponds to the earlier AIDS-related complex or ARC.

The lymphadenopathies are due to a B lymphoid cell hyperplasia associated with histiocytic hyperplasia. These lymph node changes are seen at the beginning of the disease. In the classification we proposed (*Table 1*) these changes are

called type IA. The B cell hyperplasia comprises the following changes:

1. Follicular hyperplasia with huge germinal centers (*Fig. 1*).
2. Polyclonal plasma cell hyperplasia in the medullary cords, in the interfollicular areas and in the follicles.
3. B-immunoblastic hyperplasia in the deep cortical and interfollicular areas.
4. Sinusal B lymphocytosis in the cortex.

The histiocytic hyperplasia consists of:

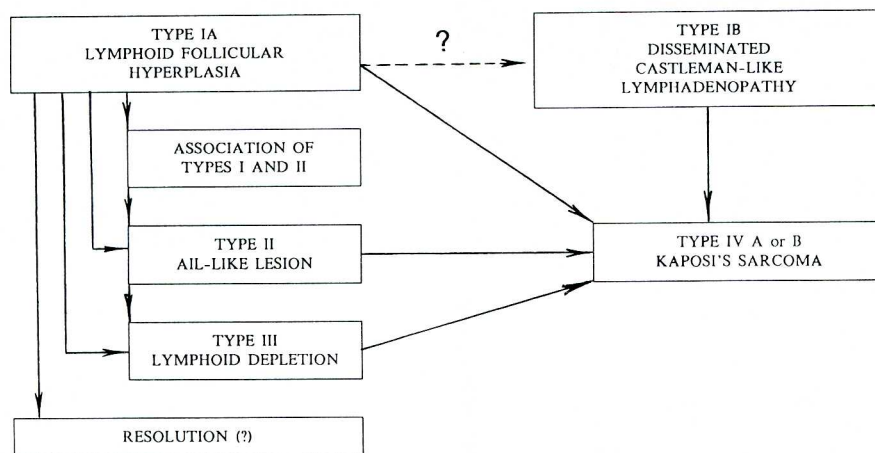
1. Sinusal histiocytosis with erythrophagocytosis (*Fig. 1*).
2. Histiocytic granuloma along the cortical sinuses.
3. Epithelioid cell clusters between the follicles and at the periphery of germinal centers.

But the most important modifications in the lymph node with follicular hyperplasia consist of progressive follicular disruption or lysis and a progressive T lymphoid cell depletion with unbalanced CD4/CD8 ratio.

Immunolabeling studies demonstrate the presence of a high quantity of T cells but with a decrease of CD4 positive cells and an increase of CD8 positive cells. The increase in CD8 cells in the germinal centers is highly suggestive of HIV infection, particularly when associated with intrafollicular depletion of CD4 cells (*Figs. 2 and 3*).

Follicular lysis is recognized at the optical level (*Fig. 4*). Sheets of lympho-

Table 1
Diagram of the Possible Evolution of Lymph Node Lesions in LAS and AIDS



cytes infiltrate the germinal centers. Most of them are CD8 positive T lymphocytes. In the infiltrated areas, there is a dislocation of the follicular architecture. In other cases, such disruption is due to edema and/or hemorrhage. Immunohistochemical staining with a monoclonal antibody specific for follicular dendritic cells (FDC) demonstrates presence of large irregular zones without labeled FDC. In these areas, the FDC network is destroyed (Fig. 5). In association, the perifollicular mantle zone becomes atrophic and progressively disappears, leading to naked germinal centers (Figs. 1,6,7).

In addition to all these changes, the post-capillary venules are hypertrophied and seem to be more numerous than in normal lymph nodes.

These changes together are highly suggestive of HIV infection despite the lack of specificity of each histological modification. In a personal series of 65 patients, we proposed the diagnosis of HIV related lymphadenopathy in 96% of the cases simply on histological criteria. The diagnosis was confirmed by seropositivity and/or the discovery of HIV-like particles in the germinal centers of the hyperplastic follicles.

Demonstration of retrovirus parti-

cles, first published by Armstrong and Horn, then confirmed by Racz et al and by our group, is the most interesting finding on electron microscopy (Fig. 8). These particles exhibit the morphology of HIV particles as described *in vitro*. They are round, measuring from 100 to 120nm in diameter. They are delineated by a fine, sharp, peripheral membrane and contain a central core measuring 40 to 50nm in diameter. The form and size of the core is a function of the plane of section. The most common shape is conical with an eccentric dark base and a lighter vanishing apex, sometimes truncated. In every patient (65) these viral particles were found only in the germinal centers. They lie in the extracellular spaces delimited by the cytoplasmic expansions of the FDC (Fig. 9). Armstrong and Horn demonstrated some budding from the cytoplasm of FDC and proposed that the HIV particles are produced by infected FDC. These FDC show membrane and cytoplasmic alterations perhaps preceding their death.

In summary, in type IA lymphadenopathy, the most important modification is B lymphoid cell hyperplasia, which leads to reactivation of silent viral infections such as EBV or cytomegalovirus. The higher number of mitoses favors the

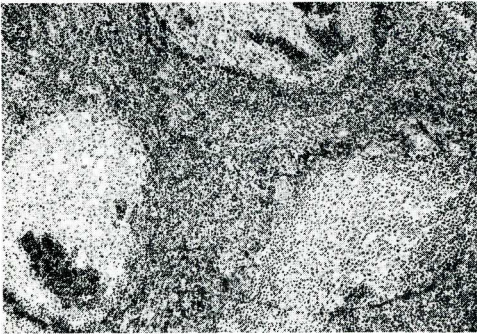


Fig. 1. Lymph node, type IA (hematoxylin-eosin, G=120x). Follicular hyperplasia with lymphocytic infiltrates in the germinal centers and atrophic mantle zone.

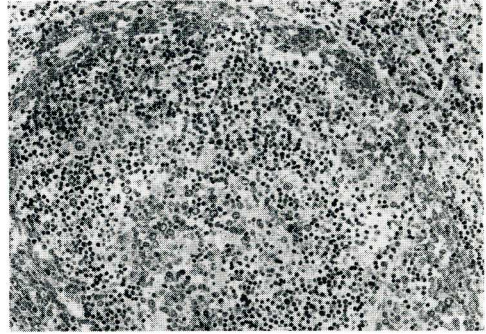


Fig. 4. Lymph node, type IA (Giemsa, G=225x). Severe follicular lysis. The normal architecture is disrupted by edema and lymphocytic infiltrate.

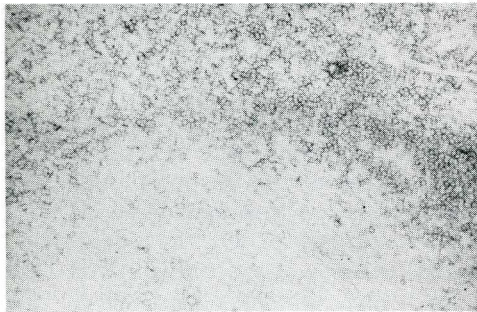


Fig. 2. Lymph node type IA (immunoperoxidase staining, ABC procedure, Leu 3A monoclonal antibody, G=150x). The CD4 positive T cells are present in the interfollicular and deep cortical area (top). In the germinal center their number are considerably reduced in comparison to control cases.

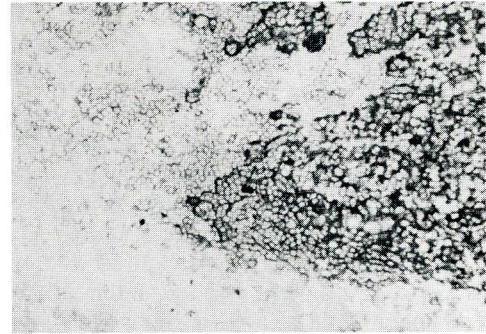


Fig. 5. Lymph node type IA (immunoperoxidase staining, ABC procedure, anti-follicular dendritic cell monoclonal antibody, G=200x). Defect in staining of the FDC realizing irregular zone in the germinal center.

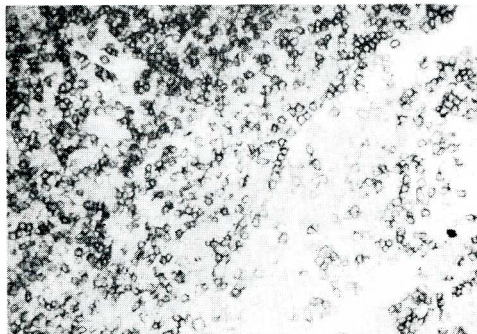


Fig. 3. Lymph node type IA (same procedure, IOT8 monoclonal antibody, G=300x). Same case, magnification of the left upper part of the same field as Fig. 5. Large number of CD8 positive lymphocytes around and in the germinal center.

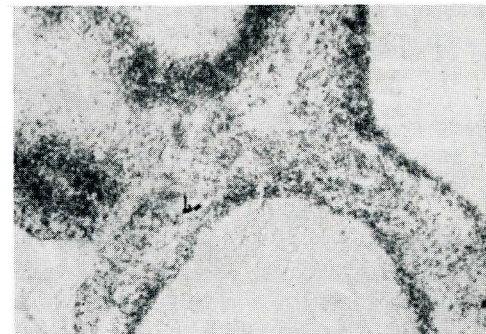


Fig. 6. Lymph node type IA (immunoperoxidase staining, ABC procedure, anti-6 heavy chain monoclonal antibody, G=120x). The mantle zone, constituted by lymphocytes expressing surface IgD, shows a variable atrophy from one lymph node to the other.

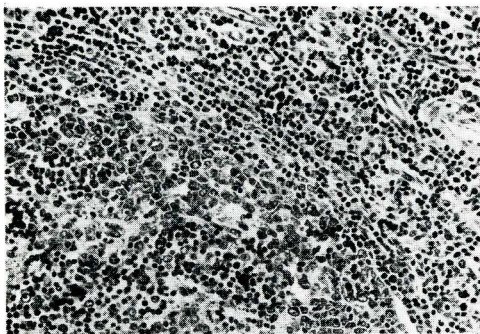


Fig. 7. Lymph node type IA (Giemsa staining, $G=260\times$). Naked germinal center due to severe mantle zone atrophy. Lymphocytic infiltrate with disruption of the germinal center (bottom left).

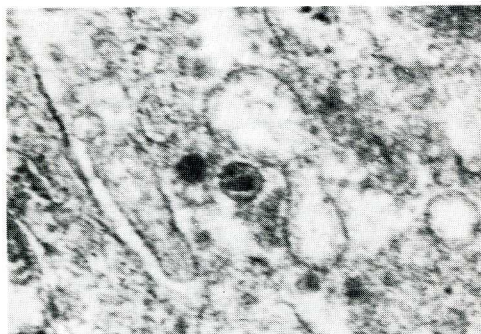


Fig. 8. Lymph node type IA ($G=70,000\times$). A typical HIV particle is recognized in the extracellular spaces. Notice the pyramidal shape of the central core.

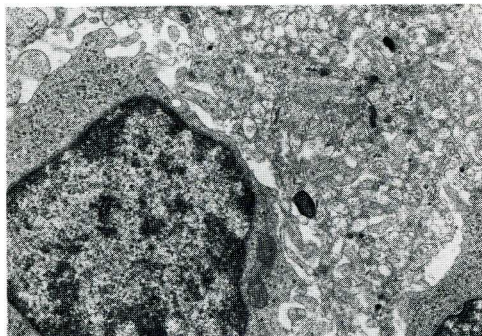


Fig. 9. Lymph node type IA ($G=5,500\times$). Follicular dendritic reticulum cell with a labyrinthine pattern of cytoplasmic processes. One junction system between two processes can be recognized. A small number of viral particles lie between the processes.

development of abnormal clones with chromosomal alterations. Successive mutations can lead to B-ML, often of the Burkitt-type. The second important change is the progressive follicular lysis which leads to a B-lymphoid deficiency complicating the progressive loss of CD4 positive T lymphocytes, which is responsible for the development of opportunistic infections.

In PGL, two other types of morphological changes can be seen in the lymph node. The first is characterized by a diffuse pattern with vascular hyperplasia and a large number of immunoblasts. This histological change looks like angio-immunoblastic lymphadenopathy. We term this pattern type II in our classification. No germinal centers can be recognized or else only small remnants constituted by clusters of FDC as demonstrated with specific monoclonal antibody on frozen section. In type II lymphadenopathy, immunolabeling studies demonstrate the presence of polyclonal B cells (immunoblasts and plasma cells) and a marked decrease in T lymphocytes predominantly of the CD4 class. Association of type IA and type II changes can be observed in the same lymph node thereby demonstrating a continuous evolution from type IA to type II.

The last pattern exhibited in PGL resembles the so-called "multicentric Castleman disease." The germinal centers display an "onion bulb" appearance due to centrollicular B lymphoid cell depletion. The T-dependent deep cortical areas are atrophic. A massive polyclonal plasmacytosis is seen in the medullary cords, around the vessels in the cortex and in the follicles. In addition, vascular hyperplasia and distension of the sinus are recognized.

Patients with type IA may have an evolution of many years. Most cases with type II transform into true AIDS with opportunistic infections and atrophy of the lymph node due to severe lymphoid depletion predominantly of CD4 positive T-cells (our type III). In all published cases with type IB changes, a B-ML or a Kaposi's sarcoma was dis-

closed a few days or weeks after the lymph node biopsy. A scheme of the possible evolution is summarized in *Table 1*.

The spleen in thrombocytopenic purpura

Some HIV-infected patients have a unique manifestation thrombocytopenia unresponsive to drug treatment. Splenectomy is sometimes undertaken. Follicular hyperplasia is characteristic without lymphoid infiltration of the germinal centers and without disruption of the FDC network. Only two differences are detectable between the spleen of HIV-positive patients and that of idiopathic thrombocytopenia. First, there is an increased number of CD8 positive T lymphoid cells in the germinal centers. Second, electron microscopy demonstrates HIV-like particles in the germinal centers in extracellular spaces between the cytoplasmic expansions of the FDC. In more advanced cases, lymphoid infiltrates are seen in the germinal centers with or without edema but with FDC network disruption. Some Malpighian corpuscles demonstrate a Castleman-like pattern. Polyclonal plasmacytosis is always present in the red pulp cords. In short, the same pattern of lymphoid tissue modifications are depicted in the spleen as in the lymph node of HIV-infected patients.

CONCLUSION

Lymph node biopsies and studies of resected spleens in HIV-infected patients exhibit characteristic histological and immunological patterns, which suggests HIV infection at the outset of the disease. These changes can even be found in seronegative patients. Electron microscopy of germinal centers in lymph node and spleen may demonstrate the presence of HIV particles, which points to the diagnosis of HIV infection in both seropositive and seronegative patients.

Type IA with severe destruction of the germinal centers, and especially type IB and II are each associated with a poor prognosis.

Lymph node biopsy is also important for disclosing ML or early Kaposi's sarcoma.

Finally, immunohistochemistry, ultrastructural study, and molecular biologic techniques will continue to shed further light on this disease.

ACKNOWLEDGEMENTS

We thank Mr. Maurice Wolfesberger for providing the photographs.

REFERENCES

1. Armstrong, JA, R Horne: Follicular dendritic cells and virus like particles in AIDS-related lymphadenopathy. *Lancet* II (1984), 370-372.
2. Baroni, CD, F Pezzella, A Stopacciaro, M Mirolo, E Pescarmona, D Vitolo, AM Casano, P Barsotti, L Nicoletti, LP Ruco, S Uccini: Systemic lymphadenopathy syndrome (LAS) in intravenous drug abusers. *Histology, immunochemistry and electron microscopy. Pathogenic correlations. Histopathol.* 9 (1985), 1275-1293.
3. Biberfeld, P, A Ost, A Porwit, B Sandstedt, G Pallesen, B Bottiger, L Morfelt-Mansson, G Biberfeld: Histopathology and immunohistology of HTLV III-LAV related lymphadenopathy and AIDS. *Acta Path. Microbiol. Immunol. Scand. Sect. A.* 95 (1987), 47-65.
4. Centers for Disease Control: Persistent generalized lymphadenopathy among homosexual males. *Morbidity and Mortality Weekly Report.* 31 (1982a), 249-251.
5. Centers for Disease Control: Classification system for human T-lymphotropic virus type III/lymphadenopathy-associated virus infection. *Ann. Intern. Med.* 105 (1986), 234-237.
6. Diebold, J, C Marche, J Audouin, C Bouton, JP Aubert: Les differents aspects histopathologiques des ganglions lymphatiques dans le SIDA (etats prodromiques etats voisins et syndromes confirmes). In *SIDA*, Zittoun, R. (Ed.), DOIN et CIE, Paris, (1985).
7. Diebold, J, C Marche, JP Aubert, J Audouin, A LeTourneau, C Bouton, M Reynes, J Wiszniak, F Capron, V Tricottet: Lymph node modifications in patients with the acquired immunodeficiency syndrome (AIDS) or with AIDS related complex (ARC). A histological, immunopathological and ultrastructural study of 45 cases. *Pathol. Res. Pract.* 180 (1986), 590-611.
8. Diebold, J, J Audouin, A LeTourneau, JP Aubert: Lymph node biopsy in the diagnosis of persistent lymphadenopathy syndrome in patients at risk for acquired immunodeficiency syndrome. *Progress in Surgical Pathology.* VII, (1988).

9. Finkbeiner, WE, BM Egbert, JR Groundwater, RW Sagebiel: Kaposi's sarcoma in young homosexual men. A histopathologic study with particular reference to lymph node involvement. *Arch. Pathol. Lab. Med.* 106 (1982), 261-264.
10. Ioachim, HL, CW Lerner, ML Tapper: Lymphadenopathies in homosexual men. Relationship with the acquired immune deficiency syndrome. *JAMA* 250 (1983), 1306-1309.
11. Janossy, G, AJ Pinching, M Bofill, J Weber, JE McLaughlin, M Ornstein, K Ivory, JRW Harris, M Favrot, DC MacDonald-Burns: An immunohistological approach to persistent lymphadenopathy and its relevance to acquired immune deficiency syndrome. *J. Clin. Exp. Immunol.* (1985), 257-266.
12. LeTourneau, A, J Audouin, J Diebold, C Marche, V Tricottet, M Reynes: LAV-like viral particles in lymph node germinal centers in patients with the persistent lymphadenopathy syndrome and the acquired immunodeficiency syndrome-related complex. An ultrastructural study of 30 cases. *Hum. Pathol.* 17 (1986), 1047-1053.
13. Marche, C, Y Neguesse, C Bouton, S Kernbaum, B Regnier, AG Saimot, J Diebold: Histopathological studies of lymphadenopathy in AIDS: Tentative classification. Preliminary report. Communication at a symposium on "Epidemic of AIDS and Kaposi's sarcoma", Napoli, June, 1 vol., Karger AG, Basel (1983).
14. Marche, C, S Kernbaum, AG Saimot, Y Neguesse, C Bouton, J Diebold, B Regnier, D Vittecoq: Histopathological study of lymph nodes in lymphadenopathy and acquired immune deficiency syndromes. *Eur. J. Clin. Microbiol.* 31 (1984), 75-76.
15. Meyer, PR, LD Ormerod, KG Osborn, LJ Lowenstiner, RV Hendrickson, RL Modlin, RE Smith, MD Gardner, CR Taylor: An immunopathologic evaluation of lymph nodes from monkey and man with acquired immune deficiency syndrome and related conditions. *Hematol. Oncol.* 3 (1985), 199-210.
16. Pileri, S, MT Rivano, E Raise, G Gualandi, M Gobbi, M Martuzzi, FM Gritti, J Gerdes, H Stein: The value of lymph node biopsy in patients with the acquired immunodeficiency syndrome (AIDS) and the AIDS-related complex (ARC): A morphological and immunohistochemical study of 90 cases. *Histopathol.* 10 (1986), 1107-1129.
17. Racz, P, K Tenner-Racz, C Kahl, AC Feller, P Kern, M Dietrich: Spectrum of morphologic changes of lymph nodes from patients with AIDS or AIDS-related complexes. *Progress in Allergy* 37 (1986), 81-181.
18. Raphael, M, P Pouletty, M Cavaille-Coll, W Rozenbaum, A Homond, L Nonnemacher, A Delcourt, JC Gluckman, P Debre: Lymphadenopathy in patients at risk for acquired immunodeficiency syndrome. *Histopathology and histochemistry. Arch. Pathol. Lab. Med.* 109 (1985), 128-132.
19. Toccanier, MF, Y Kapaci: Lymphadenopathy in drug addicts. A study of the distribution of T-lymphocyte subsets in the lymph node. *Virchows Arch. A. Path. Anat. Histopathol.* 406 (1985), 149-164.
20. Ziegler, JL, G Wagner, JS Greenspan: Diffuse undifferentiated non-Hodgkin's lymphoma among homosexual males-United States. *Morbid Mortal. Weekly Rep.* 31 (1982b), 277-279.

Professor J. Diebold
Laboratoire d'Anatomie et de
Cytologie Pathologiques
Faculte de Medecine Broussais
Hotel Dieu
15, rue de l'Ecole de Medecine
75270 Paris Cedex 06
FRANCE