

AIDS-KAPOSI'S SARCOMA COMPLEX: EVOLUTION OF A FULL-BLOWN LYMPHOLOGIC SYNDROME

M.H. Witte, C.L. Witte

Department of Surgery, University of Arizona College of Medicine, Tucson,
Arizona, USA

ABSTRACT

An hypothesis is presented to explain the link between acquired immunodeficiency syndrome (AIDS) and Kaposi's sarcoma (KS). According to this hypothesis, AIDS involves all four components of the integrated lymphatic system--lymphatics, lymph nodes, lymphocytes, and lymph--and thereby resembles various congenital and acquired lymphologic syndromes characterized by one or more of the following features: lymphostasis, angiogenesis, and fibrosis; depletion of immunocompetent cells and immunosuppression; opportunistic infections; and vascular neoplasms. A better understanding of the steps in the evolution of these processes and their interrelationships to the four components of the lymphatic system should provide insight into the immunopathogenesis of AIDS-KS as well as its detection and treatment.

The current pandemic of AIDS now affecting more than 55,000 persons worldwide was ushered in six years ago by the dramatic appearance of an aggressive disseminated form of a rare vascular malignancy--Kaposi's sarcoma (KS)--in homosexual men (1). Whereas an explosion of information has since accumulated about the epidemiology and immunopathology of AIDS and the putative AIDS virus (HIV) has been identified and

characterized, the link between AIDS and KS remains puzzling. Because HIV has not been convincingly found in KS lesions and animal models of AIDS do not display KS, some consider KS an epiphenomenon traceable to associated AIDS risk factors (2) or merely one of several opportunistic neoplasms secondary to immunosuppression. Others, in contrast, regard the two entities as closely intertwined in pathogenesis and view KS in both its external and internal manifestations as an uncontrolled angiogenic response accompanying immune hyperstimulation followed only later by immune exhaustion (3). At the present time, each of these contrasting perspectives remains tenable, in part reflecting a fundamental ignorance about host defense against the responsible retrovirus and other foreign pathogens, particularly those aspects relating to the afferent (lymphatic) limb of the immune response.

HYPOTHESIS

Given these divergent views, we now propose that the AIDS-KS complex represents one of a constellation of congenital and acquired "lymphologic syndromes" arising from the four basic elements of the lymphatic system--lymphatic vessels, tissue fluid or lymph, lymphocytes, and lymphoid aggregates, which also happens to form the battleground of the host response (*Fig. 1*). Indeed,

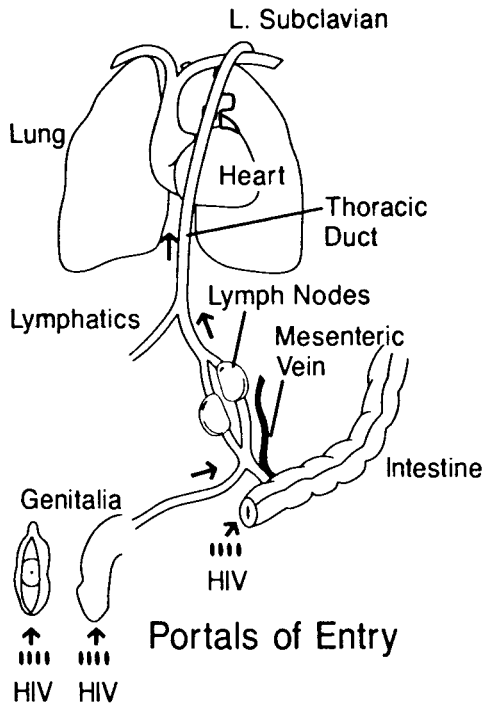


Fig. 1. Primary lymphogenous route of HIV infection and dissemination in cases not involving blood transfusions or intravenous drug abuse. HIV enters through the mucosal barriers of the genitalia and gastrointestinal tract either as free particles or carried by foreign cells. These then either remain at the sites of entry or migrate into draining lymphatics and are transported to pelvic or mesenteric lymph nodes and enter germinal centers. These particulates also exit via efferent lymphatics (or alternatively via venous sinuses) and continue along lymph nodal chains into central lymph trunks and from there gain access to the bloodstream where they are widely disseminated. This lymphologic scheme bears not only on a likely mode of entry and dissemination of HIV but also on the pathogenesis of opportunistic infections and neoplasms associated with AIDS (see text).

from what is already known, HIV is distinctly *lymphotropic*. Not only does this retrovirus seek out, infect, and destroy T-helper *lymphocytes*, the predominant circulating cell in *lymph*, but it also invades and passes from host to host through a variety of tissue fluids (i.e., *lymph*), producing a local response that interferes with the free movement of tissue fluid, macromolecules, and migrating cells (i.e., *lymphostasis*), occasionally accompanied by overt *lymphedema*. The

virus initially excites then finally exhausts *lymph nodes* and other *lymphoid aggregates* in a process marked by intense neovascularization and vascular transformation, scarring, and obliteration, and in late stages by aggressive *lymphocyte-derived malignancies* (lymphomas) and *lymphatic-derived* (KS) neoplasms.

Hypothesis-Analysis

Modern concepts of the lymphatic system view the integrated function of lymphatic vessels, lymph, lymphocytes, and lymphoid aggregates as a complex circulation and communication network of tissue fluid, macromolecules, particles, and cells, which functions continuously as a "blood-lymph loop" to renew the extracellular microenvironment and transmit messages maintaining (or appropriately alerting) the milieu interieur (4,5). When the lymphatic circulation is impaired and lymphostasis intercedes, high protein edema fluid accumulates, stimulating intense fibrosis, lipid deposition, vigorous proliferation of lymphatics and blood vessels, and benign lymphangiomatoid nodular changes, all proximal to the site of obstruction (4,6). In this setting, recurrent lymphangitis and cellulitis (i.e., opportunistic infections) of the lymphedematous part are common, closely linked to defective local immune surveillance and accompanied by impaired lymphatic clearance and processing of pathogenic microorganisms, other foreign particulates, and macromolecules. Indeed, tissues poor or absent in lymphatic drainage are a privileged site for skin homografts, and depression of T-helper cells in conjunction with lymph node and thymic atrophy characterized by diffuse fibrosis, vascular transformation and lymphocyte depletion, are striking features of various lymphedema and chylous syndromes. Occasionally, a highly aggressive malignant angiosarcoma closely resembling KS arises in the chronically lymphedematous part, whether acquired after radical mastectomy for breast cancer (so-called Stewart-Treves syndrome) (7) or of congenital origin.

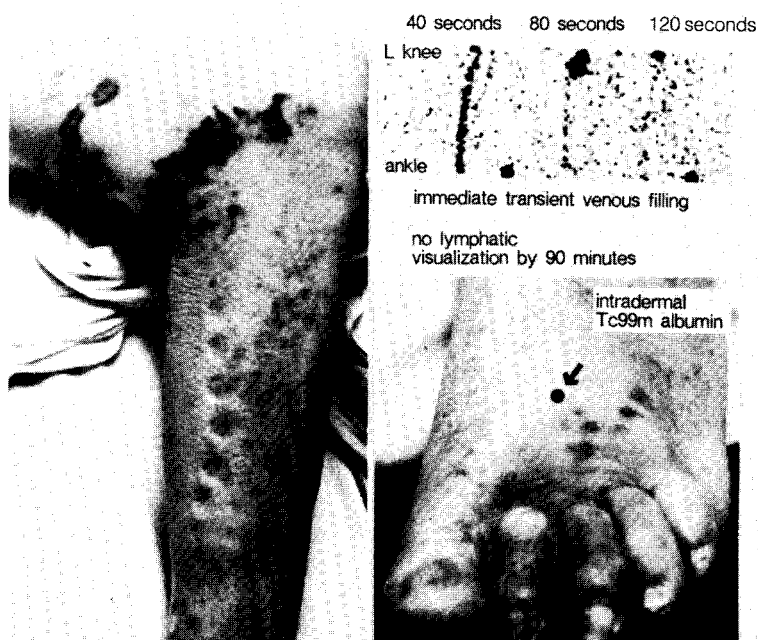

Fig. 2. Right leg, left foot, and lymphoscintigram (upper right) in classical Kaposi's sarcoma. In this 74-year-old man with longstanding Kaposi's sarcoma of the lower extremities treated with irradiation and displaying extensive brawny edema (note linear pitting) and ulceration, intradermal deposition of 500 μ c of 99m Tc albumin in the dorsum of the left foot resulted in prompt visualization of the draining venous system several seconds after injection and fading by one minute. This finding is consistent with a lymphatic venous shunt or direct communication of the interstitium with an abnormally permeable venous system.

Thus, the constellation of clinical and pathologic findings in AIDS (i.e., the HIV-induced disease)--immunosuppression associated with T-helper lymphocyte and lymphoid tissue depletion, fibrosis, opportunistic infection, and aggressive vascular malignancies--reproduces systemically and in macrocosm the sequelae of lymphostasis in the affected lymphedematous part. In peripheral lymphedema, the findings are limited to the involved extremity ("local AIDS") but a more generalized immunodeficiency state (a form of "systemic AIDS") develops without HIV in congenital and acquired visceral lymphangiectasia syndromes associated with chylous reflux, protein-losing enteropathy, or other external and internal bulk losses of lymph and its constituent lymphocytes, where especially the afferent limb of the immune response becomes impaired (8).

It is noteworthy that the slowly growing indolent form of "classical" African Kaposi's disease is almost universally associated with antecedent or concurrent lymphedema (9) and the cutaneous lesions characteristically follow the course of draining lymphatics (10). Abnormal communications between the blood and lymphatic vasculature have also been demonstrated radiographically (11). On 99m Tc albumin lymphoscintigraphy, we have observed prompt transient venous filling in a patient with classical Kaposi's sarcoma associated with bilateral lymphedema (Fig. 2). Although only mentioned in passing in clinical descriptions and color atlases (12) and then attributed to local tumor infiltration or regional lymphadenopathy, lymphedema of the face and neck, genitalia, or of an involved extremity is also not infrequently a manifestation in AIDS-KS, and even

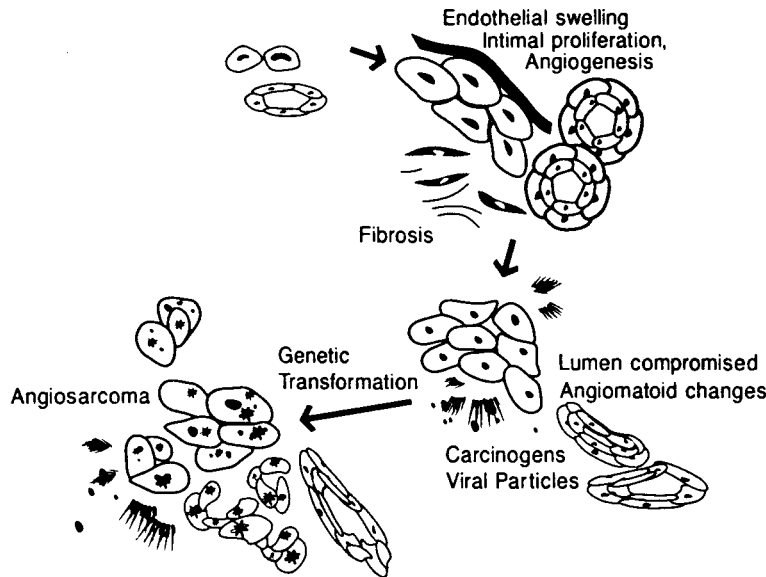


Fig. 3. In the evolution of Kaposi's sarcoma or angiosarcoma associated with lymphatic obstruction, dilatation of vascular channels occurs early with "piling up" of endothelial cells and vigorous angiogenesis. Impeded tissue drainage of carcinogens and microbial pathogens, paucity of interstitial immunocompetent cells, and potential direct entry of macromolecules and particles into the venous system bypassing regional lymph nodes, lead to progressive impairment of the local immune response to foreign antigens, persistent endothelial stimulation and proliferation, and oncogene activation. The outcome is vascular hyperplasia and ultimately benign and malignant neoplasia.

chyloous pleural effusions and protein-losing enteropathy (13) have been described. Moreover, in simian AIDS, an animal counterpart of the human disorder, peripheral lymphedema is occasionally observed. Finally, mounting morphologic and immunohistochemical evidence supports the view that KS is derived from endothelial-lined channels more closely resembling lymphatic than blood vascular endothelium (10,14-15). On the other hand, prominent neovascularization is a widespread and well-recognized phenomenon in AIDS even in the absence of KS lesions, manifested in many different organs and tissues (e.g., angioimmunoblastic lymphadenopathy, peliosis hepatis, and subcutaneous angiolipomas and angiofibromas).

These observations support the notion that widespread stimulation of both blood vessel and lymphatic proliferation (hemangiogenesis and lymphangiogenesis) is a key feature of the AIDS-KS

complex. It remains unclear whether multifocal endothelial hyperplasia and neoplasia result from viral DNA transformation or from environmental carcinogens and cofactors (Fig. 3), or represent a more general reaction to immunologically stimulated lymphokine release or even to lymphostasis. Likewise, how these changes relate to lymphocyte maldistribution and lymphoid atrophy and fibrosis is unknown. Nonetheless, immune surveillance and intact humoral and cellular immunity involve close interactions between the migrant streams of lymphocytes and other mononuclear cell populations and the vascular endothelium. Lymphocyte "homing" to the spleen, thymus gland, Peyer's patches, and regional lymph nodes depends on shared cell-surface receptors, and vascular endothelium engages in multifaceted complex interrelationships with immunocompetent cell populations (16), directing cell traffic while generating colony-stimulating

activity as well as interacting with surrounding extracellular matrix and neighboring macrophages, smooth muscle cells, fibroblasts, and adipocytes. Endothelial receptors are "turned on" both by viremia and by circulating T-helper lymphocytes. It is thus more than coincidental that HIV not only attacks T-helper cells but also has been localized in vascular endothelium (17), dendritic cells, and macrophages, cell types which have been proposed as HIV reservoirs or targets. In other words, the systemic immune defects in AIDS are far more widespread and complex than mere destruction of activated T-helper cells by the causative virus as demonstrated *in vitro*. It seems reasonable, therefore, to hypothesize that important clues to the pathophysiology of AIDS-KS lie hidden in HIV interactions with blood and lymphatic vessels themselves as well as with lymphoid cells, macromolecules, and tissue fluid circulating or residing in the lymphatic system and the contiguous interstitial space.

These concepts are exemplified by our original report (18) reexamined (19) in 1984 as "AIDS in 1968," describing the clinical course of a sexually active black male adolescent who initially presented with genital and later bilateral lower extremity lymphedema. His disease rapidly progressed to anasarca with ascites and pleural effusions, progressive inanition, and death over a two-year interval. The evolution of lymphatic obstruction at both groins extending to involve the whole body; gradual transformation of lymph nodal pathology from reticuloendothelial hyperplasia [resembling AIDS-related complex (ARC)] to fibrosis and atrophy including a thymus devoid of germinal centers and Hassall's corpuscles and marked by vascular transformation; profound peripheral lymphocytopenia; angiomatoid collections of dermal lymphatics; unremitting opportunistic (chlamydial) infection including terminal necrotizing pneumonitis; profound cachexia and eventual demise with disseminated KS involving the skin, subcutaneous tissue, anorectum, lymph nodes, and thymus gland, represents a lymphologic

syndrome involving all four elements of the lymphatic system and fulfilling the original Center for Disease Control (CDC) criteria for AIDS long before a name could be attached to it.

In collaboration with Drs. R. Garry and A. and M. Gottlieb of Tulane University and Imreg Corporation and our original colleagues in St. Louis, we recently spot-tested deep-frozen body fluids and tissues preserved for almost 20 years for evidence of HIV (antibody response and/or antigen) to see whether this patient was a victim of HIV-infection before its time, infection with another foreign pathogen, or alternatively, a widespread angiosarcoma (Stewart-Treves syndrome) from systemic lymphostasis. Not only were HIV antigens detected and subsequently quantified by antigen capture assay in frozen tissues, particularly spleen and brain, but Western blot immunoassay was positive for serum antibodies against 9 of 9 HIV-1 but not HIV-2 antigens.

Unknowns and predictions

Research directions and predictions arising from this lymphologic hypothesis include: 1) HIV not only infects blood vascular endothelium and closely related lymphatic endothelium but is cytopathic for these cells both *in vivo* and *in vitro* and attacks common cell surface receptors; 2) alternatively, or under different conditions, HIV directly or indirectly through lymphokine release stimulates endothelial proliferation; 3) lymphatic channels are an important portal of entry and route of spread for HIV (and associated opportunistic pathogens (e.g., *Mycobacterium avium intracellulare* and intestinal parasites), and the regional lymphatic drainage bears the brunt of the disrupted afferent limb of the host immune response, first through immune stimulation then ultimately suppression; 4) particularly in non-blood transmitted AIDS, lymphatic involvement should be prominent in the genitalia and at both ends of the gastrointestinal tract and amenable to non-invasive lymphatic visu-

alization (e.g., radionuclide lymphscintigraphy), which could form the basis for useful clinical "staging"; 5) KS should be transferable to tissue culture with isolation of constituent endothelial cell populations bearing structural and functional features of vascular endothelium particularly that derived from lymphatics; 6) in a variety of lymphologic syndromes, the evolution of lymph nodal pathology including immunoarchitecture should parallel the sequence of findings in ARC/AIDS; 7) in AIDS patients, central lymph from the thoracic duct should be strongly positive for HIV and a potentially large source of both multiplying and reservoir virus as well as infected and immunoreactive recirculating lymphocytes and related cell populations; 8) immunomodulating drugs under development to treat AIDS should be potentially useful in restoring immune function in other lymphologic syndromes; 9) angioinhibitory (and specifically lymphangiostatic) substances should be beneficial in disseminated KS, and *in vitro* cultures of lymphatic (20) and blood vascular endothelium in pure populations or in coculture with interacting cell types may be useful to study and screen these agents; 9) HIV-associated AIDS is only one of many acquired immunodeficiency syndromes exhibiting the final common pathway for a variety of pathophysiologic processes targeting the lymphatic apparatus.

ACKNOWLEDGEMENTS

Supported in part by Arizona Disease Control Research Commission Contracts #8277-00000-1-1-AT-6625, ZB-7492, and ZM-8036.

REFERENCES

1. Friedman-Kien, A, L Laubenstein, M Marmor, et al: Kaposi's sarcoma and Pneumocystis pneumonia among homosexual men—New York City and California. *Morbidity and Mortality Weekly Report* 30 (1981), 305-308.
2. Fauci, AS, H Masur, EP Gelman, et al: The acquired immunodeficiency syndrome: An update. *Ann. Int. Med.* 102 (1985), 800-813.
3. Levy, JA, JL Ziegler: Acquired immunodeficiency syndrome is an opportunistic infection and Kaposi's sarcoma results from secondary immune stimulation. *Lancet* 2 (1983), 78-81.
4. Olszewski, L: *Peripheral Lymph: Formation and Immune Function*. CRC Press, Inc., Boca Raton, Florida (1985).
5. Witte, M, C Witte: Lymphatics and blood vessels, lymphangiogenesis and hemangiogenesis: From cell biology to clinical medicine. *Lymphology* 20 (1987), 257-266.
6. Altorfer, J, L Clodius: Chronic experimental lymphedema of the extremities: Pathological changes. *Experientia* 32 (1976), 823-824.
7. Stewart, FW, N Treves: Lymphangiosarcoma in postmastectomy lymphedema. *Cancer* 1 (1948), 64-81.
8. Witte, M, C Witte: Lymphangiogenesis and lymphologic syndromes. *Lymphology* 19 (1986), 21-28.
9. Lothe, F: Kaposi's sarcoma in Uganda Africans. *Acta Pathologica et Microbiologica Scandinavica Supplementum* 161 (1963).
10. Dorfman, RF: Kaposi's sarcoma: The contribution of enzyme histochemistry to the identification of cell types. *Acta Intl. Union Cancer* 18 (1962), 464-476.
11. Palmer, PES: The radiological changes of Kaposi's sarcoma. *Acta Intl. Union Cancer* 18 (1962), 400-412.
12. Farthing, CF, SE Brown, RCD Staughton, et al (Eds.): *Colour Atlas of AIDS*. Wolfe Medical Publications, Ltd., London, (1986).
13. Loughran, DH, ES Johnson: Epidemic Kaposi's sarcoma. *Medical Aspects of Human Sexuality* May (1987), 128-141.
14. Beckstead, JH, G Wood, V Fletcher: Evidence for the origin of Kaposi's sarcoma from lymphatic endothelium. *Am. J. Pathol.* 119 (1985), 294-300.
15. Dictor, M: Kaposi's sarcoma: Origin and significance of lymphaticovenous connections. *Virchows Arch. (Pathol. Anat.)* 409 (1986), 23-35.

16. Baldwin, Wm III: The symbiosis of immunocompetent and endothelial cells. *Immunol. Today* 3 (1982), 267-269.
17. Wiley, C, R Schrier, J Nelson, et al: Cellular localization of human immunodeficiency virus infection within the brains of acquired immunodeficiency syndrome patients. *Proc. Soc. Natl. Acad. Sci.* 83 (1986), 7089-7093.
18. Elvin-Lewis, M, MH Witte, CL Witte, et al: Systemic chlamydial infection associated with generalized lymphedema and lymphangiosarcoma. *Lymphology* 6 (1973), 113-121.
19. Witte, MH, CL Witte, WL Drake Jr, et al: AIDS in 1968. *J. Am. Med. Assoc.* 251 (1984), 2657.
20. Way, D, M Hendrix, M Witte, et al: Lymphatic endothelial cell line (CH3) from a recurrent retroperitoneal lymphangioma. *In Vitro* 23 (1987), 647-652.

Marlys H. Witte, M.D.
Department of Surgery
University of Arizona
College of Medicine
1501 North Campbell Avenue
Tucson, AZ 85724 USA