

## WHOLE BODY LYMPHANGIOSCINTIGRAPHY IN FERRETS CHRONICALLY INFECTED WITH *BRUGIA MALAYI*

M. Witte, G. McNeill, C. Crandall, T. Case, C. Witte, R. Crandall, J. Hall, W. Williams

Departments of Surgery and Diagnostic Radiology (Nuclear Medicine), University of Arizona College of Medicine, Tucson, Arizona, USA, and Department of Pathology, Immunology, and Medical Microbiology, University of Florida, Gainesville, Florida, USA

### ABSTRACT

*Whole body lymphangioscintigraphy was performed after intradermal injection of  $^{99m}$ technetium human serum albumin or antimony colloid in the distal hindlimbs and forelimbs of ferrets chronically infected with *Brugia malayi*. The findings were compared with control ferrets and those with surgical interruption of the iliac lymphatics. While only one infected ferret manifested chronic hindlimb lymphedema, all exhibited delayed transport of radioisotope from the hindpaw with obstruction in the groin, poor or absent visualization of central lymphatic channels and regional lymph nodes, a picture similar to that following surgically induced lymphatic obstruction. In control ferrets, there was prompt visualization of peripheral lymphatic channels and regional lymph nodes with sharper and more extensive channel visualization after radiolabeled albumin and more intense sustained nodal visualization after radiolabeled antimony colloid. This noninvasive technique provides a readily repeatable investigative tool adaptable to small animals to study the evolution of lymphatic filariasis and other conditions associated with lymphatic obstruction.*

During the 1960's and 1970's, the newly developed technique of direct lymphangiography was applied to the study of human and experimental lymphatic filariasis (1). Intralymphatic administration of contrast media following intradermal vital dye injection revealed striking lymphatic dilatation and collateral formation (though poorly correlated with overt edema or a discrete site of obstruction), loss of lymphatic valve competence, retrograde flow occasionally with chylous reflux, lymphatic thrombi, and enlarged lymph nodes early with lymphoid dropout and fibrosis late. Largely due to concern for its cumbersomeness and invasiveness with associated damage to the lymphatic endothelial lining, direct lymphography has had limited usefulness other than to display vividly the extensive internal damage to the lymphatic system often unsuspected by mere external examination. For experimental purposes, moreover, the technique proved difficult in small animals and not easily repeated serially.

Because of technologic advances in radionuclide production and imaging devices during the past decade, noninvasive lymphoscintigraphy or isotope lymphangiography has gained increasing

favor in the clinical arena to visualize regional channels and nodes and to examine lymphatic uptake and transport of proteins and other macromolecules from the interstitium (2,3). A variety of radionuclides and colloidal materials have been tested for this purpose, and in 1983, intradermal instillation of radiolabeled albumin ( $^{99m}\text{Tc}$ -alb) was suggested as preferable for delineation of peripheral lymphatic trunks (4). Indeed, use of this agent in characterizing patients with edema of lymphovascular origin (i.e., primary and secondary lymphedema) provides a rapid, noninvasive image of peripheral lymph dynamics (5-8). When used in conjunction with a whole body scanning device, the lymphatic system can be visualized in continuity throughout its length rather than as sequential focal areas of interest (8). Therefore,  $^{99m}\text{Tc}$ -alb whole body lymphangioscintigraphy was adapted to ferrets in order to delineate lymphatic abnormalities in chronic *Brugia malayi* infection with and without peripheral lymphedema. The findings were compared with control ferrets and those with surgically-induced peripheral lymphatic obstruction.

## MATERIALS AND METHODS

The experimental group consisted of ten adult male ferrets weighing approximately 1.5kg. Four had been infected approximately 1 year earlier with 50-75 *Brugia malayi* third-stage larvae intrascrotally and two bilaterally in the inguinal region. None showed either lymphedema or other disability. One ferret had been repeatedly infected in the dorsum of the right foot while saline was injected as a control into the left foot; over a period of three years, chronic unremitting lymphedema of the right hindlimb developed. Two ferrets underwent abdominal exploration under pentobarbital anesthesia (25mg/kg IP) approximately 1 year earlier, at which time the parailiac lymphatics were liga-

ted and resected bilaterally and adjacent lymphatic branches and nodes excised; neither lymphedema nor disability was evident. Six untreated ferrets served as controls.

At the time of lymphangioscintigraphy under pentobarbital anesthesia, ferrets were positioned under a Toshiba GCA-90B digital gamma camera so that the whole body was included in the field. 0.05ml containing  $100\mu\text{Ci}$   $^{99m}\text{Tc}$  tightly bound (92 - 99%) to human serum albumin (and in 7 ferrets anti-mony colloid on a different occasion) was injected intradermally into the dorsum of each hindpaw. A brief period of hindlimb massage was carried out after the initial 30 minutes of images. Following this maneuver, additional intrascrotal intradermal injections of  $^{99m}\text{Tc}$ -alb were done in 10 ferrets, and additional bilateral intradermal forepaw injections of  $^{99m}\text{Tc}$ -alb were done in 13 ferrets. Serial images were obtained for up to 6 hours. In 9 of these ferrets after intradermal Evans blue injection in the dorsum of the hindpaw, surgical exposure of the dye-stained peripheral lymphatic system was carried out under pentobarbital anesthesia to confirm the lymphoscintigraphic findings prior to sacrifice.

## RESULTS

In control ferrets after  $^{99m}\text{Tc}$ -alb, peripheral lymphatic channels were promptly visualized throughout their length as were more central lymphatics (particularly after hindlimb massage) at least up to the cisterna chyli and occasionally into the thoracic duct. Regional lymph nodes (popliteal, femoral, and iliac as well as axillary and supraclavicular area) were also identified (*Fig. 1, left*). On the other hand,  $^{99m}\text{Tc}$  colloid failed to visualize distinctly the iliac lymphatics and particularly central channels more cephalad although lymph nodes were more intensely and discretely delineated and for a more prolonged period than after  $^{99m}\text{Tc}$ -alb (*Fig. 1, right*).

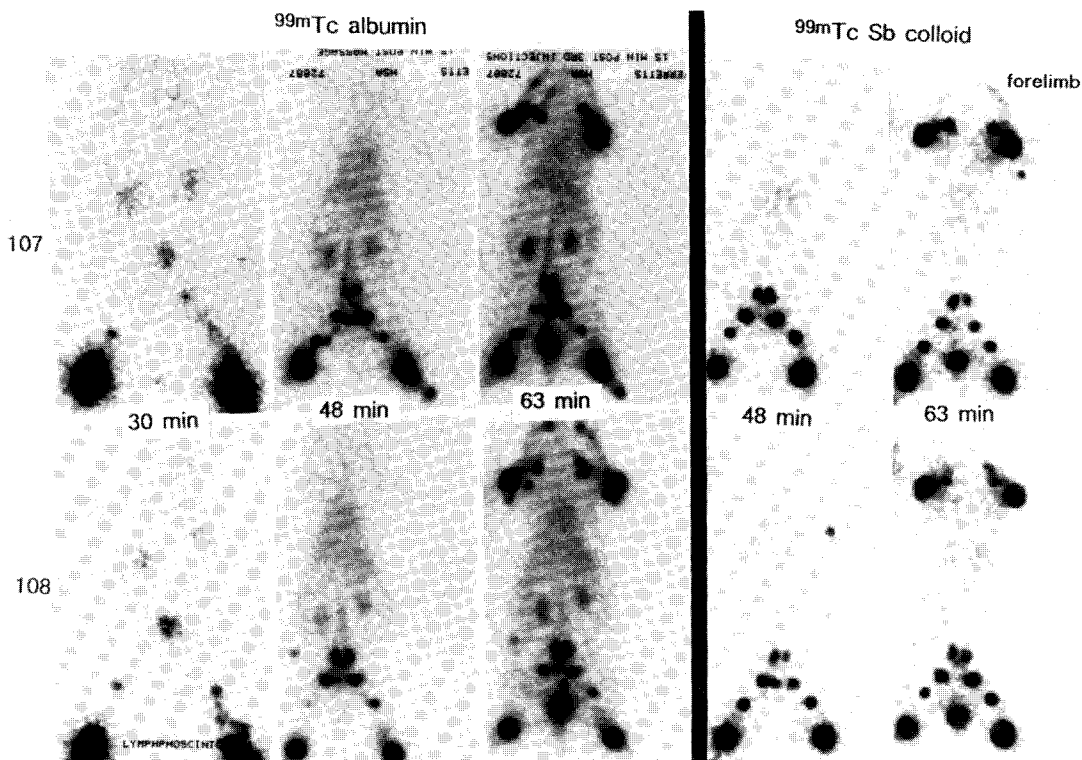


Fig. 1. Whole body lymphoscintigrams ( $^{99m}\text{Tc}$  albumin) (left) and antimony (Sb) colloid (right) after sequential bilateral hindpaw and forepaw as well as scrotal injection in 2 ferrets (#107, 108) (see text for details). Note rapid movement of the tracer into peripheral and central lymphatics (albumin only) with delayed persistent images of regional lymph nodes.  $^{99m}\text{Tc}$  albumin enhances truncal imaging while colloid enhances nodal imaging. Probably because of changes in technetium binding, renal excretion and visualization is only seen with  $^{99m}\text{Tc}$  albumin as the tracer.

In ferrets with *Brugia malayi* infection introduced via each of the three routes (scrotal, inguinal or hindpaw), uptake and transport of the radioisotope from the hindlimbs was severely restricted whether or not lymphedema was detectable (Figs. 2 and 3). Radioactivity accumulated and persisted in dilated peripheral lymphatics and diffused interstitially. There was little or no tracer transport (and only after vigorous hindlimb massage) beyond the upper hindlimb or groin over a six hour period. Regional lymph nodes (popliteal, femoral, and parailiac) were either poorly visualized or more usually not seen at all. In contrast, except for one forepaw injection (Fig. 2), forelimb lymphatic channels were well visualized with rapid appearance of tracer in the axillary nodes. Lymph-

scintigraphic findings in the hindlimbs (Figs. 2 and 3) corresponded to but magnified the dilated lymphatic cisterns and collaterals located laterally within the upper hindlimb between the femoral and popliteal nodes and directly visualized after vital blue dye injection at the time of surgical exploration. In two ferrets (Fig. 3) where a detailed search under direct microscopy was carried out at operation, these hindlimb lymphatics were found to harbor nests of vigorously active adult worms, which were subsequently videotaped in motion.

In chronic postsurgical lymphatic obstruction without filarial infection, lymphoscintigraphy also showed delayed isotope uptake and proximal transport, dilated lymphatics (later confirmed at operation), and little or no passage

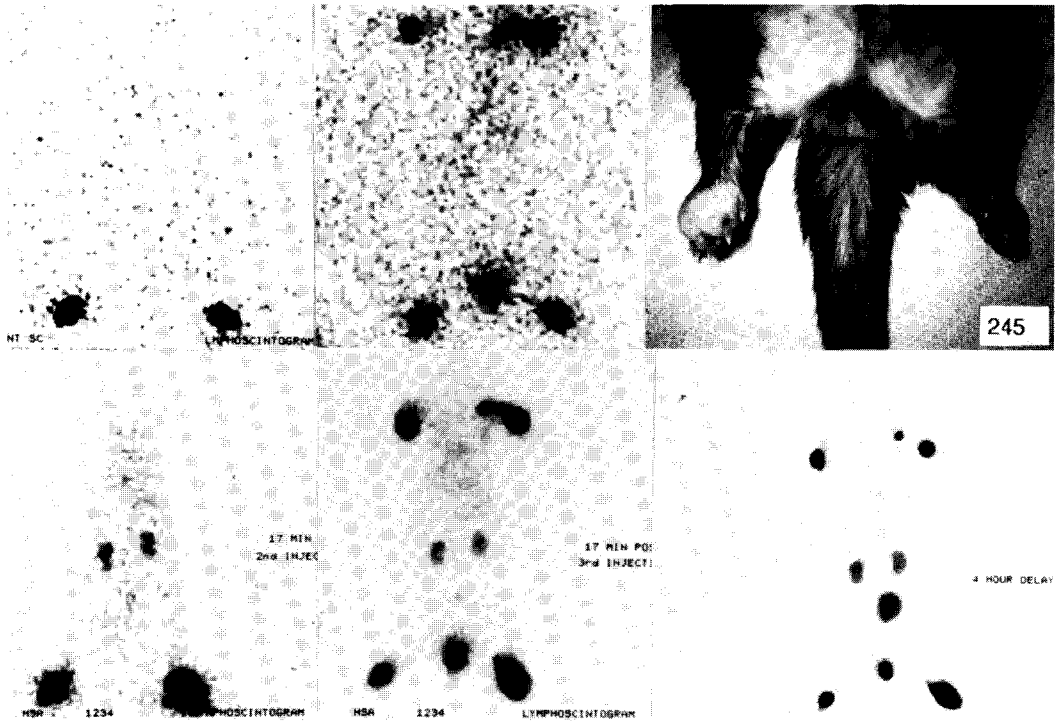


Fig. 2. Gross appearance of hindlimb edema (upper right) in ferret (#245) infected with filarial larvae in the right paw 3 years earlier, and lymphoscintigrams ( $^{99m}\text{Tc}$ -Sb colloid upper and  $^{99m}\text{Tc}$  albumin lower). Note lack of transport of both colloid and albumin from either hindlimb (with or without edema) or from the scrotum (middle upper and lower). Some technetium metabolite is also seen in both kidneys after  $^{99m}\text{Tc}$  albumin injection (lower views). It is also noteworthy after forepaw injection that radioisotope transport and nodal visualization are detected only on one side (see delayed scintiscan, lower right) despite lack of inoculation of filarial larvae into either forelimb.

beyond the groin, even though lymphedema or other disability was absent (Fig. 4).

## DISCUSSION

Whole-body lymphangiostintigraphy (LAS) using  $^{99m}\text{Tc}$ -alb as the tracer is a useful method to visualize and assess the peripheral and even more central lymphatic system (8). Bands of radioactivity representing truncal pathways are visualized promptly, and regional nodes appear after intradermal injection several minutes later even under anesthesia and typically without massage or exercise.

During the past decade, lymphoscintigraphic data has been used extensively to obtain isotopic curves of uptake ("transit times") over "areas of

interest" in an effort to assess lymphatic flow quantitatively (2,3). Whole body LAS, however, allows improved continuous images with simultaneous visualization of multiple areas of drainage and a broad integrated picture of the structure and function of the peripheral lymphatic system.

Our findings suggest that radiolabeled albumin is equal or superior to colloidal preparations. It has been claimed that the higher molecular weight compounds are more selectively absorbed into the lymphatic system and more tightly bound, and, furthermore, visualize nodes better. However, where the primary aim is truncal visualization and tight binding of non-colloidal albumin can be accomplished, there appears to be distinct advantage to using  $^{99m}\text{Tc}$ -alb as the tracer. Thus, in

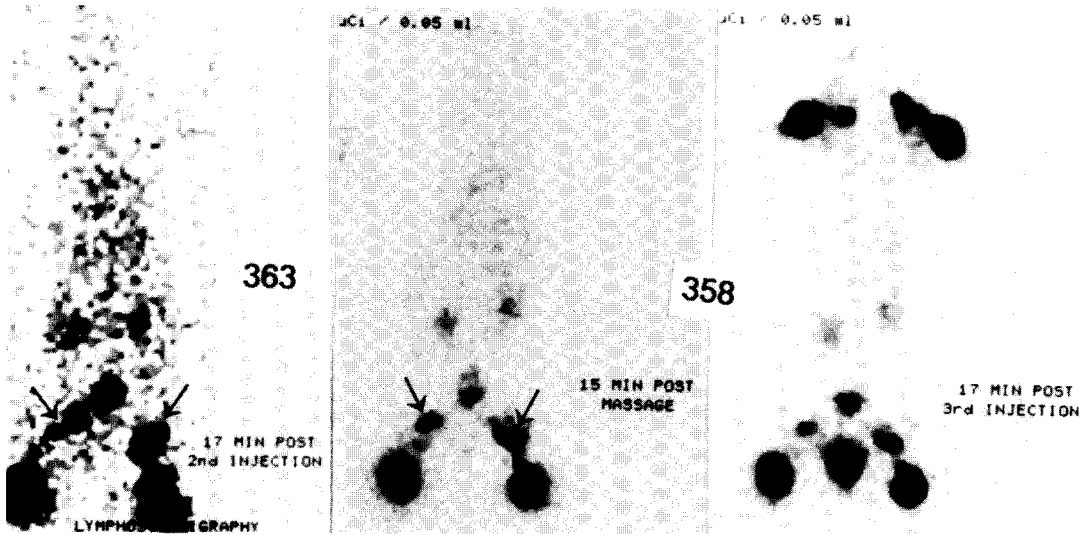


Fig. 3. Lymphoscintigrams ( $^{99m}\text{Tc}$  albumin) one year after intrascrotal inoculation of *Brugia malayi* in 2 ferrets (#363,358). Despite absence of gross edema, there is delayed tracer transport in dilated "lakes" and lack of progression past the groin. In contrast, forepaw injection (extreme right) demonstrates prompt tracer lymphatic uptake and nodal transport. Arrows represent the site of live adult worms found at surgical exploration.

control ferrets, as in patients with congenital and acquired lymphedema, colloidal preparations are superior to visualize lymph nodes but trunks are more rapidly and intensely visualized and over a greater length with  $^{99m}\text{Tc}$ -alb (8). Extralymphatic uptake is minimal at least early in the scanning process. This observation conforms to the lack of direct venous uptake and near total transport of albumin by lymphatics after intradermal injection of albumin into an extremity, particularly if the injection is of small volume and not administered under excessive pressure.

Previous studies have shown that ferrets infected with filarial larvae develop both acute and chronic signs and symptoms akin to human lymphatic filariasis from endemic *Wuchereria bancrofti* or *Brugia malayi* (10,11). Not only is the tropical eosinophilia syndrome exhibited along with systemic pathology characteristic of that condition but longstanding lymphedema appears in a substantial percentage of infected animals. However, the incidence of occult lymphatic dysfunction without overt lymphedema is not

known. Diffuse lymphatic dysplasia in these chronically infected ferrets is demonstrated by LAS, and dissection reconfirms that the outward manifestation of lymphedema may not appear for some time despite ongoing lymphatic obstruction. As in dogs with extensive surgical lymphatic blockage of the hindlimb (9), these ferret hindpaws with notable lymphatic abnormalities would presumably develop chronic lymphedema given sufficient time with gradual loss of valve competence and pumping capability of lymphatic trunks. The mechanism and pathways responsible for tissue fluid removal during this latent interval are unclear but possibly relate to collateral channels not readily visualized either by lymphography or lymphoscintigraphy or alternatively, newly formed tissue and prelymphatic channels that allow frontal movement of liquid through tissue spaces. These latter pathways may be the same ones that decompress the interstitium during therapeutic compression and massage in patients with lymphedema.

Interestingly, one infected ferret (Fig. 2) exhibited abnormalities in a

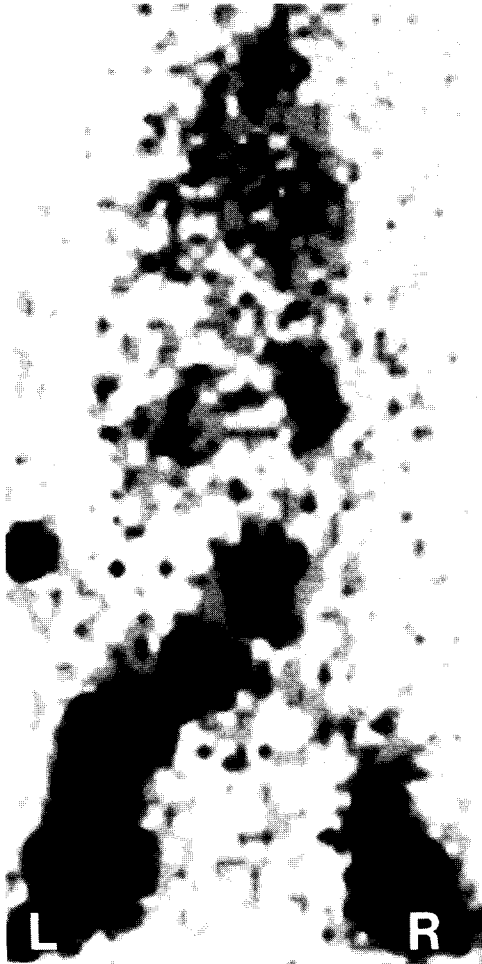

Fig. 4. Lymphoscintigram ( $^{99m}\text{Tc}$  albumin) in ferret with surgically induced lymphatic obstruction. Note massively dilated "lakes" of radioactivity that correspond to obstructed, dilated lymphatics at autopsy. A minute amount of radioisotope is seen centrally and in both kidneys.

forelimb as well as the left hindlimb despite the fact that larvae were introduced (and presumably adult worms later developed) only in the right hindlimb. Indeed, in two other ferrets (Fig. 3), larvae and/or adult worms migrated retrograde from the scrotal injection site with lodging of live adult worms between the femoral and popliteal nodes bilaterally. Such "downward" migration, for which the mechanism is poorly understood, has been described

in human filariasis. Furthermore, adult worms have also been detected in ferrets in the distal contralateral uninjected limb after larvae were inoculated unilaterally in the paw (Crandalls, unpublished observation).

The presence of active live adult worms, presumably capable of reproduction, inside dilated lymphatic cisterns between the femoral and popliteal nodes more than a year after inoculation is noteworthy. Although microfilaremia was undetectable at the time, it seems likely that microfilaria continue to be produced for long periods even without larval reinjection experimentally or, in man, reinfection. Persistence of live adult worms likely contributes to continued progression of filariasis, even after the host leaves the endemic area.

In summary, whole-body lymphoscintigraphy using  $^{99m}\text{Tc}$ -alb as tracer provides a noninvasive, simple, readily repeatable investigative tool to assess lymphatic drainage. This technique, which magnifies yet correlates closely with operative and autopsy findings, should not only be of value to study the evolution of lymphatic pathology and pathophysiology in filariasis in the laboratory, but should also prove useful for screening and evaluation of patients with filarial lymphedema in the endemic area.

#### ACKNOWLEDGEMENT

This investigation received financial support from the UNDP/World Bank/WHO Special Programme for Research and Training in Tropical Diseases (ID No.: 870051) (MHW) and from USPHS AI-19275 for development of the ferret model (CC, RC).

#### REFERENCES

1. Gooneratne, BWM: *Lymphography--Clinical and Experimental*, Butterworths, (1974), 83-121.
2. Pecking, A, R Cluzan, JP Desprez-Curely, et al: Indirect lymphoscintigraphy in patients with limb oedema. *Phlebology* 1 (1986), 211-215.

3. Weissleder, H, R Weissleder. Lymphedema: Evaluation of qualitative and quantitative lymphoscintigraphy in 238 patients. *Radiology* 167 (1988), 729-735.
4. Ege, GN: Lymphoscintigraphy: Techniques and applications in the management of breast carcinoma. *Sem. Nucl. Med.* 13 (1983), 26.
5. Nawaz, K, M Hamad, S Sadek, et al: Lymphoscintigraphy in peripheral lymphedema using technetium-labelled human serum albumin: Normal and abnormal patterns. *Lymphology* 18 (1985), 181.
6. Nawaz, K, MM Hamad, S Sadek, et al: Dynamic lymph flow imaging in lymphedema. Normal and abnormal patterns. *Clin. Nuc. Med.* 11 (1986), 653-658.
7. Samuels, LD. Lymphoscintigraphy. *Lymphology* 20 (1987), 4.
8. Williams, W, M Witte, C Witte, et al: Whole body Tc<sup>99m</sup> human serum albumin lymphangioscintigraphy. *J. Nucl. Med.* 29:972 (supplement), 1988.
9. Olszewski, W: On the pathomechanism of development of postsurgical lymphedema. *Lymphology* 6 (1973), 35.
10. Crandall, RB, JP Thompson, DH Connor, et al: Pathology of experimental infection with *Brugia malayi* in ferrets: Comparison with occult filariasis in man. *Acta Tropica* 41 (1984), 373-381.
11. Crandall, RB, CA Crandall, MK Nayar: Lymphatic filariasis in the ferret. In *Progress in Lymphology-XI*, H Partch (ed.), Excerpta Medica, Amsterdam, 1988, 675-677.

**Marlys H. Witte, M.D.**  
**Professor of Surgery**  
**University of Arizona College**  
**of Medicine**  
**1501 N. Campbell Avenue**  
**Tucson, AZ 85724 USA**