

*LYMPHOGRAPHIA***LOCALIZED HEPATIC OIL EMBOLIZATION
FOLLOWING LYMPHOGRAPHY****J. Bruna**

Department of Radiology, Charles University, Prague, Czechoslovakia

CASE REPORT

A 60-year-old man developed lymphedema of the right leg three months prior to contrast oil lymphography. Physical examination revealed palpable lymph nodes in the right groin. A transrectal needle biopsy of a firm prostate gland disclosed adenocarcinoma on histology. Plain x-ray and radioisotope scintigraphy of the bones showed multifocal changes consistent with skeletal metastases. Computed axial tomography (CT) of the abdomen and pelvis showed enlarged para-aortic lymph nodes, infiltration of the posterior urinary bladder wall, lack of function of the right kidney, and thrombosis of the external iliac vein. Dorsal pedal contrast oil lymphography (6-7ml ethiodol) showed bilateral blockage at the level of the external iliac lymph nodes (*Fig. 1*), with prominent filling of the portal branches of the ventral segment of the left lobe of the liver (*Fig. 2*). Ethiodol was still detectable in the liver as long as 10 days after injection (*Fig. 3*). Despite chemotherapy the patient died soon thereafter. Post mortem examination confirmed prostatic adenocarcinomatous infiltration of the true pelvis, para-aortic and pelvic lymph nodes, hydro-nephrosis, right hydroureter, metastases of the lumbar and sacral vertebrae, and lymphedema of the legs and scrotum.

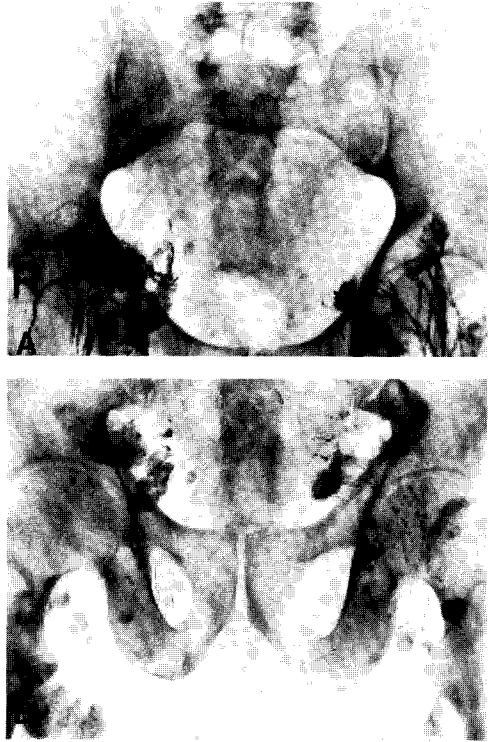


Fig. 1. Lymphangiography showing metastatic blockage at the level of the external iliac lymph nodes bilaterally. A--initial phase; B--storage or delayed phase.

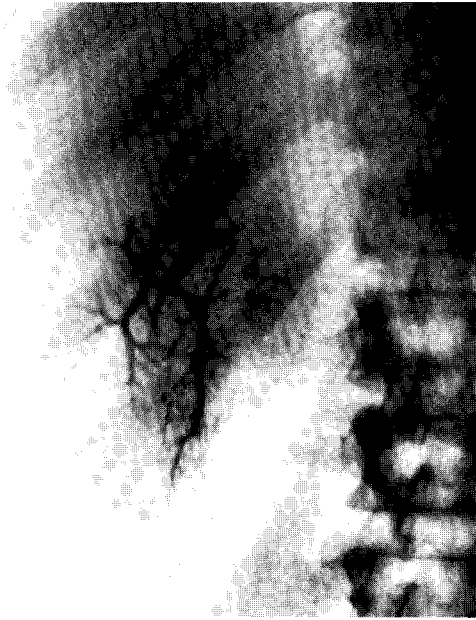

Fig. 2. Plain x-ray of the abdomen showing oil embolization in the portal venous radicles of the left lobe.

COMMENT

Hepatic oil embolization is a rare complication of oil contrast lymphography (1-4). It has been encountered from blockage of lumbar lymphatics or the thoracic duct sometimes with concomitant inferior vena caval thrombosis (5-8). Most patients have metastatic involvement of retroperitoneal lymph nodes from testicular or uterine cancer or occasionally from lymphoma or adenocarcinoma of the colon. Commonly, lumbar lymphatics and nodes are diffusely obstructed but on occasion only the pelvic lymph nodes are blocked (9,10). If a large amount of contrast reaches the hepatic parenchyma, the branches of the portal vein are visualized as in our patient and clearance is slow over many days. Where communication between the lymphatic and portal system is limited, the liver receives only a small quantity of contrast and there occurs merely a diffuse granular appearance to the liver. Localized embolization of the ventral segment of the left lobe of the liver is unusual and

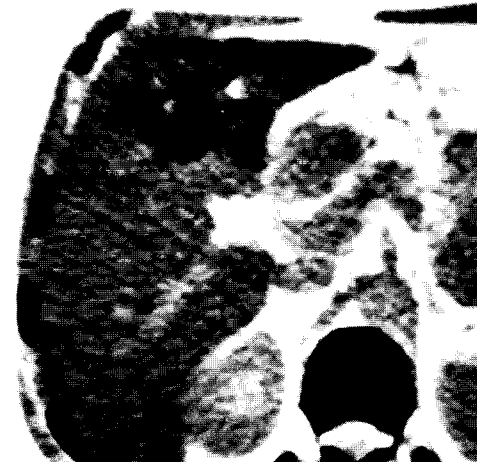
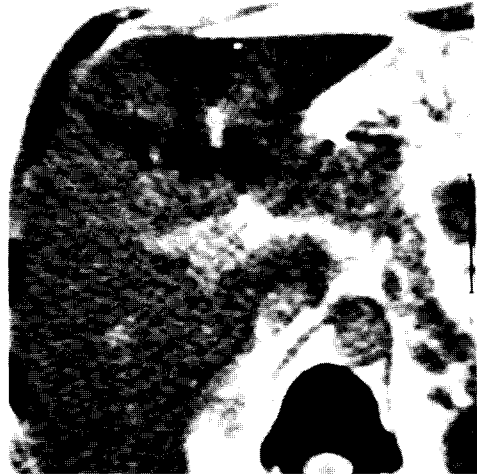
Fig. 3. Abdominal computed tomography 10 days after lymphogram demonstrating persistence of contrast medium in the liver.

suggests a lymph-umbilical communication via parietal lymphatic trunks rather than collateral visceral lymphatic plexuses.

REFERENCES

1. Bruna, J: The types of collateral lymphatic circulation. *Lymphology* 7 (1974), 61.
2. Chavez, CM, JD Picard, D Davis: Liver opacification following lymphangiography. *Surgery* 63 (1968), 564.
3. Koehler, PR: Complication of lymphography. *Lymphology* 1 (1968), 117.
4. Bruneton, JN, A Le Treut, M Abbes, et al: Hepatic oil embolization following

- lymphangiography. *Lymphology* 15 (1982), 70.
5. Bodie, JF, DS Linto: Hepatic oil embolization as a complication of lymphography. *Radiology* 99 (1971), 317.
 6. Hecht, H, W Bedron, D Baker: Hepatic oil embolization following lymphangiography in a child with neuroblastoma. *Amer. J. Roentgenol.* 104 (1968), 860.
 7. Hoshi, H: Hepatic oil embolism after lymphography in a patient with carcinoma of the uterine cervix. *Jap. J. Clin. Radiol.* 28 (1983), 163.
 8. Lechner, G, P Riedl, O Zechner: Zum Mechanismus der Kontrastmitteldarstellung der Leber nach Lymphographie. *Fortschr. Rontgenstr.* 125 (1976), 355.
 9. Chadacek, Z, M Halouskova: Lymphovenose Verbindung zwischen den Lymphgefassen des Beckens und dem Pfortadersystem. *Fortschr. Rontgenstr.* 105 (1966), 227.
 10. Pujol, H, JL Lamarque, H Balmes: Hepatomegalie au Lipiodol Ultrafluide au cours d'une lymphographie. *J. Radiol.* 45 (1964), 366.

Prof. Josef Bruna, M.D., DrSc
Clinic of Radiology
Charles University in Prague
Srobarova 50, 10034 Prague 10
CZECHOSLOVAKIA