

PREDICTIVE ROLE OF IMAGING IN SENTINEL LYMPH NODE DISSECTION FOR MELANOMA

A.M. Ho, R. Avery, E.A. Krupinski, J. Warneke, P.H. Kuo

Departments of Medical Imaging (AMH,EAK,PHK) and Surgical Oncology (JW), University of Arizona, Tucson, Arizona, USA

ABSTRACT

A retrospective study of 67 patients with metastatic melanoma was performed to evaluate if imaging from lymphoscintigraphy could predict a higher miss rate if only the most radioactive node were removed. Following protocol for sentinel node biopsy, the surgeon resected all lymph nodes containing radioactivity >10% of the most radioactive node. A correlation was performed between the radioactive counts of the lymph nodes and the presence of metastases. The percentage of cases in which the most radioactive node was negative for metastasis on pathology was calculated. Two nuclear medicine physicians read the images from lymphoscintigraphy specifically to determine if the first lymph node visualized became less intense than other nodes on later images. Sensitivity, specificity, positive predictive value (PPV), and negative predictive value (NPV) were calculated. In 13 of 67 (19%) patients, the most radioactive lymph node was negative for metastasis while a less radioactive node contained metastatic disease. Consensus reading by the nuclear medicine physicians determined that in 9 cases, the first lymph node visualized became less intense than another lymph node on later images. Of the 9 cases, 4 were true positive and 5 were false positive when correlated with intraoperative count rate and pathology. Of the cases where the most radioactive node was not positive on

histopathology (n = 13), the consensus reading by the nuclear medicine physicians reported 4 of them (31%). Imaging by lymphoscintigram had a sensitivity 31%, specificity 91%, positive predictive value 44%, and negative predictive value 85% for predicting whether the most radioactive lymph node at surgery would be negative for metastasis at pathology. We conclude that in patients with melanoma, lymphoscintigraphy has high specificity and negative predictive value but modest sensitivity and positive predictive value for detecting when the sentinel node will not be the most radioactive lymph node during sentinel lymph node dissection. These findings support that dynamic imaging by lymphoscintigraphy has a role in surgical planning but that the imaging protocol could benefit from further optimization.

Keywords: lymphoscintigraphy, sentinel lymph node dissection, melanoma, metastasis, specificity, predictive value

Melanoma is a malignant tumor of melanocytes that accounts for the vast majority of deaths related to skin cancer. This malignancy has also shown increasing incidence rates for at least 30 years (1). Since 2008, melanoma has risen from the sixth most common cancer in men to the fifth most common cancer, while it remains the seventh most common cancer in women. The American Cancer Society estimates that in

2014 there will be 76,100 new cases of melanoma detected with an estimated 9,710 deaths (1). For localized melanoma, the 5-year survival rate is 98% but decreases to 16% for distant stage disease (1).

Nodal metastasis of cutaneous melanoma occurs through the lymphatics to regional lymph nodes (2). Sentinel lymph node dissection is therefore essential for melanoma staging (3). Sentinel lymph node (SLN) dissection is directed towards removal of the first lymph nodes encountered via draining lymphatics before these lymphatics extend to additional nodes. Morton et al validated that in the absence of metastatic disease in a sentinel node, the additional nodes in that field would rarely contain metastasis (4).

Identification of the SLN is performed by lymphoscintigraphy with either intra-dermal injection of a vital blue dye and/or radiolabeled sulfur colloid around the site of tumor. The radiolabeled sulfur colloid is transported either passively or by macrophages through the lymphatic vessels to the draining lymph nodes.

Intraoperative use of a gamma probe for radioactivity detection within the lymph nodes has been shown to improve the rate of SLN identification (5). However, multiple lymph nodes are often detected with gamma probe evaluation leading to uncertainty as to whether the most radioactive lymph node is the true sentinel lymph node or a secondary node. A 2001 study demonstrated that if only the most radioactive lymph node was removed in each nodal basin, 13.1% of nodal basins with positive sentinel nodes would have been missed (6).

Additionally, Carlson et al demonstrated that tumor burden within a metastatic sentinel lymph node influences the uptake of radioactive colloid (7). Lymph nodes that have been infiltrated with tumor have decreased numbers of antigen presenting cells within the lymph node resulting in a reduced capability to take up and retain radiotracers (8). Therefore, metastatic lymph nodes might retain less radiotracer compared to secondary

lymph nodes and may not be the most radioactive lymph node at surgery. Consequently, it is important to remove lymph nodes with lower radioactive counts. Current protocols routinely target lymph nodes with radioactivity approximately 10% or higher compared to the most radioactive node for dissection, as well as any other clinically suspicious nodes (6, 9-12).

This study of patients with metastatic melanoma was performed to evaluate if imaging using lymphoscintigraphy can predict if the most radioactive lymph node at surgery will be negative for metastasis at pathology.

MATERIALS AND METHODS

A retrospective review from April 2004 to December 2011 was performed on 67 patients from a quality control surgical database of patients with melanoma who had positive nodal disease after lymphoscintigraphy-directed sentinel lymph node dissection at the University of Arizona Medical Center. This review was approved by the Institutional Review Board and a waiver to obtain informed consent was granted. During this time period, the imaging and operating technique did not change significantly.

Sentinel lymph node dissection was generally performed for melanoma with ≥ 1 mm thickness. Lymphoscintigraphy was performed with an intradermal injection of approximately 37MBq (1 mCi) of filtered Technetium-99m labeled sulfur colloid adjacent to the melanoma lesion or biopsy site in four divided doses under sterile technique by the nuclear medicine technologist. Each dose was in an approximate volume of 0.03 mL (for a total volume of 0.12 mL). Dynamic imaging started immediately after injection with 1-minute frames acquired for the first 15 minutes, followed by 5-minute static images until visualization of a node or scheduled surgery time. Imaging was obtained in the anterior and posterior projections. Delayed static images were also obtained in

the lateral projections as necessary. Transmission imaging was also performed using a Cobalt-57 flood source. The technologist, under the direct supervision of the nuclear physician, marked the skin overlying the foci of greatest radiotracer accumulation.

Operating time was 1 to 2 hours (typically 90 minutes) from the time of injection. Intraoperatively, a handheld gamma probe was used to detect radiolabeled lymph nodes, and the most radioactive lymph node and all lymph nodes with radioactivity of >10% of the most radioactive node were dissected. Palpable or suspicious lymph nodes were also removed. No blue dye was used at the time of surgery. One surgeon performed all the dissections during the study period. The surgeon used the markings on the skin only to identify the general region for dissection. The surgeon measured the count rate of each node away from the operative field and therefore away from background counts from the patient. This count rate for each node was recorded in the operative note, which was used for the retrospective analysis.

All surgically resected lymph nodes were labeled and after serial sectioning were examined histopathologically with routine hematoxylin and eosin and immunochemical staining for S-100 protein, melanoma-associated antigen HMB-45, and melan A. The pathology of each sentinel lymph node was correlated with the radioactive counts.

For each patient, the removed lymph nodes were categorized into nodal basins. The nodal basins with more than one lymph node removed were selected for analysis. Nodal basins with only one lymph node removed were excluded since a second node is not available for comparison. Statistical analysis was performed to determine how frequently the less radioactive nodes were positive for metastases. The miss rate was calculated as the percentage of cases in which the most radioactive lymph node was negative for metastasis, while a less radioactive lymph node in the same nodal basin was positive for malignancy.

Two board-certified nuclear physicians first independently reviewed the lymphoscintigraphy images blindly and discrepancies were resolved by consensus. A scan was called "positive" if the first node visualized became less intense than other nodes on more delayed imaging. In this case, the radiologist predicts that the most radioactive node seen during surgery will not have tumor and another less radioactive node will have tumor. A scan was called "negative" if the first node visualized remained the most intense node on more delayed imaging. In this case, the radiologist predicts the most radioactive node will have tumor. Therefore, a true positive case is "positive" on imaging (the first node visualized became less intense than another node on delayed imaging) and the most radioactive lymph node is negative for metastasis. This is a case where the radiologist has correctly predicted based on imaging that the most radioactive node seen during surgery will not have tumor. A false positive case is "positive" on imaging, but the most radioactive lymph node is positive for metastasis. This is a case where the radiologist has incorrectly predicted based on imaging that the most radioactive node seen during surgery will not have tumor. In addition to the miss rate, statistical evaluation to calculate sensitivity, specificity, positive predictive value (PPV), and negative predictive value (NPV) was performed.

RESULTS

Sixty-seven patients, 22 women and 45 men, underwent lymphoscintigraphy-directed SLN dissection and had nodal metastases at pathology. The average age was 57 years old. Fifty-eight cases demonstrated a single draining lymph node basin. In 9 cases, there were multiple draining nodal basins. A total of 148 lymph nodes were collected during surgery, and after pathological dissection a total of 170 lymph nodes were analyzed for metastases. The mean number of sentinel lymph nodes collected per patient was 2.5.

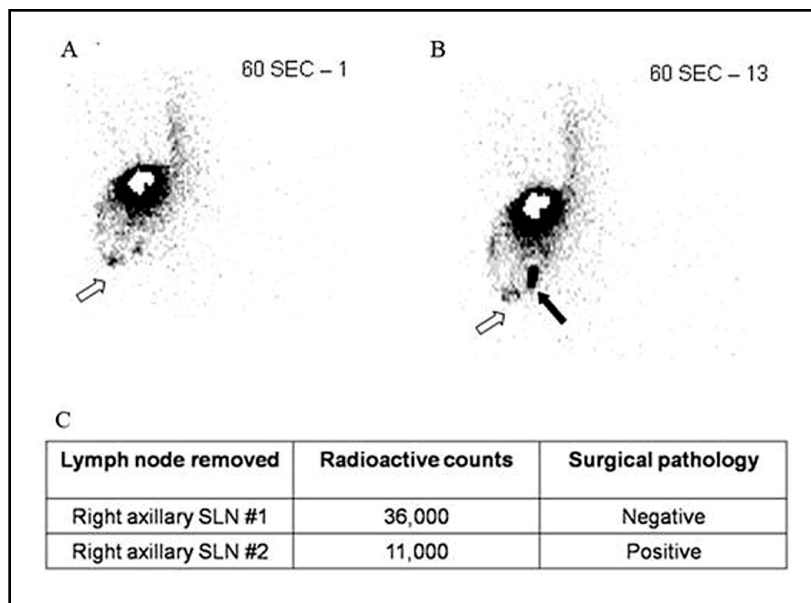


Fig. 1. True positive case. 53 year-old man with history of melanoma in the right posterior shoulder. In the 1-minute frame (A), the first lymph node is visualized (open arrow). In the 13-minute frame (B), the first lymph node visualized became less intense than another node (solid arrow). Pathologic examination revealed that the most radioactive lymph node was negative for tumor and the less radioactive lymph node was positive for tumor (C).

There were 78 positive sentinel lymph nodes found in 68 nodal basins.

To determine the frequency that a less radioactive SLN was positive for metastasis, while the most radioactive lymph node was not, 42 positive nodal basins were identified in which more than one SLN was removed. In these nodal basins, 13 cases were identified (31%) in which the most radioactive lymph node was found to be negative for metastasis, while another lymph node with lower radioactivity was positive. Overall, in 13 of 68 nodal basins (19%) the most radioactive node was negative at pathology when a less radioactive node was positive at pathology. Therefore the miss rate would have been 19% (13/68) if only the most radioactive node was removed overall. In these 13 cases, the most radioactive node had on average a 39% higher radioactive count rate than the less radioactive node that was positive on histology (SD = 34%; median = 28%; range = 2.8% - 93%).

Images from lymphoscintigraphy were analyzed for all 67 patients to evaluate whether the first lymph node visualized became less intense than other lymph nodes in the same nodal basin. A consensus was made for 9 cases in which the first lymph node became less intense than other lymph nodes in the same nodal basin. Of the 9 cases, 4 were true positive and 5 were false positive when correlated with intraoperative count rate and pathology. Of the cases where the most radioactive node was not positive on histopathology (n = 13), the consensus reading by the radiologists reported 4 of them (4/13 = 31%). Representative examples of true positives are demonstrated in *Figs. 1 and 2*. An example of a false positive case is provided in *Fig. 3*. In patients with melanoma, lymphoscintigraphy has high specificity and negative predictive value but modest sensitivity and positive predictive value for detecting when the sentinel node will not be the most radioactive node (*Table 1*). Imaging

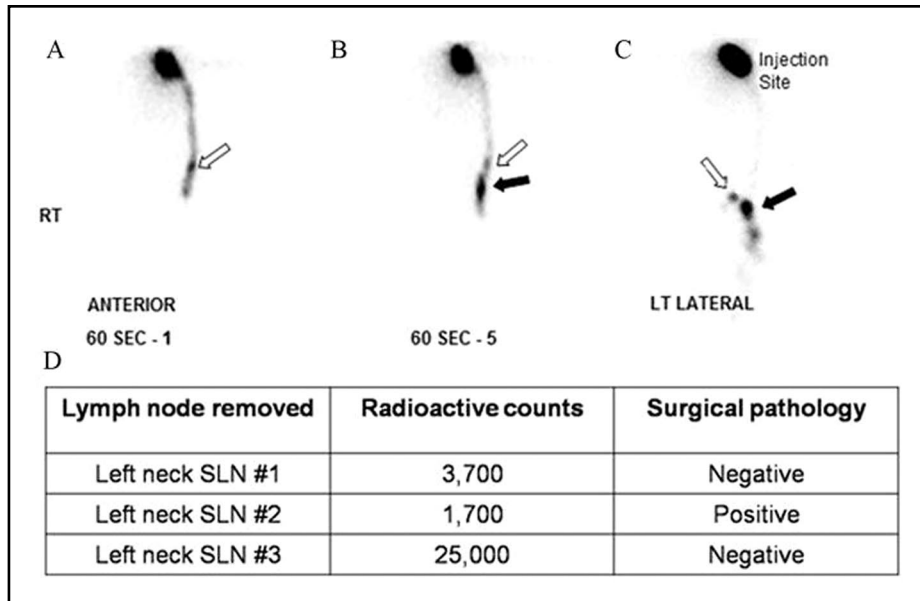


Fig. 2. True positive case. 77 year-old man with history of melanoma in the left scalp. In the 1-minute frame (A), the first lymph node is visualized (open arrow). In the 5-minute frame (B), the first lymph node visualized became less intense than another node (solid arrow). In the 18-minute static frame (C), the first lymph node remains less intense than another node. Pathologic evaluation revealed that the most radioactive lymph node was negative for tumor and the less radioactive lymph node was positive for tumor (D).

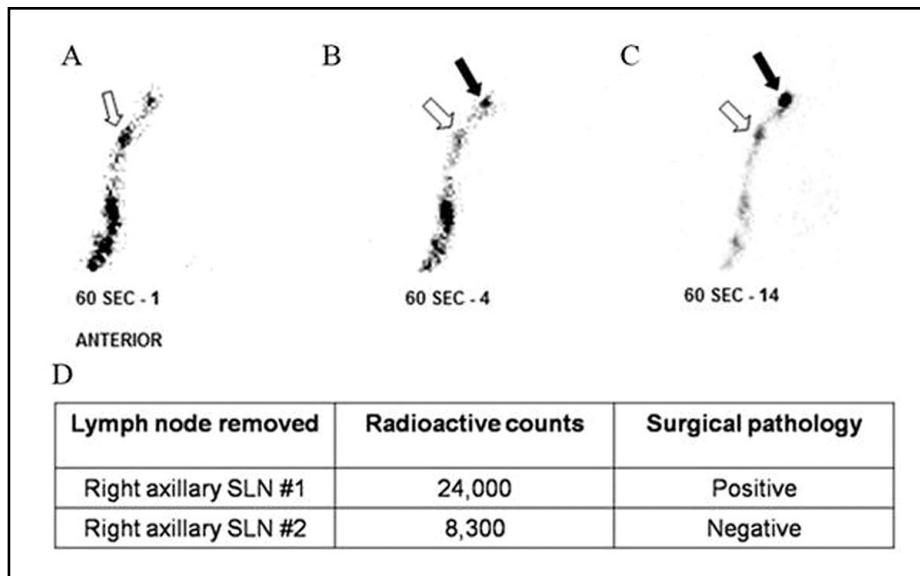


Fig. 3. False positive case. 58 year-old woman with history of melanoma in the right thumb. In the 3-minute frame (A), the first lymph node is visualized (open arrow). In the 4-minute frame (B), the first lymph node visualized became less intense than another node (solid arrow). In the 14-minute frame (C), the first lymph node remains less intense than another node. Pathologic evaluation revealed that the most radioactive lymph node was positive for tumor and the less radioactive lymph node was negative for tumor (D).

TABLE 1
Sensitivity, Specificity, Positive Predictive Value, and Negative Predictive Value

Reader	Sensitivity	Specificity	PPV	NPV
1	0.31	0.89	0.40	0.84
2	0.15	0.91	0.29	0.82
Consensus	0.31	0.91	0.44	0.85

predicted the most radioactive lymph node would not have metastatic disease with a consensus sensitivity of 31%, specificity of 91%, PPV 44%, and NPV 84%.

DISCUSSION

Lymphoscintigraphy is well established for surgical localization of sentinel lymph nodes in patients with cutaneous melanoma for the staging of metastatic disease, and this study investigated whether imaging could predict a higher miss rate if only the most radioactive node were removed. To accomplish this, we first examined the miss rate if only the most radioactive node were removed. We then reviewed the imaging specifically to assess if the first node visualized became less intense than other nodes at a later time point. The results of the radioactive counts and pathology from the removed nodes were compared with imaging reads.

The results of this study confirm the findings in previous studies that if only the most radioactive node is removed, the positive sentinel node would be missed at a low but still clinically unacceptable rate. In our study, 19% of the sentinel lymph nodes with the highest radioactive counts were negative for metastases, while less radioactive lymph nodes were positive for metastases. The Sunbelt Melanoma and Carlson groups demonstrated a similar miss rate of 23% and 19%, respectively (6,7).

To our knowledge, this is the first study to determine whether lymphoscintigraphy imaging can predict if the most radioactive

lymph node at surgery will be negative for metastasis at pathology. While the sensitivity was relatively low, a positive predictive value approaching 50% indicates clinical potential. For example, a positive scan may indicate the need for greater caution in measuring the radioactivity of nodes and warrant removal of additional nodes. Since sentinel lymph node dissection occurs after the lymphoscintigraphy imaging, the relative count rates obtained by the intraoperative gamma probe may change from the time of imaging. The importance of the imaging is not to target a specific node of lower radioactivity for surgery but to identify that a patient has a higher probability of atypical lymphatic drainage resulting in a higher miss rate if only the most radioactive node were removed. Therefore, in these instances, it is important to communicate these findings with the surgeons to aid in surgical planning and accurate staging of the patient's disease.

In the future, a prospective trial may have improved sensitivity by utilizing a protocol developed specifically for this purpose. For example, optimization may entail shorter time points, cameras utilizing a larger field of view, or SPECT/CT (13-14). SPECT/CT could aid the surgeon to localize which node was the "hottest" sentinel node rather than using the intraoperatively detected radioactive counts, which is a representation of nodal activity more delayed than imaging. Quantitative analysis with regions of interest may be superior to visual assessment. Since the tumor burden within a lymph node may influence the uptake of radioactive colloid, future studies could evaluate the relationship amongst percent tumor burden, radioactive count rate, and imaging appearance.

Utilization of receptor-targeted radiopharmaceuticals for lymphoscintigraphy such as Technetium Tc99m Tilmanocept would also be interesting to study for this purpose (15-17). Also, future studies with a larger patient population and prospective evaluation of surgical removal of lymph

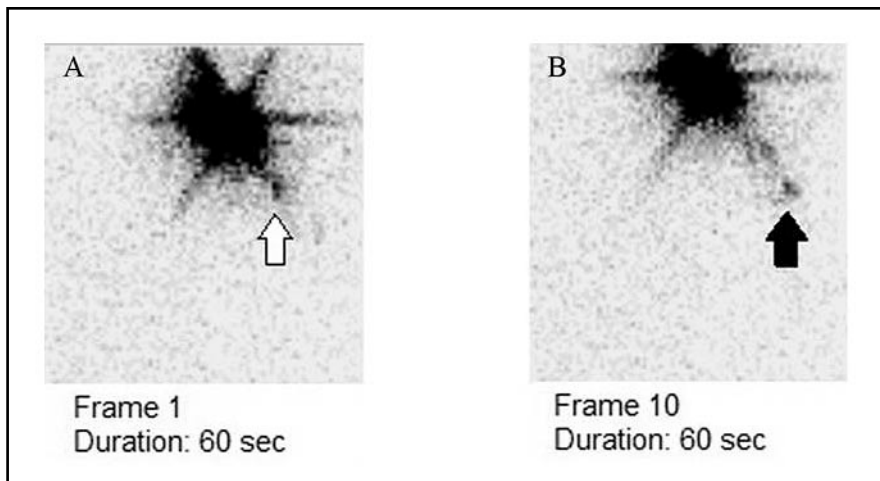


Fig. 4. Missed case. 67 year-old man with left shoulder melanoma. In the 1-minute frame (A), the first lymph node in the left axilla is visualized (open arrow). In the 10-minute frame (B), the first lymph node visualized became less intense than another node (solid arrow). Sentinel lymph node dissection was negative for metastatic disease by pathologic examination. Later, the patient was found to have a biopsy proven metastatic nodal disease.

nodes with radioactive count rates lower than the 10% may be performed to investigate the clinical impact of our findings.

Our study has several limitations. As mentioned earlier, the nodes on imaging cannot always be directly correlated to the surgically removed nodes. Also, the study was retrospective in design. While the subjects were not consecutive, they were randomly collected. To better understand the inter-observer variability, a larger pool of readers is required (our institution has two nuclear medicine physicians). Finally, while the rate is certainly low, we do not know exactly how often patients at our institution have a missed positive sentinel node with counts below 10% of the most radioactive lymph node. For example, a patient was diagnosed with left shoulder melanoma and had a sentinel lymph node dissection that was negative for metastasis. On clinical follow-up, the patient was later confirmed surgically to have local metastatic nodes. Retrospective review of the lymphoscintigraphy study (Fig. 4) demonstrates that the first lymph node visualized becomes less intense than another node. In this instance, perhaps surgical removal of

lymph nodes with radioactive count rates lower than 10% of the most radioactive lymph node may have accurately staged this patient.

CONCLUSION

Melanoma patients with nodal metastasis are known to have a worse prognosis than those without nodal metastasis. Therefore, accurate identification of nodal metastasis is crucial for staging, prognosis and therapy. Our study shows that imaging by lymphoscintigraphy has both a high specificity and negative predictive value but modest sensitivity and positive predictive value for detecting when the sentinel node at pathologic examination will not be the most radioactive node at surgery. These findings are promising that an optimized imaging protocol may play a future role in surgical planning for improved sentinel lymph node dissection.

REFERENCES

1. American Cancer Society. Cancer Facts & Figures 2014. Available at:

- <http://www.cancer.org/acs/groups/content/@research/documents/webcontent/acspc-042151.pdf>. Accessed: August 4, 2014.
2. Reintgen, D, CW Cruse, K Wells, et al: The orderly progression of melanoma nodal metastases. *Ann. Surg.* 220 (1994), 759-767.
 3. Gershenwald, JE, W Thompson, PF Mansfield, et al: Multi-institutional melanoma lymphatic mapping experience: the prognostic value of sentinel lymph node status in 612 stage I or II melanoma patients. *J. Clin. Oncol.* 17 (1999), 976-983.
 4. Morton, DL, DR Wen, JH Wong, et al: Technical details of intraoperative lymphatic mapping for early stage melanoma. *Arch. Surg.* 127 (1992), 392-399.
 5. Gershenwald, JE, CH Tseng, W Thompson, et al: Improved sentinel lymph node localization in patients with primary melanoma with the use of radiolabeled colloid. *Surgery* 124 (1998), 203-210.
 6. McMasters, KM, DS Reintgen, MI Ross, et al: Sentinel lymph node biopsy for melanoma: how many radioactive nodes should be removed? *Ann. Surg. Oncol.* 8 (2001), 192-197.
 7. Carlson, GW, DR Murray, V Thourani, et al: The definition of the sentinel lymph node in melanoma based on radioactive counts. *Ann. Surg. Oncol.* 9 (2002), 929-933.
 8. Faries, MB, I Bedrosian, C Reynolds, et al: Active macromolecules uptake by lymph node antigen-presenting cells: A novel mechanism in determining sentinel lymph node status. *Ann. Surg. Oncol.* 7 (2000), 98-105.
 9. Liu, LC, BM Parrett, T Jenkins, et al: Selective sentinel lymph node dissection for melanoma: importance of harvesting nodes with lower radioactive counts without the need for blue dye. *Ann. Surg. Oncol.* 18 (2011), 2919-2924.
 10. Emery, RE, JS Stevens, RW Nance, et al: Sentinel node staging of primary melanoma by the "10% rule": Pathology and clinical outcomes. *Am. J. Surg.* 193 (2007), 618-622.
 11. Porter, GA, MI Ross, RS Berman, et al: How many lymph nodes are enough during sentinel lymphadenectomy for primary melanoma? *Surgery* 128 (2000), 306-311.
 12. Chagpar, AB, CR Scoggins, RC Martin 2nd, et al: Are 3 sentinel nodes sufficient? *Arch. Surg.* 142 (2007), 456-459.
 13. Stoffels, I, C Boy, T Pöppel, et al: Association between sentinel lymph node excision with or without preoperative SPECT/CT and metastatic node detection and disease-free survival in melanoma. *JAMA* 308 (2012), 1007-1014.
 14. Wagner, T, J Buscombe, G Gnanasegaran, et al: SPECT/CT in sentinel node imaging. *Nucl. Med. Commun.* 34 (2013), 191-202.
 15. Sondak, VK, DW King, JS Zager, et al: Combined analysis of phase III trials evaluating [^{99m}Tc]tilmanocept and vital blue dye for identification of sentinel lymph nodes in clinically node-negative cutaneous melanoma. *Ann. Surg. Oncol.* 20 (2013), 680-688.
 16. Leong, SP, J Kim, M Ross, et al: A phase 2 study of (^{99m}Tc)-tilmanocept in the detection of sentinel lymph nodes in melanoma and breast cancer. *Ann Surg Oncol.* 18 (2011), 961-969.
 17. Qin, Z, DJ Hall, MA Liss, et al: Optimization via specific fluorescence brightness of a receptor-targeted probe for optical imaging and positron emission tomography of sentinel lymph nodes. *J. Biomed. Opt.* 18 (2013), 101315.

Phillip H. Kuo, M.D. Ph.D.
Department of Medical Imaging
1501 N. Campbell Avenue
PO Box 245067
Tucson, AZ 85724-5067 USA
Email: pkuo@email.arizona.edu