

SURGICAL PREVENTION AND TREATMENT OF LYMPHEDEMA AFTER LYMPH NODE DISSECTION IN PATIENTS WITH CUTANEOUS MELANOMA

F. Boccardo, F. De Cian, C.C. Campisi, L. Molinari, S. Spinaci, S. Dessalvi, G. Talamo,
Caterina Campisi, G. Villa, C. Bellini, A. Parodi, P.L. Santi, C. Campisi

Department of Surgery (FB,LM,SS,SD,GT,CC), Unit of Lymphatic Surgery, Unit of Surgical Oncology (FDC), Unit of Plastic and Reconstructive Surgery (CCC,PLS), Unit of Dermatology (Caterina Campisi), Unit of Nuclear Medicine (GV), Department of Pediatrics (CB), G. Gaslini Institute, Genoa, Italy, IRCCS S. Martino Hospital-Cancer Institute (IST), University of Genoa, Italy

ABSTRACT

Despite the development of minimal access dissection techniques, use of superficial groin dissection alone, and other recommendations to reduce morbidity in melanoma treatment, the incidence of lymphedema is still significant. The purpose of the current study was to assess the efficacy of microsurgical methods to limit the morbidity of inguinal lymphadenectomy. We conducted a retrospective review of patients who underwent groin dissection for melanoma treatment from February 2006 to April 2009. A total of 59 melanoma patients with positive groin lymph nodes comprised 18 patients (T-group) with melanoma in the trunk and 41 patients (E-group) who had melanoma in an extremity and currently have lymphedema. The T-group patients underwent primary prevention of lymphedema with microsurgical lymphatic-venous anastomoses (LVA) performed simultaneously with groin dissection. The E-group patients underwent LVA to treat the secondary lymphedema after an accurate oncological and lymphological assessment. Limb volume measurements and lymphoscintigraphy were performed pre- and post-operatively to assess short and long term outcome. No lymphedema occurred after

microsurgical primary preventive approach in the T- group. Significant (average 80% reduction of pre-op excess volume) reduction of lymphedema resulted after microsurgical treatment for secondary leg lymphedema. Post-operative lymphoscintigraphy in 35 patients demonstrated patency of microsurgical anastomoses in all cases with an average follow-up of 42 months. Study results demonstrate that microsurgical LVA primary prevention prevented lymphedema after inguinal lymphadenectomy in the T-group patients. In addition, lymphatic-venous multiple anastomoses proved to be a successful treatment for clinical lymphedema with particular success if treated at the early stages.

Keywords: cutaneous melanoma, lymphatic morbidity, lymphedema, primary prevention, microsurgery

Lymph node metastasis from melanoma of the lower extremities commonly involves the inguinal nodes. In cases of lymphatic metastasis, surgery represents the gold standard, and it is curative for most melanoma patients. Inguinal dissection, with or without iliac and obturator dissection, is the treatment of choice for patients with micro- and macroscopic nodal metastasis and absence

TABLE 1
Demographic and Pathologic
Characteristics of Study Patients
in Both Groups

	T-Group	E-Group
Gender		
Female	11	23
Male	7	18
Age (Mean; range)	53.7 (21-76) yrs	54.1 (23-79) yrs
BMI (Mean; range)	29.2 (19.4-43.6)	28.9 (19.2-41.7)
Primary site		
Extremity	/	41
Trunk	18	/
Palpable disease	3	7
Micrometastatic disease	15	34
N. of positive nodes		
1	11	25
2-3	6	12
4+	1	4
Lymphedema stage		
I A	18	/
I B	/	11
II A	/	12
II B/III A	/	18

of distant disease. However, superficial and deep groin dissection is associated with significant morbidity (1-3). Possible complications include lymphangitis, wound dehiscence, lymphocele, hematomas, venous thrombosis, and lymphedema (4), and various procedures have been attempted to limit these complications (5). In this retrospective study we examined both prevention and treatment of lymphedema associated with melanoma and groin lymphadenopathy.

PATIENTS AND METHODS

A retrospective review of patients undergoing groin dissection in melanoma

treatment in our facility from February 2006 to April 2009 was conducted. Patients had previously signed a specific consent to indicate the kind of operation, possible risks, and complications to participate in procedures of lymphedema microsurgical prevention and treatment. The study was previously approved by the hospital's ethics board.

A total of 63 melanoma patients with positive groin lymph nodes were identified. Four patients were excluded because one died, two had preexisting volume discrepancy in the extremities, and one did not complete the follow-up. Therefore, 59 patients were suitable candidates to take part in this study. Eighteen patients (T-group with Stage IA – no lymphedema) had melanoma in the trunk and 41 patients (E-group) had melanoma in an extremity with lymphedema. Demographic and pathologic characteristics of patients undergoing groin dissection are reported in *Table 1*.

The T-group underwent primary prevention of lymphedema with microsurgical lymphatic-venous anastomoses (LVA) performed simultaneously with groin dissection (Ly.M.P.H.A.: Lymphatic Microsurgical Preventive Healing Approach) (6). LVA was carried out between lymphatics distal to the inguinal node and a collateral branch of the great saphenous vein (*Fig. 1*). Two ml of blue-dye was injected intradermally, subcutaneously, and deeply beneath the muscular fascia at the medium third of the medial surface of the thigh to identify groin lymphatic vessels draining the lower limb. The injection was performed 5 minutes on average before skin incision of the groin. During groin superficial lymphadenectomy, blue lymphatics seen merging at inguinal node were isolated, closed by titanium clips, cut from nodal capsule and prepared for anastomoses. A collateral branch of the great saphenous vein was also identified and prepared. The competence of the vein valvular system for unidirectional flow was ensured before anastomoses.

Patients in the E-group underwent an

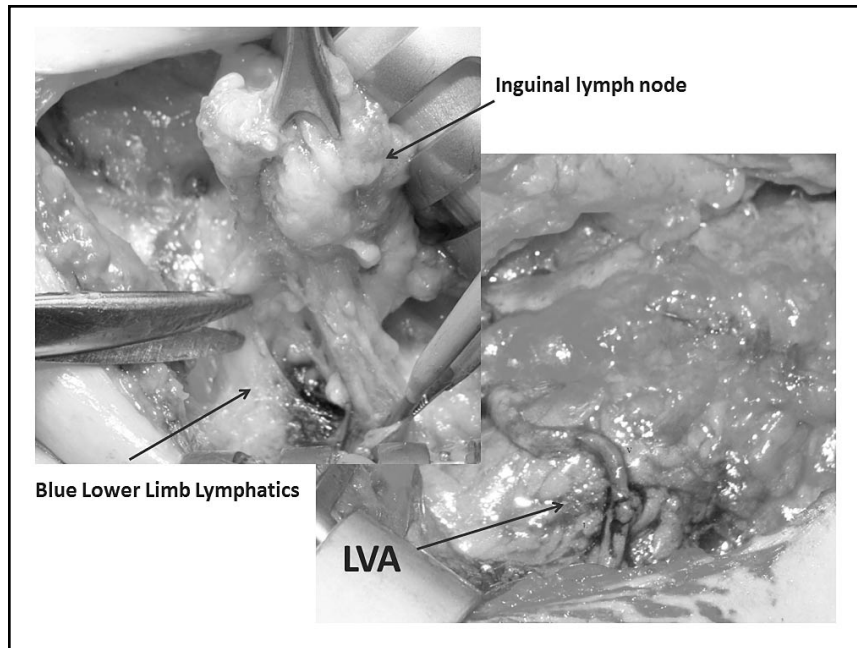


Fig. 1. Operative photographs demonstrating lymphatic-venous anastomoses (LVA) for primary prevention of lymphedema during groin dissection for trunk melanoma treatment (T-group). Blue-stained lymphatic vessels are removed from the inguinal node (upper left) and anastomosed into a branch of the saphenous vein (lower right).

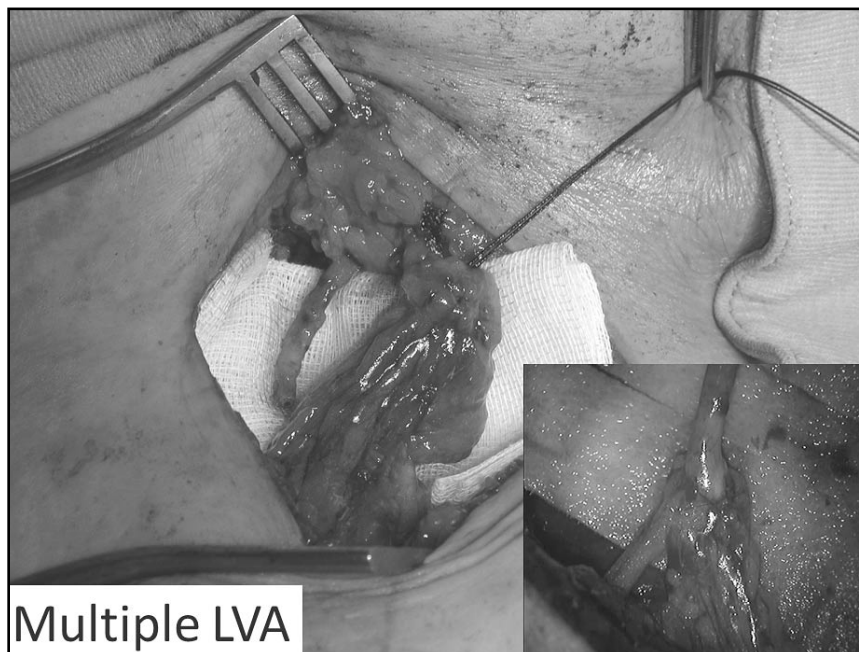


Fig. 2. Operative photographs demonstrating multiple LVA for lower limb lymphedema following melanoma treatment (E-group). Multiple blue-stained lymphatics (in tissue pedicle over gauze) are anastomosed to a vein (lower right insert).

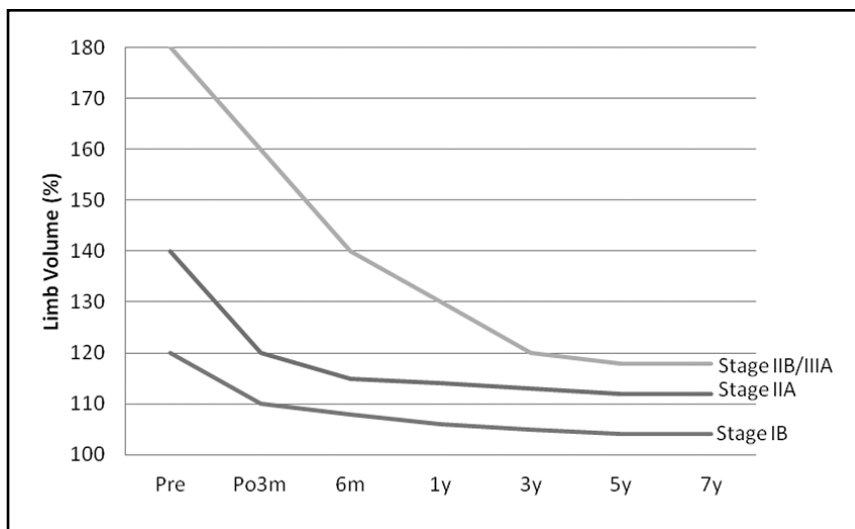


Fig. 3. Long-term microsurgical treatment outcome of lymphedema resulting from melanoma treatment with groin lymphadenopathy. Patients in all three stages demonstrate progressive reduction in limb volume percent increase over 7 years with patients diagnosed in earlier stages both having less lymphedema at start and less at follow up.

accurate oncological and lymphological assessment (18 with stage IIB/IIIA lymphedema; 12 with stage IIA; and 11 with stage IB) and then were treated with multiple LVA for clinical secondary lymphedema (Fig. 2). Microsurgical operation consisted of end-to-end shirt sleeve- shape anastomosis where blue lymphatics were directly inserted together into the vein using a U-shape stitch (8-0 Nylon). The lymphatics were then stabilized inside the vein with additional stitches between the vein border and the peri-lymphatic adipose tissue. At the end of anastomosis, the U-shape stitch was removed to avoid any risk of lymphatic closure. The passage of patent blue lymph into the vein allowed verification of patency of LVA during surgery. Clamps were usually not necessary. In most cases, the medial accessory saphenous vein was used and all blue afferent lymphatics were anastomosed to the same vein segment (multiple LVA) and the microsurgical anastomosis took approximately 30 minutes to be performed. No additional treatments (drugs, physical therapy and elastic garments) were provided.

Limb volume measurements, obtained by measuring serial limb circumferences and then calculated using the formula for the volume of a truncated cone, and lymphoscintigraphy were performed pre- and post-operatively to assess short and long term outcomes. Limb measurements were recorded by the same physiotherapist on a specific chart. Lymphedema was diagnosed when the difference between the two limbs was more than 200 ml. Median follow-up time was 42 months (range 6-67).

RESULTS

No lymphedema occurred after microsurgical primary preventive approach (Ly.M.P.H.A.) in the T-group patients. Patients in the E-group had a significant (average 80%) reduction of pre-op excess lymphedema volume after microsurgery. Stage IB lymphedema patients had a 95% reduction, stage IIA 84%, and stage IIB/IIIA 70%. All patients had been previously treated by conservative methods (Fig. 3).

Long term follow-up allowed verification

TABLE 2
Transport Index (T.I.) Assessment
of Patients in the E-group According to
Their Lymphedema Staging

Number of patients	Pre-operative T.I.	Post-operative T.I.
15 (Stage IIB/IIIA)	35 (30-47)	29 (24-37)
9 (Stage IIA)	27 (25-31)	12 (9-16)
11 (Stage IB)	19 (15-26)	7 (3-10)

of patency of microlymphatic-venous anastomoses. Lymphoscintigraphy was performed post-operatively in 35 patients and demonstrated patency of microsurgical anastomoses in all cases. To quantify visual findings in lymphoscintigraphy, the Kleinhans transport index (T.I.) was used (7). In this index, 5 parameters describe the lymph flow: lymphatic transport kinetics (K), distribution pattern (D), time lapse to appearance of lymph nodes (T in minutes, multiplied by 0.04), assessment of lymph nodes (N) and assessment of lymph vessels (V). Each parameter is given a score from 0 to 9, with 0 indicating no abnormalities and 9 indicating the worst condition. The transport index can vary from 0 (no abnormalities) to 45 (most abnormal) and a T.I. < 10 is considered normal. T.I. improved an average of 67% (range 32-85%) after 1 year follow-up in the E-group patients after microsurgery (Table 2). Eleven of the T-group patients had a normal T.I. pre-operatively and 7 already had an impaired T.I. (> 10).

DISCUSSION

Lymphedema is a significant complication of inguinal node dissection performed for metastatic melanoma (8), but its severity can be limited with proper surgical and physical therapy. It is important to measure limb volume pre-operatively to allow better follow up of patients and to diagnose lymphedema at the very earliest stage when there is an

absence of fibrotic changes of tissues and lymphatic vessels.

In patients with melanoma of the trunk, it is possible to perform preventive lymphatic-venous anastomosis (LVA) simultaneously with inguinal lymphadenectomy (T-group). This preventive method proved to significantly reduce lymphedema occurrence compared with the historic rate of lymphedema development following groin dissection for melanoma on the trunk (64% in our group of oncologic surgeons). However, this preventive surgical approach can only be carried out in patients with melanoma localized at the trunk. In cases of melanoma of the extremities, this preventive approach cannot be used for oncological reasons, and lymphedema development can be limited with accurate post-operative management. Immediate post-operative elastic wraps have proved their efficacy when placed from the foot to above the knee with multiple layers, replaced afterwards by compression stockings. Leg elevation is useful as well when the patient is still lying on the bed.

After an accurate oncological assessment and the absence of any sign of recurrence of the malignancy, lymphedema can be treated by lymphatic microsurgery in order to bypass the obstacle to lymph flow by derivative multiple LVA at the groin (E-group) (9). In these patients, lymphoscintigraphy represents the gold standard to assess lymphatic transport capacity preoperatively and afterwards to evaluate long-term results (10) (Fig. 4). Venous ultrasonography was also performed in all patients to study vein circulation.

A correctly performed completion lymphadenectomy with careful attention to surgical details can help to minimize wound complications, decrease the time of closed-suction drains and decrease venous thromboembolism. Although we do not have the means to test for it yet, there is always a concern for congenital predisposition for lymphedema (genes, growth factors, derivative lymphatic pathways, etc.) even though these cases appear to be primarily

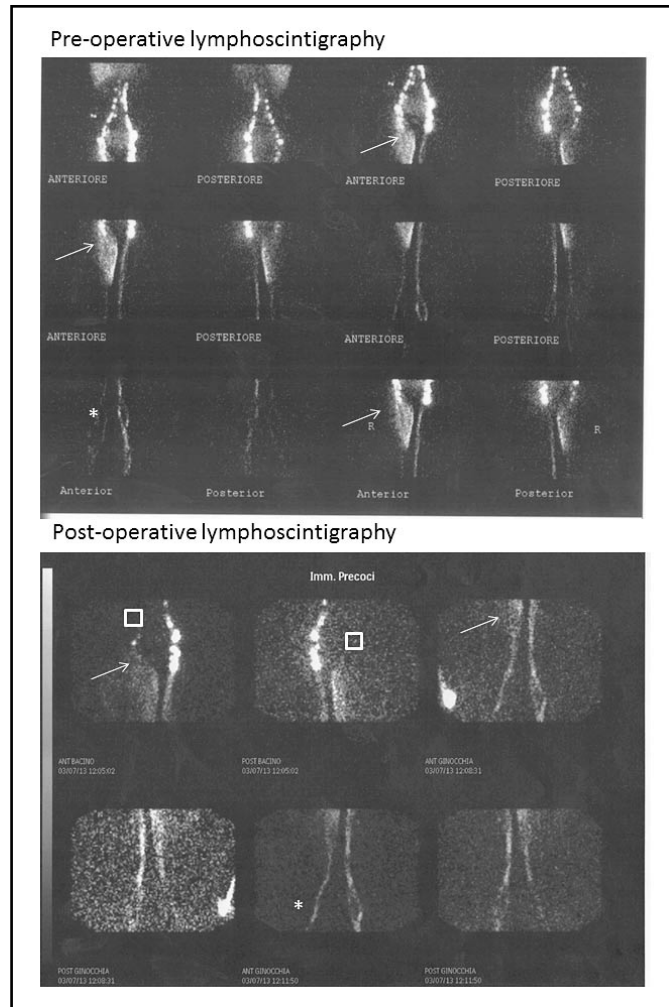


Fig. 4. Lymphoscintigraphic pre(top) and post(bottom) operative assessment of LVA at the right groin. Arrows indicate dermal backflow (DB) below the groin on the patient's right side before and the reduction after microsurgery. Stars show the pre and post improvement of lymphatic flow in the right lower limb. Squares show the approximate site of LVA and the corresponding disappearance of the tracer where the lymphatics connect into the blood stream.

secondary lymphedema in terms of anatomic-functional predisposition. Anatomic and functional risks may be assessed preoperatively with lymphoscintigraphy and could be addressed with additional preventive measures.

Although this retrospective study is relatively small, the number of patients for this specific population is substantial. Patients with melanoma of the trunk may not

always be similar to each other or to those with melanoma of a limb. Replicative prospective studies in other institutions are needed to ensure the validity and transportability of these techniques. With these caveats, we believe that microsurgery is a valid technique for the prevention and treatment of lymphedema complications due to groin lymphadenectomy in the setting of melanoma.

REFERENCES

1. Sarnaik, AA, CA Puleo, JS Zager, et al: Limiting the morbidity of inguinal lymphadenectomy for metastatic melanoma. *Cancer Control* 16 (2009), 240-247.
2. Faries, MB, JF Thompson, A Cochran, et al: The impact of morbidity and length of stay of early versus delayed complete lymphadenectomy in melanoma: Results of the multicenter selective lymphadenectomy trial. *Ann. Surg. Oncol.* 17 (2010), 3324-3329.
3. Shada, AL, CJ Slingsluff, Jr: Regional control and morbidity after superficial groin dissection in melanoma. *Ann. Surg. Oncol.* 18 (2011), 1453-1459.
4. Spillane, AJ, M Tucker, S Pasquali: A pilot study reporting outcomes for melanoma patients of a minimal access ilio-inguinal dissection technique based on two incisions. *Ann. Surg. Oncol.* 18 (2011), 970-976.
5. Chang, SB, RL Askew, Y Xing, et al: Prospective assessment of postoperative complications and associated cost following inguinal lymph node dissection (ILND) in melanoma patients. *Ann. Surg. Oncol.*, 17 (2010), 2764-2772.
6. Kleinhans, E, RG Baumeister, D Hahn, et al: Evaluation of transport kinetics in lymphoscintigraphy: Follow up study in patients with transplanted lymphatic vessels. *Eur. J. Nucl. Med.* 10 (1985), 349-352.
7. Cambria, RA, P Gloviczki, JM Naessens, et al: Non invasive evaluation of the lymphatic system with lymphoscintigraphy: A prospective, semiquantitative analysis in 386 extremities. *J. Vasc. Surg.* 18 (1993), 773-782.
8. Cormier, JN, RL Askew, KS Mungovan, et al: Lymphedema beyond breast cancer: A systematic review and meta-analysis of cancer-related secondary lymphedema. *Cancer* 116 (2010), 5138-5149.
9. Boccardo, FM, F Casabona, D Friedman, et al: Surgical prevention of arm lymphedema after breast cancer treatment. *Ann. Surg. Oncol.* 18 (2011), 2500-2505.
10. Campisi, C, C Bellini, C Campisi, et al: Microsurgery for lymphedema: Clinical research and long-term results. *Microsurgery* 30 (2010), 256-260.

Francesco Boccardo, MD, PhD
Department of Surgery -
Unit of Lymphatic Surgery
IRCCS S. Martino Hospital-
Cancer Institute (IST)
University of Genoa, Italy
E-mail: francesco.boccardo@unige.it