

HYALURONIDASE TREATMENT OF ACUTE LYMPHEDEMA IN A MOUSE TAIL MODEL

H.J. Jeong, K.H. Roh, G.C. Kim, Y.O. Kim, J.H. Lee, M.J. Lee, Y.-J. Sim

Department of Physical Medicine and Rehabilitation (HJJ,KHR,GCK,JHL,MJL,YJS), Department of Pathology(YOK), Kosin University Gospel Hospital, Kosin University College of Medicine, Busan, Korea

ABSTRACT

The purpose of this study was to investigate the impact of hyaluronidase (HAase) on lymphedema using an acute mouse tail lymphedema model. Six-week old mice served to produce acute lymphedema and were then either treated with HAase injection or used as operative controls. An additional group of unmanipulated normal mice was used for comparison. Tail volumes were measured for 23 days and histological changes examined. Western blot analysis was conducted to quantify lymphatic vessel endothelial hyaluronan receptor (LYVE)-1, tumor necrosis factor (TNF)- α , transforming growth factor (TGF)- β 1, podoplanin, CD 44, and vascular endothelial growth factor receptor3 (VEGFR3) expression levels. The operative control group showed an increase in thickness of the dermis and subdermis, microlymphatic dilatation, and an increase in neutrophils. In contrast, the HAase treated group exhibited alleviation of inflammation evidenced by a decline in microlymphatic dilatation and neutrophils and an overall increase in microlymphatic vessels. Western blot analysis demonstrated that TNF- α and TGF- β 1 expression declined but CD44 expression increased in the HAase treated group. Levels of LYVE1, podoplanin, and VEGFR3 also increased significantly in the HAase group. Our results indicate that HAase treatment in the acute mouse tail

model reduced lymphedema volume possibly through degradation of HA trafficking, which reduced inflammation and fibrosis in tissues and stimulated lymphangiogenesis.

Keywords: lymphedema, inflammation, lymphangiogenesis, fibrosis, hyaluronidase, mouse tail

The lymphatic system consists of a key network of vessels which maintains tissue fluid homeostasis and prompt regional inflammatory and immune responses (1). When the anatomical and functional integrity of lymphatic vessels is impaired, disruption in fluid transport causes abnormal fluid accumulation in skin and subcutaneous tissues termed lymphedema (2). Lymphedema can be classified into primary and secondary lymphedema forms with secondary lymphedema attributable to various factors such as infection, malignant tumor, surgery, radiation therapy, chronic venous insufficiency, and trauma (1).

Despite continuing developments in conservative and surgical treatment approaches, secondary lymphedema treatment options have been limited (2). Some investigations have found that growth factors can induce lymphangiogenesis to treat secondary lymphedema, but clinical application remains limited (1). Although secondary lymphedema has been defined

as a high protein edema, Liu and colleagues (3) found in some lymphedema patients that protein concentration levels were lower in the lymphedema tissues than normal tissues and that the level of hyaluronic acid (HA) was clearly higher in the lymphedema tissues compared to normal. Moreover, in lymphedema, macromolecules such as HA build up in the interstitium hampering cell trafficking and triggering cytokine release. These events result in the trophic changes associated with chronic lymphedema. Therefore, lymphedema, which is viewed as a high protein edema, actually shows stronger correlation to HA than to protein level. In addition, HA is partly metabolized in lymph nodes before entering the general circulation and rapidly degrading in the liver. Therefore, the lymph circulation is the main transport pathway for HA from tissue, and an impaired lymph circulation promotes interstitial fluid stagnation and changes the metabolism of HA (4). In the tissues, HA accelerates extravasation of lymphocytes and macrophages from the blood circulation and promotes their migration to sites of inflammation. Impaired trafficking of HA can initiate inflammation in edematous tissues and affect collagen metabolism there causing fibrosis, which is a key pathologic feature of chronic lymphedema (5).

Recently, studies in secondary lymphedema examining structural and functional tissue changes found higher gene expression of proinflammatory cytokines in untreated patients compared to those treated with complex decongestive physiotherapy (6). Tabibiazar et al (7) observed in an experimental acute lymphedema model that the dermis and subdermis exhibited intense acute inflammatory changes and used transcriptional profiling to demonstrate upregulation of genes related to acute inflammation, immune response, complement activation, wound healing, fibrosis, and oxidative stress response. Accordingly, inflammation was postulated to be central to the pathogenesis of lymphedema, creating fibrosis in the

transition phase from acute to chronic lymphedema or triggering trophic changes in tissues, and further, that inflammation should be a very important factor evaluated in future studies of various lymphedema treatments.

Hyaluronidase (HAase) is one of four glycosaminoglycans that build the dermal extracellular matrix and a class of enzymes which degrade HA. Luagier et al (8) found in both in vivo and in vitro studies that topical HAase significantly reduces HA in the epidermis and subdermis layers. Their findings suggest that HAase might be helpful in alleviating HA stagnation in the dermis and subdermis of secondary lymphedema. Therefore, the use of HAase in lymphedema patients would be expected to promote cell trafficking and a reduction in lymphedema volume. However, few studies have been conducted on the effect of HAase on secondary lymphedema and there have been no studies that we are aware of focusing on tissue changes resulting from HAase treatment.

Therefore, in a mouse tail model of acute secondary lymphedema, we investigated whether HAase injection can: 1) reduce lymphedema volume; 2) alleviate inflammation and fibrosis in the dermis and subdermis; and further 3) serve as a lymphangiogenesis factor.

METHODS

Materials and Study Plan

Six-week-old ICR female mice weighing 25-30 grams were housed and maintained on a 12-hour day-night cycle at 23°C ambient temperature and supplied with water and feed *ad libitum*. Mice were placed into one of the three groups: HAase treatment group, untreated operative control group, and a normal unmanipulated group. Tail volumes were obtained for all three groups and tissues were examined at multiple time points to examine histological changes. Animal studies conformed to the Guide for the Care and Use of Laboratory Animals published by the US

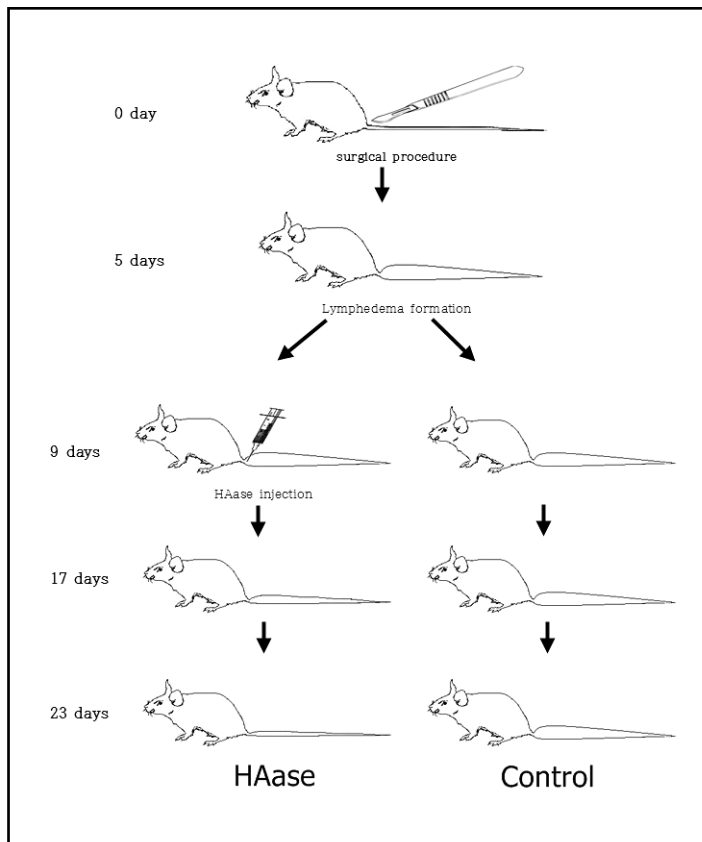


Fig. 1. Operative procedures were performed on tails of mice to produce acute lymphedema. On postoperative day 9, mice were divided into either a HAase treatment group with two injections of HAase into the tail distal to the operative site or to the control untreated group. Mice were then followed for 14 days until postoperative day 23.

National Institutes of Health (NIH Publication No. 85-23, revised 1996), and the study was approved by the Animal Experimentation Ethics Committee of Kosin University.

The unmanipulated normal mice were observed for 23 days without any clinical interventions. To create the mouse model of acute lymphedema, operative procedures (see below) were performed on mice in both HAase and untreated control groups, and lymphedema was allowed to develop for nine days. On postoperative day 9, the HAase group was given HAase injections in the tail. Histological changes for 14 days (to 23 days post-op) were observed in both HAase and control groups (*Fig. 1*).

METHODS

Acute Lymphedema Model

To create a mouse tail model of acute secondary lymphedema, ICR female mice (25-30 grams) were anesthetized by intraperitoneal injection of tiletamine/zolazepam (Zoletil® 50; Virbac, France, 30mg/kg) and xylazine hydrochloride (Rompun®; Bayer, Germany, 10mg/kg). Dermis and subcutaneous tissues (5-10 mm) near the base of the tail were removed without injuring the blood vessels on both side of the tail, and antibiotic cream was applied to prevent infection. Lymphedema volume in the tails was

previously reported to be most pronounced on postoperative day 9 and persisted for 23 days after operation (9).

Hyaluronidase administration

150 IU/0.1ml of HAase (BMHYLUNIDASE INJ®; BMI KOREA, Korea) was injected with a 26 gauge needle on both dorsal and ventral sides approximately 15mm distal from tail base (distal to the operative area) and observations were made for 14 days thereafter.

Measurements of Volume in Mouse Tail Lymphedema

For each group, the diameter of mouse tails was measured with an electronic caliper for 23 days after the surgery at intervals of 10mm up to 70mm distal from tail base. Diameters were converted to circumferences and a standard truncated cone formula was used to determine volume (10).

Lymphoscintigraphy

To examine function of lymphatic vessels, two mice were randomly selected from both HAase and operative control groups on postoperative days 0, 9, and 23 and imaged with lymphoscintigraphy. Under anesthesia, 99mTc-phytate (100 uCi/0.02 ml) was intradermally injected 70mm distal from the base of the tail. Images were obtained at 10, 30 and 60 minutes after injection using a microSPECT INFINIA gamma camera (GE medical system, USA) equipped with a LEGP (low energy general purpose) collimator.

Histology

To examine histological changes, three mice from the HAase and control groups were euthanized by carbon dioxide asphyxiation on postoperative day 9, 16 or 23, and tails were removed for immediate fixation in formalin. In addition, 3 mice from the

unmanipulated normal group were euthanized and their tails collected as above. One mm-thick cross-sectional pieces of tissue were obtained from the area located 15mm from the base of the tail for tissue examination. All tissues were embedded in paraffin, sectioned, and stained with hematoxylin and eosin for evaluation of histological changes.

Immunohistochemistry

To identify lymphatic vessels, 5µm paraffin sections were cut and mounted on organosilane-coated glass slides for immunohistochemical (IHC) staining. After deparaffinizing and rehydrating, antigen retrieval was performed in citrate buffer for 10 minutes at 121°C. Sections were blocked and incubated overnight at 4°C with LYVE-1 (Abcam, Cambridge, UK) followed by secondary horseradish peroxidase-conjugated antibody (DAKO, Glostrup, Denmark) for one hour at RT. Slides were then developed with DAB (DAKO) and counter-stained with Mayer's hematoxylin (DAKO) and images captured with a Nikon ECLIPSE 50i microscope (Nikon, Tokyo, Japan).

Immunofluorescence

To confirm the presence of lymphatic vessels through immunofluorescence analysis, LYVE-1 (Abcam), Podoplanin (Santa Cruz, CA, USA), and PROX-1 (Millipore, CA, USA) were used as primary antibodies with Alexa Fluor 488 goat anti-rabbit or Alexa Fluor 594 donkey anti-mouse (Invitrogen, CA, USA) secondary antibodies. Images were captured with a laser scanning microscope (LSM510 META, Carl Zeiss, Jena, Germany).

Western Blot analysis

To measure changes in levels of CD44, tumor necrosis factor- α (TNF- α), transforming growth factor- β 1 (TGF β 1), LYVE-1, podoplanin, and vascular endothelial growth factor receptor 3 (VEGFR3) expression, at

least 10 mice from each group were euthanatized with carbon monoxide on postoperative day 0, 9, 16, or 23 and tails were removed for immediate formalin fixation. RIPA buffer (20 mM Tris-HCl (pH 7.5), 150 mM NaCl, 1 mM Na₂EDTA, 1 mM EGTA, 1% NP-40, 1% sodium deoxycholate, 2.5 mM sodium pyrophosphate, 1 mM β-glycerophosphate, 1 mM Na₃VO₄, 1 μg/ml leupeptin, 1 mM PMSF) was used to separate proteins in tail tissues. BCA protein assay kit (Pierce, Rockford, IL, USA) was used to perform protein quantification, and sodium dodecyl sulfate-polyacrylamide gel electrophoresis (SDS-PAGE) was employed to separate proteins by electrophoresis. After the protein transfer from SDS-PAGE gels to PVDF membrane (Roche Diagnostics GmbH, Mannheim, Germany), the membrane was blocked (1X TBS, 0.1% Tween-20 with 5% w/v nonfat dry milk) for one hour at room temperature to prevent non-specific antibody interactions. Primary antibody was incubated overnight at 4°C and then rinsed three times with TBS-Tween-20 solution. The blots were incubated in a peroxidase-conjugated secondary antibody for 1 hour at room temperature and then rinsed three times with TBS-Tween-20 before their exposure to X-ray film (FUJI FILM Co. Tokyo, Japan) equipped with ECL kit (Amersham Pharmacia Biotech, Piscataway, NJ, USA) to confirm the protein expression. Primary antibodies LYVE1 and TNF-α were purchased from Abcam (Abcam, Cambridge, UK) and TGF-β1, podoplanin, CD 44, VEGFR3, actin and secondary antibodies were obtained from Santa Cruz Biotechnology (Santa Cruz, CA, USA).

Statistical Analysis

SPSS for windows (version 14.0) was used to conduct statistical analysis for changes in diameter and volume of mouse tails and to calculate average and standard deviation of the three groups. One-way ANOVA was used to compare volume changes between the three groups. To

measure fibrosis, inflammation, and lymphatic vessels, the levels of TGF-β1, TNF-α, CD44, LYVE-1, podoplanin, VEGFR3 in the HAase group were monitored over time with one-way ANOVA. Student's t-test was used to compare the HAase and control groups. A p-value of 0.05 was used as a cutoff for all statistical significance.

RESULTS

Lymphedema Is Reduced by Hyaluronidase

Tail diameter and volumes were measured to 70mm distal from tail base in the HAase (N=8), control (N=8), and normal mice groups (N=8). The HAase and control groups exhibited significant increase in volume starting from postoperative day 5 compared to the normal group (p<0.05). In particular, HAase and control groups displayed nearly twice the volume compared with the normal group at postoperative day 9. Thereafter, tail volumes declined in the HAase treated group (a 47% decrease from the maximum volume of 1.115±0.089 cm³ to 0.702±0.080 cm³; p<0.05) but remained unchanged in the control group (Fig. 2A). Comparison between the HAase and control groups on post-operation days 16 and 23 demonstrated that tail volumes in the HAase group significantly declined compared to the control group. At day 23, tail volume in the control group was unchanged while tail volume in the HAase treated group had returned to near normal levels (Fig. 2). In addition, the thickness of dermis and subdermis clearly reduced in the HAase group on postoperative days 16 and 23 compared to the control group and returned to near normal on postoperative day 23 (Fig. 2).

Hyaluronidase Therapy Can Improve Histological Changes in Secondary Lymphedema

Qualitative and histomorphometric analysis of paraffin-embedded, hematoxylin/

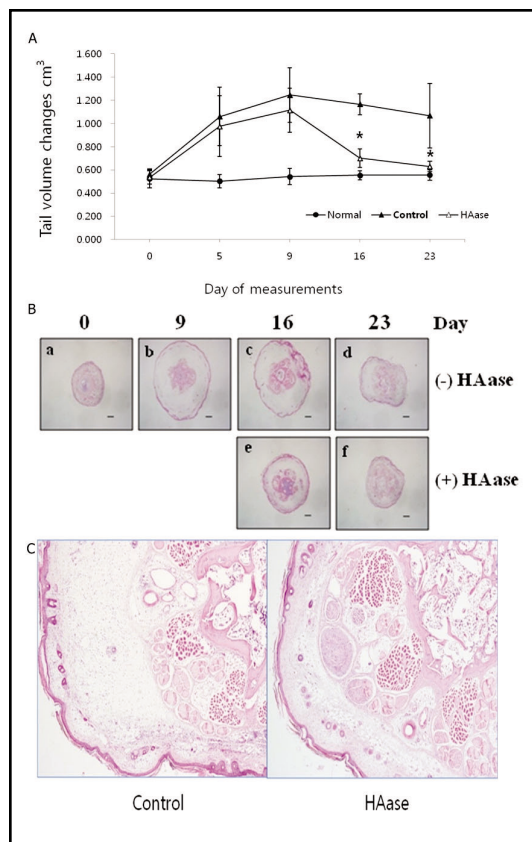


Fig. 2. Tail volume changes following acute lymphedema operation. HAase and control groups displayed nearly twice the volume increase compared with unmanipulated normal group at postoperation day 9. Tail volume of the HAase treated group gradually decreased to near the normal group, but volume of the control group was maintained (A). The HAase treated group displayed a decrease in interstitial fluid volume compared with control group at days 16 and 23 (H & E stain) (scale bar = 1mm) (B) and a decrease in the number of inflammatory cells at day 23 (H & E stain) (C).

eosin-stained dermis and subdermis sections obtained on postoperative day 9, 16 or 23 revealed acute inflammatory changes. The operative control group exhibited a 2- fold expansion of tissue between the bone and the epidermis, and dermis and subdermis showed a high degree of neutrophil infiltration (Fig. 2). These changes remained until day 23. Fibroblasts, a possible cause of fibrosis,

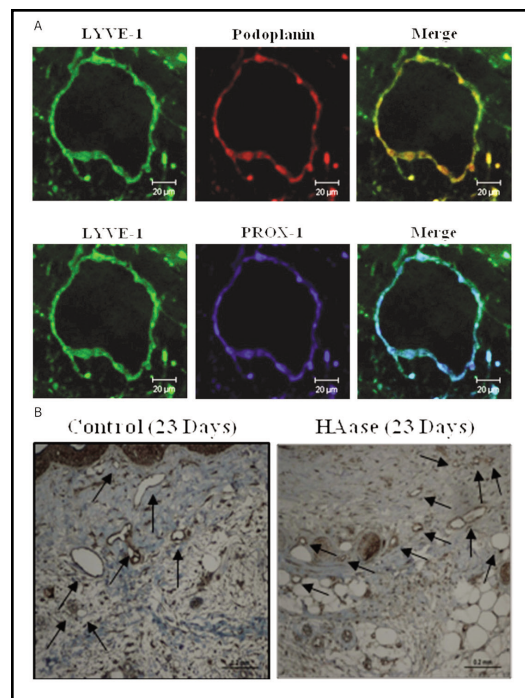


Fig. 3. Immunofluorescence images using LYVE-1, Podoplanin, and PROX-1 demonstrate cross-sectional morphology of lymphatic vessels (scale bar = 20um) (A). An increase in size and dilation of the lymphatic vessels was seen by LYVE-1 immunohistochemistry in the control (arrows), and the dilation was reduced in the HAase treated group at day 23 (B).

were observed in the subdermis. HAase injection treatment led to a decrease in inflammation (reduction in neutrophils) on postoperative day 16 and near normal histological appearance (thickness of dermis and subdermis) at postoperative day 23 (Fig. 2C).

The histological similarity between blood vessels and lymphatic vessels made it difficult to differentiate them. To clearly identify lymphatic vessels, double staining was conducted with combinations of either anti-LYVE-1 and anti-prox1 antibodies or anti-LYVE-1 and anti-podoplanin antibodies. Immunofluorescence images showed lymphatic endothelial vessels were double-stained with anti-LYVE-1 and anti-podoplanin

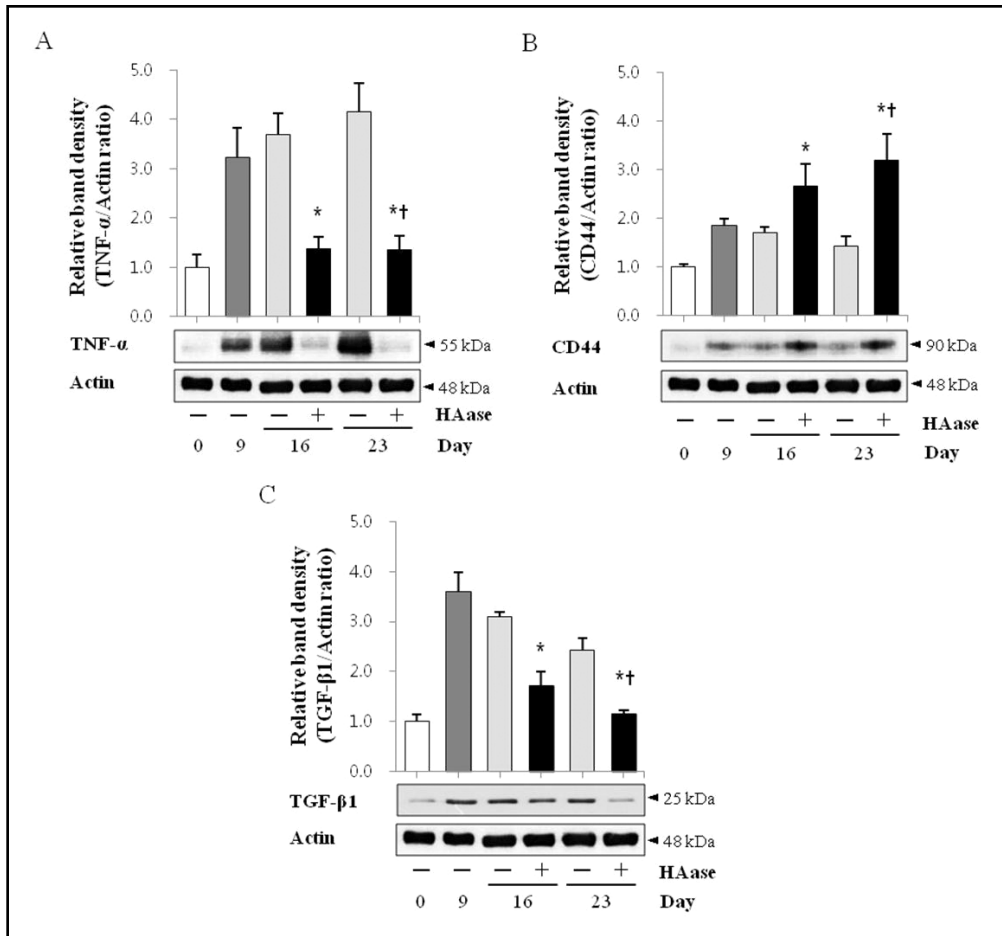


Fig. 4. The HAase treated group showed a significant reduction in TNF- α (A) and TGF- β 1 (C) and a significant increase in CD44(B) expression over time while the control group remained stable. The HAase treated group also demonstrated a significant decline in TNF- α (A) and TGF- β 1 (C) and a significant increase in CD44(B) expression on postoperative days 16 and 23 compared to the untreated control group. (* $p < 0.05$ compared with control, † $p < 0.05$ change over time).

antibodies and anti-LYVE-1 and anti-prox1 antibodies at postoperative day 23. Lymphatic vessels were marked by irregular round shapes (Fig. 3A).

Immunohistochemistry was performed to identify lymphatic vessel changes resulting from HAase injection. At day 9, lymphatic vessels exhibited dilatation and more irregular shapes. HAase injections clearly increased the number of lymphatic vessels and reduced the dilatation in lymphatic vessels of the HAase group at 23 days (Fig. 3B).

Hyaluronidase Therapy Reduces Inflammation and Fibrosis

Western blot analysis confirmed expression of tumor necrosis factor- α (TNF- α), a prominent inflammatory mediator in lymphedema. TNF- α expression increased on postoperative day 9 compared to day 0 ($p < 0.05$). Thereafter, the operative control group did not exhibit significant changes in TNF- α expression while the HAase group showed a significant reduction ($p < 0.05$) in

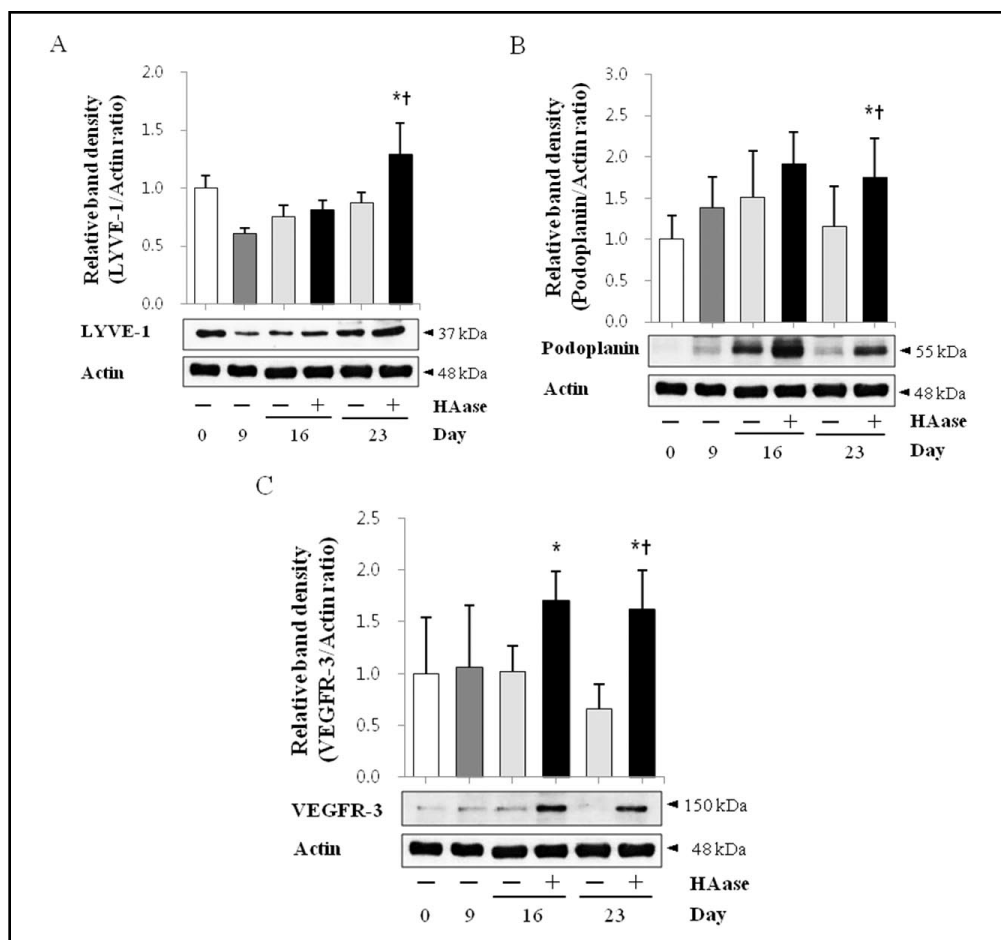


Fig. 5. The HAase treated group shows a significant increase in LYVE-1 (A), podoplanin (B), VEGFR3 (C) expression over time while the untreated control group remained stable. The HAase treated group also experienced a significant increase in LYVE-1(A), podoplanin (B), VEGFR3 (C) expression on postoperative day 23 compared to the untreated control group. (* $p < 0.05$ compared with control, † $p < 0.05$ change over time).

expression on postoperative days 16 and 23 from both day 9 and compared to the controls at each day ($p < 0.05$) (Fig. 4A). In addition, expression of CD44 (a HA receptor) was increased after day 9 and continued to rise after HAase injection at days 16 and 23 ($p < 0.05$). This increase was also significantly different from the untreated controls at days 16 and 23 ($p < 0.05$) (Fig. 4B).

Expression of TGF- β 1, a negative regulator of lymphatic regeneration, was quantified to examine the level of fibrosis.

TGF- β 1 expression was significantly increased ($p < 0.05$) on postoperative day 9 compared to day 0. Thereafter, both control and HAase groups declined in TGF- β 1 expression over time with statistically significant declines in the HAase group as well as a significant difference between the groups at days 16 and 23 ($p < 0.05$) (Fig. 4C).

Hyaluronidase Therapy Promoted Lymphangiogenesis

Western blot analysis to quantify lymphatic regeneration found that compared to day 0: LYVE-1 expression increased on postoperative days 16 and 23 after HAase injection (significantly at day 23); podoplanin expression reached a peak on postoperative day 16 (also significant at day 23, $p < 0.05$); and levels of VEGFR3 expression significantly increased on postoperative day 16 and 23 ($p < 0.05$). In comparison to the untreated controls, LYVE-1 and podoplanin expressions were higher in the HAase group at days 16 and 23 (significant at day 23), and VEGFR3 expression was significantly higher at both days 16 and 23 ($p < 0.05$) (Fig. 5).

Hyaluronidase Therapy Improved Lymphatic Function

Lymphoscintigraphy performed on postoperative day 9 showed that the control group had a slower flow of lymph fluid/tracer and a lower level of lymphatic drainage than the normal unmanipulated group with renal nodes starting to appear at 30 minutes after radionuclide injection. The presence of dermal backflow was observed in areas where dermal and sub-dermal tissues were removed and where lymphedema was found in the mouse tails (Fig. 6A). Lymphoscintigraphy tests of the untreated control group conducted on postoperative day 23 showed that radionuclide uptake did not increase at lymph nodes 1 hour after radionuclide injection, indicating that the lymph flow rate of the control group had deteriorated further. In contrast, the lymph flow of the HAase group had improved and was restored close to the normal unmanipulated group on postoperative 23 day (Fig. 6B).

DISCUSSION

The acute mouse tail model of lymphatic circulatory failure causes lymph stasis in the interstitium. It is thought that blood flow may increase as a compensatory response that reduces fluid overload in the tissues,

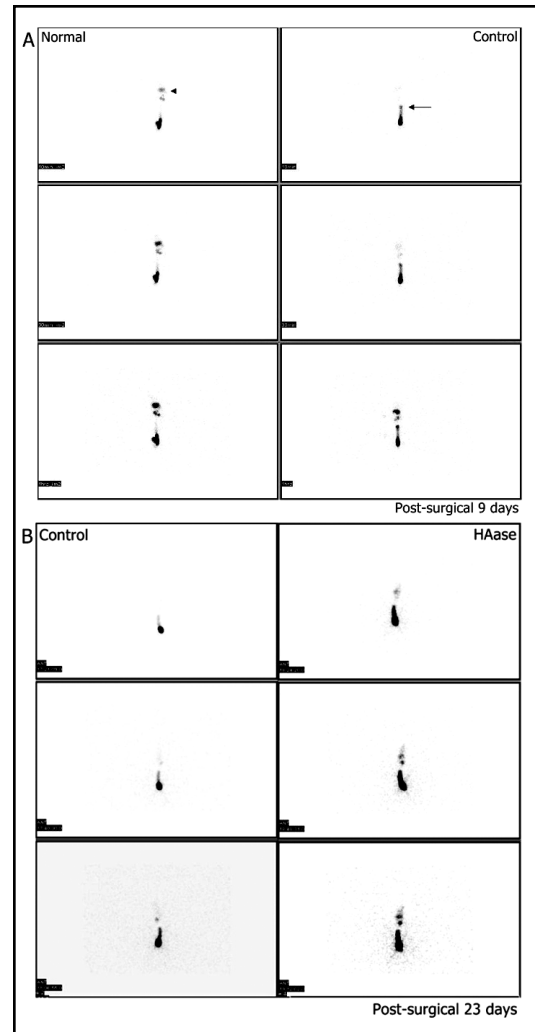


Fig. 6. Lymphoscintigraphy was performed using an intradermal injection of 100 uCi/0.02 ml of filtered ^{99m}Tc phytate. Dynamic and static images were acquired using a low energy general purpose collimator in a microSPECT INFINIA gamma camera. At day 9, renal nodes (arrow head) were visualized early in the unmanipulated normal group while in the untreated control group renal nodes were visualized 30 minutes after injection and dermal back flow (arrow) was observed (A). Lymphatic flow in HAase treated group at day 23 demonstrated improved flow and nodal imaging compared to the untreated control (B).

but this would not significantly improve the transport of excess water from the interstitium. As lymphedema continues, the exact causes

of water retention remain uncertain (11). Possible factors include protein accumulation within tissues or impaired lymph flow. In other words, lymphedema is known to be a high protein edema in which protein accumulation in the interstitium and increased oncotic pressure stimulates more edema. However, recent studies found that in the absence of inflammatory conditions the level of protein in lymphedema-affected areas did not increase compared to that of healthy counterparts but instead showed a higher HA concentration demonstrating the importance of HA in the development and pathogenesis of lymphedema (11). As a large polymer of N-acetyl-D-glucosamine and D-glucuronic acid, HA maintains tissue integrity and facilitates cell migration during inflammation, wound repair, and embryonic development periods (11).

The development of lymphedema involves a more complicated pathogenesis than simple defects in lymph vessel function. Among the most widely discussed pathologic events include inflammatory changes and fibrosis-caused chronic inflammation as oligosaccharide breakdown products of HA have inflammatory properties (macrophages release chemokines and cytokines) (12,13). Lymphatic vessels also serve as channels for inflammatory cell migration as well as HA, and this process may be facilitated by adhesion between CD44 receptor of inflammatory cells and the LYVE-1 receptor on lymphatic endothelial cells mediated by HA (5). As such, HA trafficking caused by defective lymphatic vessels has little to do with blood circulation but its accumulation is solely driven by lymphedema fluid, which may lead to prolonged inflammation and increased tissue fibrosis and cause trophic changes in the tissues (3).

HAase is an enzyme that causes natural degradation of HA (14). Clinically, HAase is known to facilitate the absorption and dispersion of drugs, and the FDA has approved its use for 1) retrobulbar anesthetic block in eye surgery and 2) hypodermoclysis (15).

We aimed to test whether HAase can reduce inflammation, one of the primary pathogenic features of lymphedema, and also examine therapeutic potential of HAase treatment to lymphedema tissues. If HAase causes HA degradation and thus HA trafficking decreases in tissues, interactions between HA-mediated receptor CD44 and LYVE-1 should change, reducing inflammation and promoting lymphangiogenesis.

This study found that HAase treatment in the mouse tail model led to a visible decline in the swelling of lymphedema and a return to near-normal conditions two weeks after the treatment. In addition, lymphoscintigraphy showed that lymphatic function improved after the HAase injection. We believe the explanation for the reduction of lymphedema and improvement of lymphatic function following HAase treatment is: (a) a decline in HA trafficking and suppressed interaction with CD44 and reduced acute inflammation, (b) a reduction of TGF- β 1, a key inhibitor of lymphatic regeneration leading to a decline in fibrosis; and (c) an increase in lymphangiogenesis through VEGFR3. This hypothesis is supported by H&E staining demonstrating a reduction in the thickness of dermis and subdermis and a clear reduction in inflammatory cells. Further, immunohistochemistry findings show an increase in lymphatic vessels and a reduction in lymphatic dilatation compared to the peak onset of lymphedema.

TNF- α expression is significant in this study. Tabibiazar et al (7) found an increase in inflammatory mediators such as TNF- α in whole tissue homogenates from mice with lymphedema, and Nakamura et al found that anti-inflammatory Ketoprofen is an effective treatment to reduce lymphedema (1). But Nakamura et al argued that direct TNF- α inhibition did not lead to lymphedema reduction, and inflammation reduction combined with TNF- α activity preservation reduced lymphedema through VEGF-C signaling (1). This study found that TNF- α expression fell in the HAase treated group

compared to the control on postoperative days 16 and 23 indicating that HAase injection alleviated inflammation and contradicting existing data that TNF- α preservation played a key role in reducing lymphedema. Further studies are therefore needed to determine the role of TNF- α in reducing inflammation and lymphangiogenesis.

The HAase treated group exhibited a visible decline in TGF- β 1 expression compared to the control group, and this finding is supported by prior research demonstrating that inhibition of TGF- β 1 expression stimulated lymphatic regeneration, and increased TGF- β 1 expression reduced LEC proliferation and function and stimulated fibrosis (16). This finding indicates that HAase may reduce fibrosis in lymphedema and improve LEC proliferation and lymphatic function.

Studies on the molecular treatment of lymphedema have concentrated on the promotion of lymphangiogenesis. In particular, many investigators believe in the use of recombinant growth factors in redeveloping lymphatic vessels as a new approach to lymphedema treatment. Vascular endothelial growth factor C (VEGFC) and vascular endothelial growth factor receptor 3 (VEGFR3) are key factors in lymphangiogenesis. VEGF gene therapy and exogenous VEGFC administration have been reported to resolve experimental lymphedema by stimulating lymphangiogenesis (17-19). Our study found that VEGFR3 increased in the HAase treated group, suggesting a correlation between HAase treatment and VEGFR3 in lymphedema. After HAase injection, lymphatic specific markers such as VEGFR3, LYVE-1, and podoplanin also increased in the HAase group supporting that HAase treatment caused lymphangiogenesis and thus improved lymphedema.

This study supported the role of HAase treatment in creating lymphangiogenesis and reducing inflammation, and there are three plausible mechanisms: (a) HAase reduced inflammation and stimulated lymphangio-

genesis; (b) the reduction of inflammation stimulated the activity of VEGF-C/VEGFR3 and thus caused lymphangiogenesis; and (c) HAase increased VEGFR3 directly and VEGFR3 reduced inflammation. Although prior studies found that VEGF-C has an anti-inflammatory effect through VEGFR3, and the activation of VEGFR3 has a potent anti-inflammatory effect in a psoriasis murine model (20,21), CD44 also increased in the HAase group. This effect is possibly attributable to a negative feedback loop due to HA reduction. Given other prior research findings that an increase in CD44 plays a critical role in reducing lung inflammation (22), we cannot rule out the possibility that an increase in CD44 directly reduced inflammation in our model.

Recent investigations of lymphedema treatments have also focused on therapeutic lymphangiogenesis with various growth factors, and stem cells are used as treatment methods (23, 24). However, considering that the efficacy of stem cells is maximized when combined with growth factors (23,24) and the use of growth factors is subject to clinical considerations concerning promotion of tumor metastasis (25), clinically applicable treatments are not in place. So far, only a few studies have been conducted on modulation of drug-induced lymphangiogenesis, but most have shown inhibition of lymphangiogenesis (26). Therefore, HAase treatment could play an important role in increasing lymphangiogenesis and reducing inflammation and fibrosis. In addition, future studies are also needed to clarify the relationship(s) between inflammation and lymphangiogenesis.

In mammals, HA exists in high-, intermediate-, and low-molecular weight forms. HA can be depolymerized into small oligosaccharides via oxygen radicals and enzymatic degradation by hyaluronidases, beta-glucuronidases, chondroitinases, and hexosaminidases (27). The various molecular weight forms of HA have vastly different effects on inflammation, with high molecular weight HA appearing to attenuate the

inflammatory response (28). In this study, we investigated the impact of HAase on lymphedema using an acute mouse tail lymphedema model. However, we did not examine whether HAase itself has a direct effect or indirectly through HA fragments produced by degradation. This issue should be clarified in future studies.

In summary, these study results in the acute mouse tail model indicate that HAase treatment reduces lymphedema volume, and the underlying mechanism may be a reduction in HA trafficking in lymphedema tissues, which in turn reduces inflammation and fibrosis and stimulates lymphangiogenesis through increased expression of VEGFR3. These promising results regarding HAase treatment should be further explored as a possible treatment strategy for patients with lymphedema.

ACKNOWLEDGMENT

This research was supported by Basic Science Research Program through the National Research Foundation of Korea (NRF) funded by the Ministry of Education, Science and Technology (2011-0008852).

REFERENCES

1. Nakamura, K, R Kavita, YT Wong, et al: Anti-inflammatory pharmacotherapy with ketoprofen ameliorates experimental lymphatic vascular insufficiency in mice. *PLoS ONE* 4 (2009), e8380.
2. Rockson SG: Diagnosis and management of lymphatic vascular disease. *J. Am. Coll. Cardiol.* 52 (2008), 799-806.
3. Liu, NF, LR Zhang: Changes of tissue fluid hyaluronan (hyaluronic acid) in peripheral lymphedema. *Lymphology* 31 (1998), 173-179.
4. Liu, N, L Shao, X Xu, et al: Hyaluronan metabolism in rat tail skin following blockage of the lymphatic circulation. *Lymphology* 35 (2002), 15-22.
5. Liu, NF: Trafficking of hyaluronan in the interstitium and its possible implications. *Lymphology* 37 (2004), 6-14.
6. Földi, E, A Sauerwald, B Hennig: Effect of complex decongestive physiotherapy on gene expression for the inflammatory response in peripheral lymphedema. *Lymphology* 33 (2000), 19-23.
7. Tabibiazar, R, L Cheung, J Han, et al: Inflammatory manifestations of experimental lymphatic insufficiency. *PLoS Med.* 3 (2006), e254.
8. Laugier, JP, S Shuster, M Rosdy, et al: Topical hyaluronidase decreases hyaluronic acid and CD44 in human skin and in reconstituted human epidermis: Evidence that hyaluronidase can permeate the stratum corneum. *Br. J. Dermatol.* 142 (2000), 226-233.
9. Jeong, HJ, KH Hwang, YJ Sim, et al: The study of animal model of lymphedema using the mouse tail. *Kosin Med. J.* 27 (2012), 141-149.
10. Taylor, R, UW Jayasinghe, L Koelmeyer, et al: Reliability and validity of arm volume measurements for assessment of lymphedema. *Phys. Ther.* 86 (2006), 205-214.
11. Liu, N: Metabolism of macromolecules in tissue. *Lymphat. Res. Biol.* 1 (2003), 67-70.
12. McKee, CM, MB Penno, M Cowman, et al: Hyaluronan (HA) fragments induce chemokine gene expression in alveolar macrophages. The role of HA size and CD44. *J. Clin. Invest.* 98 (1996), 2403-2413.
13. Noble, PW: Hyaluronan and its catabolic products in tissue injury and repair. *Matrix Biol.* 21 (2002), 25-29.
14. Lee, A, SE Grummer, D Kriegel, et al: Hyaluronidase. *Dermatol. Surg.* 36 (2010), 1071-1077.
15. Fraser, JR, WG Kimpton, TC Laurent, et al: Uptake and degradation of hyaluronan in lymphatic tissue. *Biochem. J.* 256 (1988), 153-158.
16. Clavin, NW, T Avraham, J Fernandez, et al: TGF-beta1 is a negative regulator of lymphatic regeneration during wound repair. *Am. J. Physiol. Heart Circ. Physiol.* 295 (2008), H2113-2127.
17. Jin da, P, A An, J Liu, et al: Therapeutic responses to exogenous VEGF-C administration in experimental lymphedema: Immunohistochemical and molecular characterization. *Lymphat. Res. Biol.* 7 (2009), 47-57.
18. Yoon, YS, T Murayama, E Gravereaux, et al: VEGF-C gene therapy augments postnatal lymphangiogenesis and ameliorates secondary lymphedema. *J. Clin. Invest.* 111 (2003), 717-725.
19. Szuba, A, M Skobe, MJ Karkkainen, et al: Therapeutic lymphangiogenesis with human recombinant VEGF-C. *FASEB J.* 16 (2002), 1985-1987.

20. Huggenberger, R, S Ullmann, ST Proulx, et al: Stimulation of lymphangiogenesis via VEGFR-3 inhibits chronic skin inflammation. *J. Exp. Med.* 207 (2010), 2255-2269.
21. Huggenberger, R, SS Siddiqui, D Brander, et al: An important role of lymphatic vessel activation in limiting acute inflammation. *Blood* 117 (2011), 4667-4678.
22. Teder, P, RW Vandivier, D Jiang, et al: Resolution of lung inflammation by CD44. *Science* 296 (2002), 155-158.
23. Hwang, JH, IG Kim, JY Lee, et al: Therapeutic lymphangiogenesis using stem cell and VEGF-C hydrogel. *Biomaterials* 32 (2011), 4415-4423.
24. Conrad, C, H Niess, R Huss, et al: Multipotent mesenchymal stem cells acquire a lymphendothelial phenotype and enhance lymphatic regeneration in vivo. *Circulation* 119 (2009), 281-289.
25. Mandriota, SJ, L Jussila, M Jeltsch, et al: Vascular endothelial growth factor-C-mediated lymphangiogenesis promotes tumour metastasis. *EMBO J.* 20 (2001), 672-682.
26. Yiannakopoulou, E: Modulation of Lymphangiogenesis: A new target for aspirin and other nonsteroidal anti-inflammatory agents? A systematic review. *J. Clin. Pharmacol.* 11 (2011), 1749-1754.
27. Campo, GM, A Avenoso, A D'Ascola, et al: Inhibition of hyaluronan synthesis reduced inflammatory response in mouse synovial fibroblasts subjected to collage-induced arthritis. *Arch. Biochem. Biophys.* 518 (2012), 42-52.
28. Caskey, RC, M Allukian, RC Lind, et al: Lentiviral-mediated over-expression of hyaluronan synthase-1 (HAS-1) decreases the cellular inflammatory response and results in regenerative wound repair. *Cell Tissue Res.* 351 (2013), 117-125.

Young Joo Sim, M.D.
Department of Physical Medicine
and Rehabilitation
Kosin University College of Medicine
34, Amnam-Dong, Seo-Gu,
Busan, 602-702, Korea
Phone: 82-51-990-6156
E-mail:oggum@daum.net