

## AXILLARY LYMPH NODES AND ARM LYMPHATIC DRAINAGE PATHWAYS ARE SPARED DURING ROUTINE COMPLETE AXILLARY CLEARANCE IN MAJORITY OF WOMEN UNDERGOING BREAST CANCER SURGERY

A. Szuba, A. Chachaj, M. Koba-Wszedybylb, R. Hawro, R. Jasinski,  
R. Tarkowski, K. Szewczyk, M. Bebenek, J. Forgacz, A. Jodkowska, D. Jedrzejuk,  
D. Janczak, M. Mrozinska, U. Pilch, M. Wozniwski

Departments of Internal Medicine (AS,AC,MK-W,AJ), Oncology and Gynecological Oncology (RT,KS), and Endocrinology (DJ), Wroclaw Medical University; Faculty of Physiotherapy (AS,RH,RJ,MM,UP,MW), University School of Physical Education; and Lower Silesian Oncology Center (RH,MB,JF), Wroclaw, Poland

### ABSTRACT

*Alterations in axillary lymph nodes (ALNs) after complete axillary lymph node dissection (ALND) in comparison to the preoperative status were evaluated using lymphoscintigraphy performed preoperatively and 1-6 weeks after surgery in 30 women with a new diagnosis of unilateral, invasive breast carcinoma. Analysis of lymphoscintigrams revealed that ALNs after surgery were present in 26 of 30 examined women. In comparison to preoperative status, they were visualized in the same location (12 women), in the same and additionally in different locations (9 women), or only in different locations (4 women). No lymph nodes were visualized in one woman and lymphocele were in 4 women. Thus, after ALND, a variable number of axillary lymph nodes remain and were visualized on lymphoscintigraphy in the majority of women. The classical ALND, therefore, does not allow complete dissection and removal of axillary nodes with total disruption of axillary lymphatic pathways, accounting in part for the variable incidence and severity of lymphedema after the procedure.*

**Keywords:** breast cancer, axillary lymph node dissection, lymphoscintigraphy, lymphedema, lymphatic transport, photoplethysmography

Axillary lymph node dissection (ALND) is performed for local cancer control and for staging in breast carcinoma. The number of axillary lymph nodes removed correlates with frequency of ipsilateral axillary recurrence, recurrence-free survival and overall survival (1,2). The absence or presence of cancer cells in axillary lymph nodes defines further oncological treatment and is the most important prognostic factor for patients with breast cancer (3).

ALND is, however, associated with marked morbidity. Breast cancer-related lymphedema (BCRL) remains frequent and distressing postoperative complication in women undergoing axillary clearance. BCRL affects about one-third of all breast cancer survivors and develops usually after a latent period of months or years after breast cancer treatment (4,5). BCRL frequently leads to significant disability, caused by impaired arm mobility, pain, and recurrent infections

(dermatolymphangitis -DLA) (6,7). Surgical dissection of axillary lymph nodes, resulting in disruption of lymphatic vessels draining the arm, is recognized as the major risk factor of BCRL (5). However, the etiology of BCRL is not well understood and likely to be complex and multifactorial (5,8-10). The observation that arm lymphedema does not affect two-thirds of breast cancer survivors despite receiving similar treatment that impacts the anatomy and function of axillary structures is still unexplained. Suggested protective mechanisms include opening anatomical peripheral lymphovenous communications (11,12) and development of collateral lymphatic circulation (13,14). Another mechanism might include the number of lymph nodes that remain after ALND (13).

As we have previously reported, presence of functional axillary lymph nodes visualized by lymphoscintigraphy within the axilla after ALND was associated with no or only mild lymphedema, whereas severe cases of lymphedema demonstrated no axillary lymph nodes (13). The majority of studies of the effects of axillary lymph node clearance surgery, including our prior study, have been conducted on patients after ALND or with established BCRL. Preoperative evaluation of patients before surgery may provide further clues to a better understanding of the pathogenesis of lymphedema.

The purpose of this study was to evaluate alterations in upper extremity lymphoscintigraphic patterns after breast cancer surgery with complete axillary clearance in comparison to the preoperative status.

## *MATERIAL AND METHODS*

### *Patients*

This study was approved by the Local Bioethical Committee of the Wrocław Medical University. All subjects gave informed written consent prior to inclusion in the study and selected demographic and

therapeutic parameters are presented in *Table 1*. Thirty women (mean age 55.97 years; range: 29-80 years) with unilateral breast carcinoma, who underwent breast surgery with complete axillary dissection (ALND) were examined. ALND was performed by experienced team of oncological surgeons. Standard procedure that encompasses removal of levels I, II and III nodal tissue in one bloc was performed in every case, regardless to the clinical lymph node status and the axillary vein was the upper limit of the range of surgery. The posterior wall of the axilla, consisted of subscapularis, latissimus dorsi, and teres major muscles was clearly seen during each ALND and both the long thoracic and thoracodorsal nerves were also preserved. Stripping of the axillary vein was always avoided.

In all the patients, axillary lymph nodes were evaluated using radionuclide lymphoscintigraphy performed preoperatively and 1-6 weeks after surgery.

### *Lymphoscintigraphy*

Injections of 0.25 mCi of  $^{99m}\text{Tc}$ -Nanocoll were done simultaneously in both hands in the second and the third interdigital space. Total injected dose was 1mCi per patient. Static whole body images were acquired 10 minutes and 2 hours after the injection. The procedure was performed preoperatively and repeated 1-6 weeks after surgery.

Axillary lymph nodes status before and after ALND was evaluated in every women qualitatively and quantitatively. Qualitative analysis of the postoperative pattern of axillary lymph nodes in comparison to preoperative status was performed for every patient independently by two physicians. The patients were divided into the following groups: 1- lymph nodes visualized on the operated side in the same location, however weaker than before surgery as compared to the non-operated side; 2- lymph nodes in the same location - not changed or better

**TABLE 1**  
**Patient Demographics and Treatment Characteristics**

Age	
mean/median	55.97 years
range	29-80 years
Type of surgery	
total mastectomy	18 women
breast-conserving surgery	12 women
<i>Breast cancer</i>	
right sided	16 women
left sided	14 women
Time interval between first lymphoscintigraphy and surgery	
mean	2.33 weeks
range	1-6 weeks
Time interval between surgery and second lymphoscintigraphy	
mean	3.67 weeks
range	1-6 weeks

visualized than before surgery as compared to the non-operated side; 3- lymph nodes visualized in the same location with additional visualization of lymph nodes in different locations; 4- lymph nodes visualized on the operated side however in different locations; 5- no lymph nodes visualized on the operated side; 6- presence of lymphocoele; 7- presence of lymphocoele and visualization of lymph nodes on the operated side.

For quantitative analysis, symmetrical regions of interest (ROIs) were placed over the injection site and the axilla on each lymphoscintigram. Radioactivity in ROIs was measured 10 minutes after injection ( $ROI^0$ ) and 2 hours later ( $ROI^{2h}$ ), before and after ALND. Quantification of lymphatic transport was performed by calculation of the following parameters:

(1) Axillary ratio 2 hours post injection ( $AR^{2h}$ ): the radioactivity was measured at ROI over axilla 2 hours post injection ( $ROI_{ax}$ ) to radioactivity of symmetrical ROI

over injection site ( $ROI_{inj}$ ) for each upper extremity before and after surgery by using the formula:  $AR^{2h} = (ROI_{ax} / ROI_{inj})$ ;

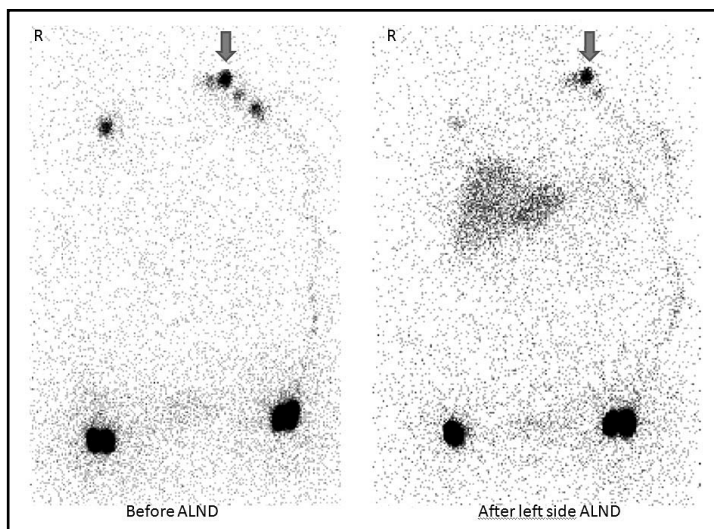
(2)  $AR^{2h}$  operated arm/ $AR^{2h}$  non-operated arm ( $AR^{2h}$  ratio) was calculated for every patient before and after ALND;

(3) Tracer disappearance rate from the injection site 2 hours post injection ( $TD^{2h}$ ): the radioactivity was measured at ROI over both sites of injection ( $ROI_{inj}$ ) for each upper extremity before and after surgery by using the formula:  $TD^{2h} = (ROI_{inj}^0 / ROI_{inj}^{2h})$ ;

(4)  $TD^{2h}$  operated arm/ $TD^{2h}$  non-operated arm ( $TD^{2h}$  ratio) was calculated for every patient before and after ALND.

#### *Photoplethysmography*

Venous photoplethysmography was carried out to assess effect of ALND on venous flow in the upper extremities. Venous photoplethysmography of upper limbs was



*Fig. 1. Lymphoscintigrams before and after a left side ALND. Lymph nodes on the operated side are in the same location with reduced visibility and the loss of distal nodes could be due to operative dissection (arrows). Interestingly, axillary lymph nodes on the right side are also less visible. Visualization of the liver indicates that some amount of the tracer entered the venous system probably at the injection site, however, opening of lymphovenous anastomoses or flow through the right side cannot be ruled out.*

performed with Rheo Dopplex II PPG (HNE Medical) in 22 women before and after surgery on the day of lymphoscintigraphy. Examination was performed in a sitting position with upper limbs allowed to hang down. The photoplethysmographic sensor was placed on the dorsal side of the wrist and the subjects then performed 10 rhythmical elbow flexions. The photoplethysmographic curve was recorded during the exercises. The venous pump index (Vp) and venous refilling time (RT) were automatically calculated using software provided by manufacturer (HNE Medical Inc.).

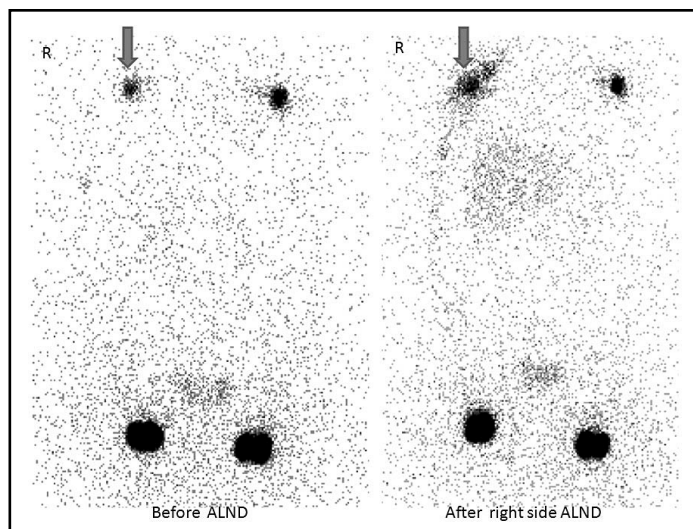
#### *Statistical Methods*

Statistical analysis was performed using Statistica for Windows 9.0. Differences between lymphoscintigraphic and photoplethysmographic parameters before and after ALND were evaluated using t-test for dependent samples. Differences were considered significant when  $p < 0.05$ .

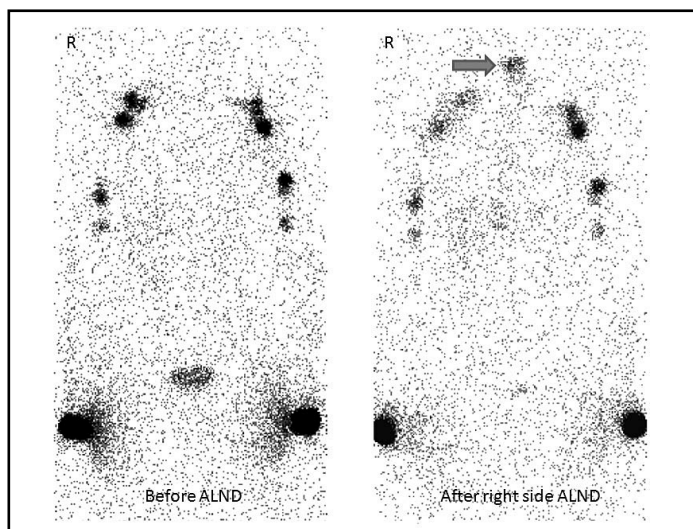
#### *RESULTS*

Qualitative visual analysis of lymphoscintigraphic patterns of lymph nodes before and after ALND in all the patients revealed the following results:

- 1) lymph nodes visualized on the operated side in the same location, however weaker than before surgery as compared to the non-operated side – 10 women (33%)
- 2) lymph nodes in the same location without change or better visualized than before surgery as compared to the non-operated side – 2 women (6.6%)
- 3) lymph nodes visualized in the same location with additional visualization of lymph nodes in different location – 9 women (30%)
- 4) lymph nodes visualized on the operated side in different location – 4 women (13.3%)
- 5) no lymph nodes visualized on the operated side – 1 woman (3.3%)
- 6) presence of lymphocoele – 3 women (10%)



*Fig. 2. Lymphoscintigrams before and after a right side ALND. Lymph nodes on the operated side after surgery are visualized at the same location with more intensity than before ALND. Liver is also visualized.*



*Fig. 3. Lymphoscintigrams before and after a right side ALND. Lymph nodes on the operated side are visualized at the same location with additional visualization of lymph nodes in different location (neck) suggesting existence of an additional lymphatic drainage pathway. Interestingly, liver can be also noticed on the postoperative lymphoscintigraphy.*

7) presence of lymphocele and visualization of lymph nodes on the operated side – 1 woman (3.3%)

*Figs. 1-4* present the examples of observed alterations in lymphoscintigrams.

Quantitative analysis revealed that the differences between lymphoscintigraphic

axillary ratio and tracer disappearance rate before and after ALND were not statistically relevant (*Table 2*). Also venous function examined by photoplethysmography was not affected by surgery-venous pump index and venous refill time did not differ before and after surgery.

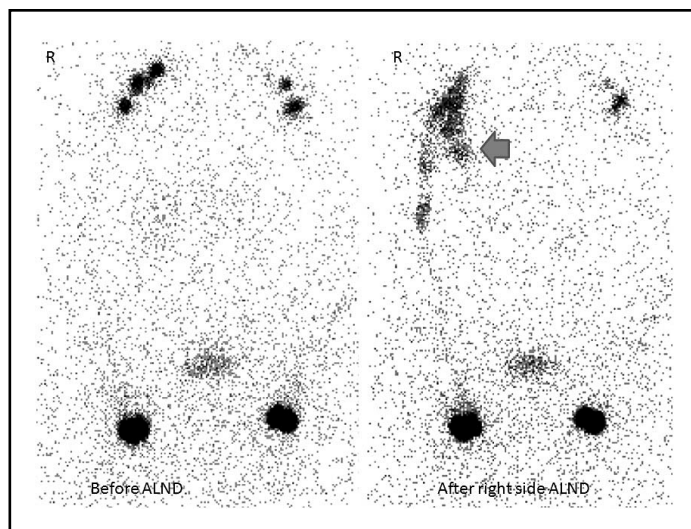


Fig. 4. Lymphoscintigrams before and after a right side ALND. After the operation, axillary lymph nodes on the operated side (right) are visualized. In addition, there is a presence of right side lymphocoele highlighted with tracer filling (arrow).

**TABLE 2**  
Quantitative Analysis of Lymphoscintigrams  
and Venous Photoplethysmography

Parameter	before ALND	after ALND	p value
AR <sup>2h</sup> ratio	1.17	0.98	0.16
TD <sup>2h</sup> ratio	0.99	1.01	0.34
VP in operated arm	39.40	35.00	0.17
VP in non-operated arm	38.00	37.00	0.80
RT in operated arm	19.80	24.00	0.23
RT in non-operated arm	22.80	24.80	0.50

Abbreviations: AR<sup>2h</sup>=axillary ratio 2 hours post injection; AR<sup>2h</sup> ratio=AR<sup>2h</sup> operated arm/AR<sup>2h</sup> non-operated arm; TD<sup>2h</sup>=tracer disappearance rate 2 hours post injection; TD<sup>2h</sup> ratio=TD<sup>2h</sup> operated arm/TD<sup>2h</sup> non-operated arm; VP=venous pump index; RT=venous refill time

## DISCUSSION

We have attempted to compare upper extremity lymphoscintigrams and the axillary lymph node status before and after ALND in women undergoing breast cancer surgery. We have previously shown that the presence of functional axillary lymph nodes after

ALND was associated with the lack of or with mild lymphedema, whereas in severe cases of upper extremity lymphedema no axillary lymph nodes were seen (13). The similar results were reported in other studies (9,15,16). However, the origin of lymph nodes visualized after ALND was not completely clear.

Our current observations revealed that axillary lymph nodes after ALND were visualized in majority of women (87%) enrolled to this study. Lymphocele was present in three of four women within the group without clearly visible axillary lymph nodes. The lymphocele could however interfere with visualization of axillary lymph nodes, and we cannot completely exclude their presence in these cases.

The presence of axillary lymph nodes after ALND has been already reported in the literature (13,15-17). Bourgeois performed postoperative axillary lymphoscintigraphy in 313 women who had undergone a radical mastectomy with ALND for breast cancer. He observed a presence of axillary nodes in 64.2% of women in his series and he attributed this finding to incomplete surgical dissection (15).

In our study, the axillary disappearance ratio (AR<sup>2h</sup>) before and after ALND, as well as the tracer disappearance (TD<sup>2h</sup>) rate before and after ALND did not significantly differ, which is in agreement with our qualitative analysis and with previous reports (18,19). These findings support the idea that lymphatic drainage from the arm to the axillary lymph nodes is initially not significantly impaired after the ALND in spite of the level I-III lymph node removal.

ALNs that remain after ALND may be considered as lymph nodes within the operated area omitted during the surgery or lymph nodes beyond operative area serving as a drainage pathway of the upper extremity. Although regeneration of regional lymph nodes might be an interesting assumption (20), taking into account short time between operation and the second lymphoscintigraphy, the possibility of regeneration of axillary lymph nodes in women examined in our study is rather impossible.

The most prevailing recognition of remaining axillary lymph nodes after ALND is that they had been missed during operation (13,15,21). Such factors as oncologic and general training of the surgeon, type of insti-

tution at which the operation was performed (tertiary referral center versus other hospitals), or even bias toward performing a more aggressive surgical approach in patients with locally advanced cancer certainly can impact the number of axillary lymph nodes retrieved during ALND (21).

However, in this study, the operations were performed by the experienced team of oncologic surgeons, with long term outcomes similar to other oncology referral centers in Europe. All breast operations were accompanied by complete and careful level I, II, and III axillary lymph node dissection with minimal chance to miss lymph nodes within predefined for level III dissection axillary operative area. We believe that functional axillary lymph nodes remaining after axillary lymph node dissection represent not unusual finding and result from specific axillary lymphatic anatomy rather than incomplete dissection due to technical issues.

Therefore, we propose the hypothesis that the presence of axillary lymph nodes after ALND is a result of a standard operative ALND procedure that defines the limits of axillary penetration and does not enable the dissection of all the axillary lymph nodes in the majority of women.

Axillary lymph nodes have been divided by anatomists into five groups as follows: anterior (drains lymph from the anterior chest wall, including the ipsilateral breast), posterior (drains posterior chest wall), lateral (drains upper extremity), central (gets lymph from anterior and lateral group) and apical (= subclavian, gets lymph from central group and drains into the thoracic duct on the left or directly into the brachiocephalic vein on the right) (22-24). Lymphatic vessels of the upper extremity, both superficial and deep, mainly drain through the axillary lateral group which consists of 4-6 lymph nodes (22-24). Besides, there are some minor lymph drainage pathways from upper extremity, i.e., some of the superficial radial lymph vessels form a trunk that ascends with the cephalic vein to reach the deltopectoral lymph nodes

or continue with the cephalic vein and enter to the apical group of the axillary nodes (24). However, knowledge about the lymphatic system is largely dependent on the studies performed in the nineteenth century with the use of mercury injected into human cadavers (25). There are only a few newer published studies on lymphatic anatomy of the breast and upper extremity. Suami et al used hydrogen peroxide to identify lymphatic vessels and then visualized them with radio-paque and color dyes in 14 cadavers. He reported that most lymph vessels of upper extremity were seen to flow into one main (sentry) lymph node in the axillary region and that the rest of lymph vessels ran along the posterior forearm, bypassing the “sentry” node to reach other smaller nodes within axilla (25).

Unlike anatomists, surgeons identify three levels of axillary lymph nodes using the pectoralis minor muscle as a reference – level I is below, level II is posterior to, and level III is superior to the pectoralis minor muscle (26). A traditional ALND, which was undertaken in the women enrolled in this study, removes all the lymph nodes of the level I, II, and III. The number of lymph nodes retrieved during an ALND varies significantly, even from 4 to 65 (21). Removal of at least 10 axillary lymph nodes is generally considered as reliable for adequate lymph node staging (27).

We presume that traditional ALND removes anterior and central lymph nodes, whereas the remaining groups of axillary lymph nodes are, at least partially, spared in the majority of women. Three-dimensional visualization of axillary lymph nodes before and after surgery would help to document and prove this hypothesis (28).

There is growing evidence that some women have a defined, hereditary, or constitutive predisposition to BCRL development, consisting of such factors as: individual weakness or underdevelopment of lymphatics and veins (9,12,29,30), specific lymphatic and vein networks, including

presence of lymphovenous anastomoses (31,32), or higher peripheral filtration rates of the lymph (33). It may be postulated that individual anatomical arrangement of axillary lymph nodes also may be part of the hereditary predisposition to BCRL. Britton et al studied concurrently lymphatic drainage pathways of the upper extremity and of the breast using lymphoscintigraphy with two different radiotracers. He was able to determine how often sentinel lymph node (SLN) draining the breast was the same node as the SLN draining the upper limb. He has found that the majority of women (13 of 15) had different pathways of lymphatic drainage from upper extremity and the breast, and in only the other 2 patients was the sentinel lymph node the same for breast and the upper extremity (32). In the study of Clough et al in 238 patients (98.2%) the axillary SLN for breast was located medially, and in only four patients (1.8%) the SLN was located laterally in the axilla (34). Nos and co-workers have shown that the dominant node draining the arm is usually situated in the lateral part of the axilla, underneath the axillary vein (35). Patients in whom the sentinel lymph node is the same for the breast and upper extremity may be at increased risk of developing BCRL after ALND.

Axillary lymph nodes in 11 of 30 women evaluated in our research were visualized in different localizations in comparison to the preoperative lymphoscintigrams (9 women – in only different locations and 2 in different plus the same locations as before operation). This may indicate that collateral lymphatic pathways were utilized in these subjects representing a compensatory mechanism after surgical injury of axillary lymphatic system.

Suami described in detail compensatory mechanisms in a cadaver that had undergone unilateral radical mastectomy and radical axillary dissection for breast cancer 11 years earlier. He used both upper limbs harvested from cadaver to examine the changes in the lymphatic structure of upper extremity after ALND. He noted presence of some



lymph nodes within the operated axilla and the following alterations in comparison to the non-operated limb: interval lymph node enlargement, obliteration of superficial lymphatic vessels, dermal backflow, and unusual communication between the superficial and deep lymphatics. These changes seem to facilitate lymph drainage after blockage of the lymph tract and could prevent the development of lymphedema in those women (17).

The importance of the absence of axillary lymph nodes in the pathology of BCRL was demonstrated in the study of the long-term results following autologous lymph node transplantation (ALNT). ALNT is a novel microsurgical technique for lymphedema treatment. Becker presented that after ALNT, postmastectomy lymphedema disappeared in 40% of patients and it notably improved in 48%. Improvement in lymphedema even in women without lymphoscintigraphic signs of lymphatic pathways restoration is difficult to explain and requires further investigations (36).

### CONCLUSIONS

Axillary lymph nodes can be detected in majority of women who underwent surgical dissection of axillary lymph nodes due to breast cancer surgery.

Current operative technique of level I+II+III axillary dissection does not allow dissection of all lymph nodes within operated axilla.

Visualization of axillary lymph nodes in different locations in comparison to the preoperative status in almost half of the women indicates that collateral lymphatic pathways were recruited and may represent a compensatory mechanism after impairment of axillary lymphatic circulation.

### ACKNOWLEDGMENT

The study was supported by the Polish Ministry of Science and Higher Education grant no: N40406631/3041.

### REFERENCES

1. Graverson, HP, K Zedeler, JA Andersen, et al: Axillary dissection in primary surgical treatment of breast cancer: Risk of false-negative axillary status. *Ugeskr. Laeger* 154 (1992), 3392-3395.
2. Weir, L, C Speers, Y D'Yachkova, et al: Prognostic significance of the number of axillary lymph nodes removed in patients with node-negative breast cancer. *J. Clin. Oncol.* 20 (2002), 1793-1799.
3. Carter, CL, C Allen, DE Henson: Relation of tumor size, lymph node status, and survival in 24,740 breast cancer cases. *Cancer* 63 (1989), 181-187.
4. Petrek, JA, RT Senie, M Peters, et al: Lymphedema in a cohort of breast carcinoma survivors 20 years after diagnosis. *Cancer* 92 (2001), 1368-1377.
5. Szuba, A, SG Rockson: Lymphedema: anatomy, physiology and pathogenesis. *Vasc. Med.* 2 (1997), 321-326.
6. Chachaj, A, K Malyszczak, K Pyszel, et al: Physical and psychological impairments of women with upper limb lymphedema following breast cancer treatment. *Psychooncology* 19 (2010), 299-305.
7. Hormes, JM, C Bryan, LA Lytle, et al: Impact of lymphedema and arm symptoms on quality of life in breast cancer survivors. *Lymphology* 43 (2010), 1-13.
8. Mak, SS, W Yeo, YM Lee, et al: Predictors of lymphedema in patients with breast cancer undergoing axillary lymph node dissection in Hong Kong. *Nurs. Res.* 57 (2008), 416-425.
9. Rockson, SG: Precipitating factors in lymphedema: Myths and realities. *Cancer* 83 (1998), 2814-2816.
10. van der Veen, P, N De Voogdt, P Lievens, et al: Lymphedema development following breast cancer surgery with full axillary resection. *Lymphology* 37 (2004), 206-208.
11. O'Mahony, S, TB Britton, JR Ballinger, et al: Delivery of radiolabelled blood cells to lymphatic vessels by intradermal injection: A means of investigating lymphovenous communications in the upper limb. *Nucl. Med. Commun.* 31 (2010), 121-127.
12. Pain, SJ, AD Purushotham, RW Barber, et al: Variation in lymphatic function may predispose to development of breast cancer-related lymphoedema. *Eur. J. Surg. Oncol.* 30 (2004), 508-514.
13. Szuba, A, A Pyszel, D Jedrzejuk, et al: Presence of functional axillary lymph nodes and lymph drainage within arms in women with and without breast cancer-related lymphedema. *Lymphology* 40 (2007), 81-86.

14. Suami, H, WR Pan, GB Mann, et al: The lymphatic anatomy of the breast and its implications for sentinel lymph node biopsy: A human cadaver study. *Ann. Surg. Oncol*, 15 (2008), 863-871.
15. Bourgeois, P, J Fruhling, J Henry: Postoperative axillary lymphoscintigraphy in the management of breast cancer. *Int. J. Radiat. Oncol. Biol. Phys.* 9 (1983), 29-32.
16. Weissleder, H, R Weissleder: Lymphedema: Evaluation of qualitative and quantitative lymphoscintigraphy in 238 patients. *Radiology* 167 (1988), 729-735.
17. Suami, H, WR Pan, GI Taylor: Changes in the lymph structure of the upper limb after axillary dissection: radiographic and anatomical study in a human cadaver. *Plast. Reconstr. Surg.* 120 (2007), 982-991.
18. Pain, SJ, RW Barber, CK Solanki, et al: Short-term effects of axillary lymph node clearance surgery on lymphatic physiology of the arm in breast cancer. *J. Appl. Physiol.* 99 (2005), 2345-2351.
19. Pain, SJ, RW Barber, JR Ballinger, et al: Local vascular access of radioprotein injected subcutaneously in healthy subjects and patients with breast cancer-related lymphedema. *J. Nucl. Med.* 45 (2004), 789-796.
20. Olszewski, WL: De novo lymph node formation in chronic inflammation of the human leg. *Ann. NY Acad. Sci.* 979 (2002), 166-177; discussion 188-196.
21. Boughey, JC, JH Donohue, JW Jakub, et al: Number of lymph nodes identified at axillary dissection: effect of neoadjuvant chemotherapy and other factors. *Cancer* 116(2010),3322-3329.
22. Uflacker, R (Ed): *Atlas of Vascular Anatomy. An Angiographic Approach*. 2nd ed. Williams & Wilkins, Philadelphia, 2007.
23. Gray, H (Ed): *Anatomy of the Human Body*, 20th ed., rev. and re-edited by Warren H. Lewis. VIII. The Lymphatic System. 4. The Lymphatics of the Upper Extremity. 7. The Lymphatic Vessels of the Thorax. Lea & Febiger, Philadelphia, 1918, Bartleby.com, 2000.
24. Doyle JR, MJ Botte: *Surgical Anatomy of the Hand and Upper Extremity*. Lippincott Williams & Wilkins, 2003.
25. Suami, H, GI Taylor, WR Pan: The lymphatic territories of the upper limb: Anatomical study and clinical implications. *Plast. Reconstr. Surg.* 119 (2007), 1813-1822.
26. Bland, KI, MP Vezeridis, EM Copeland: *Principles of Surgery*. 7th edn. New York: McGraw-Hill, 1999.
27. Mathiesen, O, J Carl, O Bonderup, et al: Axillary sampling and the risk of erroneous staging of breast cancer. An analysis of 960 consecutive patients. *Acta Oncol.* 29 (1990), 721-725.
28. Minato, M, C Hirose, M Sasa, et al: 3-dimensional computed tomography lymphography-guided identification of sentinel lymph nodes in breast cancer patients using subcutaneous injection of nonionic contrast medium: A clinical trial. *J. Comput. Assist. Tomogr.* 28 (2004), 46-51.
29. Stanton, AW, RH Mellor, GJ Cook, et al: Impairment of lymph drainage in subfascial compartment of forearm in breast cancer-related lymphedema. *Lymphat. Res. Biol.* 1 (2003), 121-132.
30. Pain, SJ, RW Barber, JR Ballinger, et al: Tissue-to-blood transport of radiolabelled immunoglobulin injected into the web spaces of the hands of normal subjects and patients with breast cancer-related lymphoedema. *J. Vasc. Res.* 41 (2004), 183-192.
31. Peters AM, JC Fowler, TB Britton, et al: Functional variation in lymph node arrangements within the axilla. *Lymphat. Res. Biol.* 7 (2009), 139-144.
32. Britton, TB, CK Solanki, SE Pinder, et al: Lymphatic drainage pathways of the breast and the upper limb. *Nucl. Med. Commun.* 30 (2009), 427-430.
33. Stanton, AW, S Modi, TM Bennett Britton, et al: Lymphatic drainage in the muscle and subcutis of the arm after breast cancer treatment. *Breast Cancer Res. Treat.* 117 (2009) 549-557.
34. Clough, KB, R Nasr, C Nos, et al: New anatomical classification of the axilla with implications for sentinel node biopsy. *Br. J. Surg.* 97 (2010),1659-1665.
35. Nos, C, B Lesieur, KB Clough, et al: Blue dye injection in the arm in order to conserve the lymphatic drainage of the arm in breast cancer patients requiring an axillary dissection. *Ann. Surg. Oncol.* 14 (2007), 2490-2496.
36. Becker, C, J Assouad, M Riquet, et al. Postmastectomy lymphedema: Long-term results following microsurgical lymph node transplantation. *Ann. Surg.* 243 (2006), 313-315.

**Andrzej Szuba, MD, PhD**  
**Professor of Medicine,**  
**Wroclaw Medical University**  
**Department of Internal Medicine,**  
**Borowska 213 street**  
**50- 556 Wroclaw, Poland**  
**Phone: +48 71 736 4000**  
**Mobile: +48 504 085 101**  
**Fax: +48 71 736 4009**  
**Email: szubaa@yahoo.com**